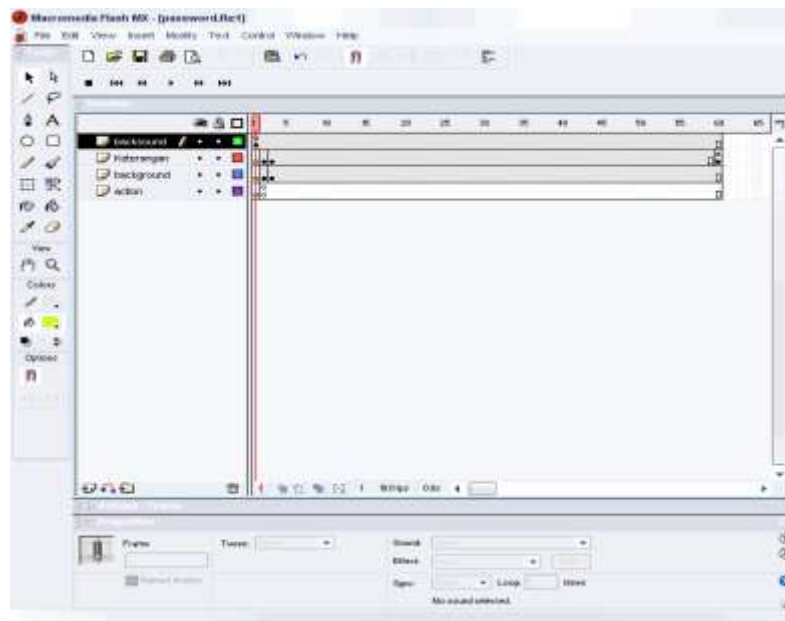


LAMPIRAN

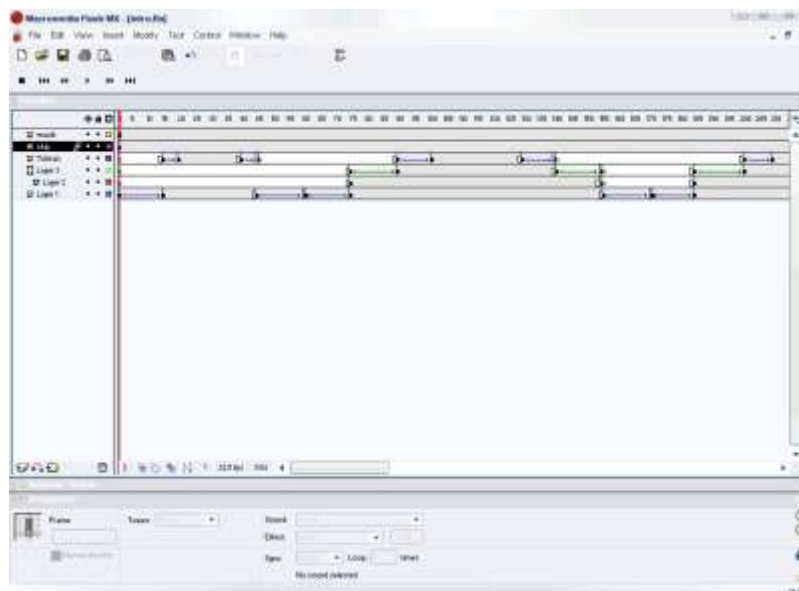
A

Timeline

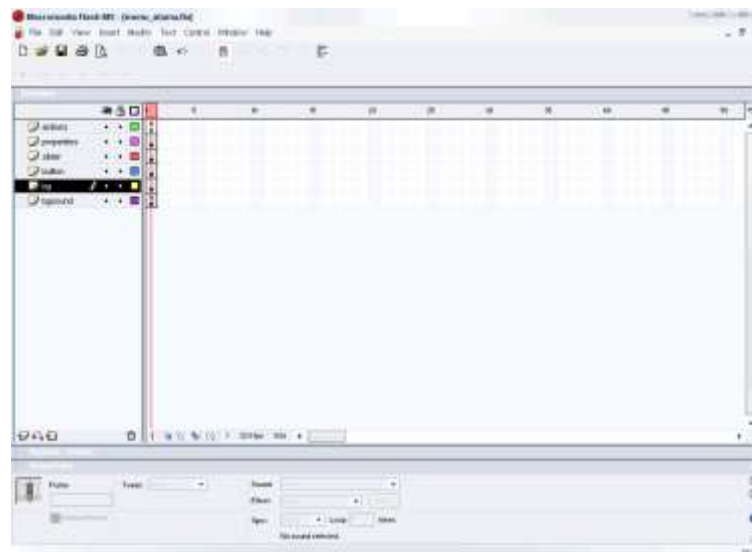
Timeline Akses



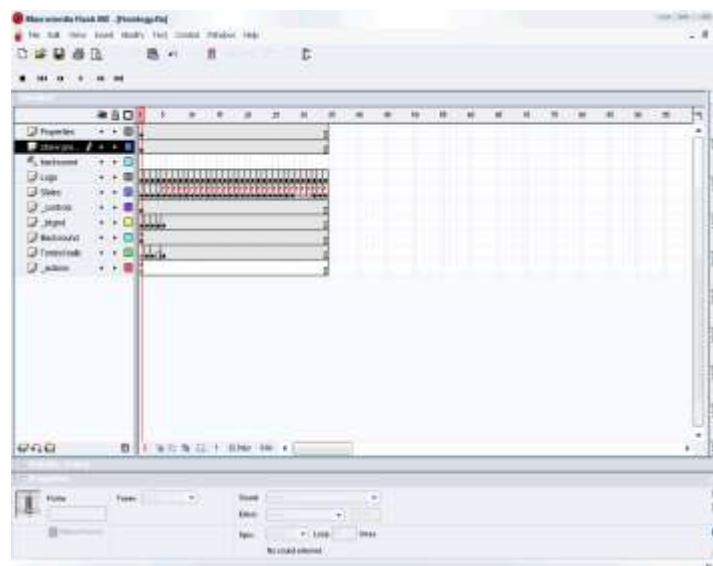Timeline Intro



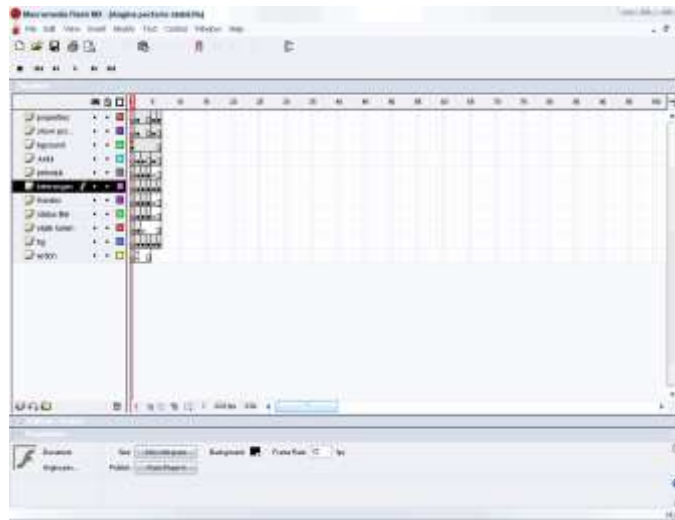Timeline Menu Utama



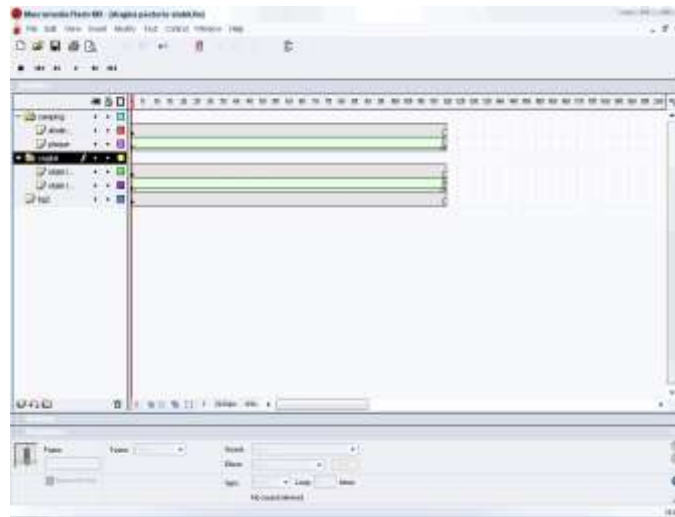
Timeline Anatomi



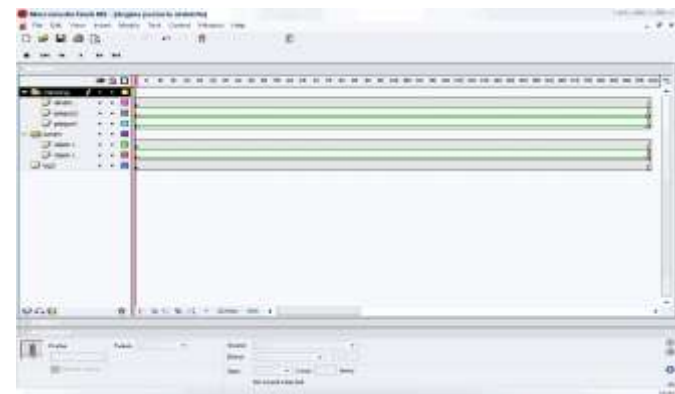
Timeline Angina Pectoris Stabil Tahap I



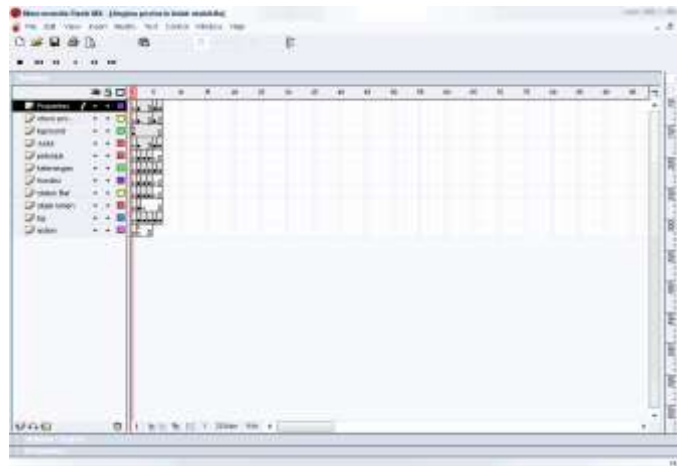Timeline Angina Pectoris Stabil Tahap II



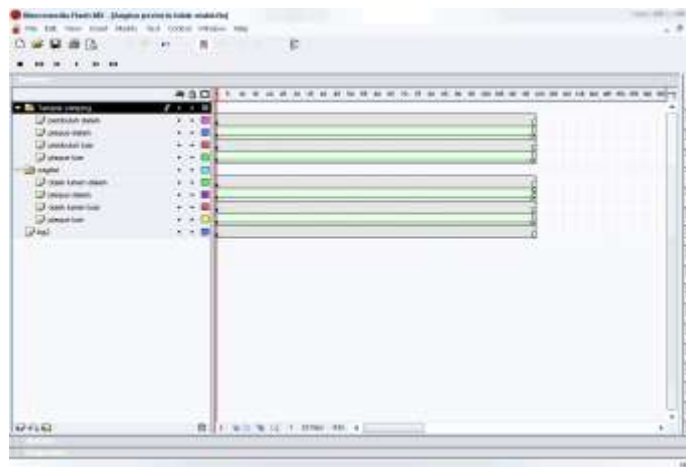
Timeline Angina Pectoris Stabil Tahap III



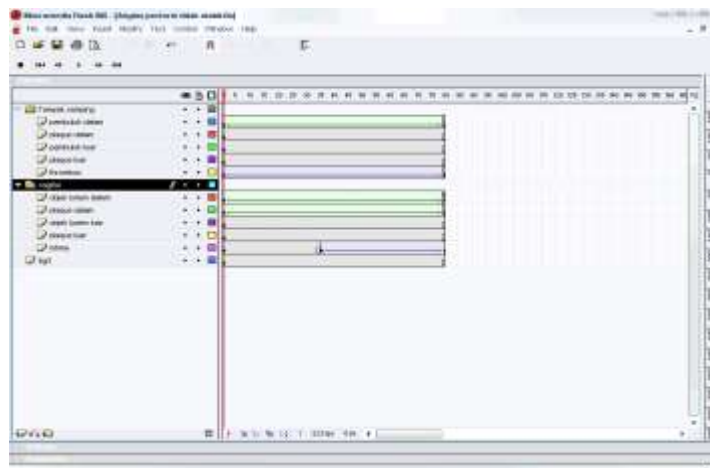
Timeline Angina Pectoris Tidak Stabil Tahap I



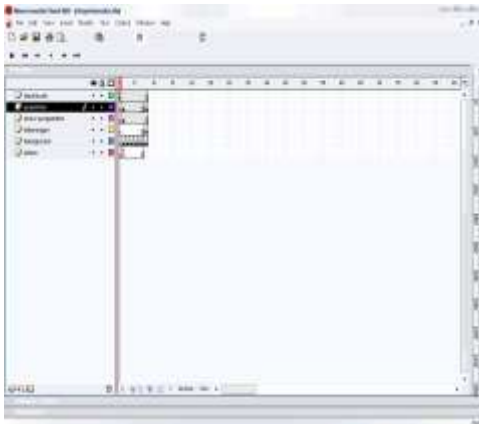
Timeline Angina Pectoris Tidak Stabil Tahap II



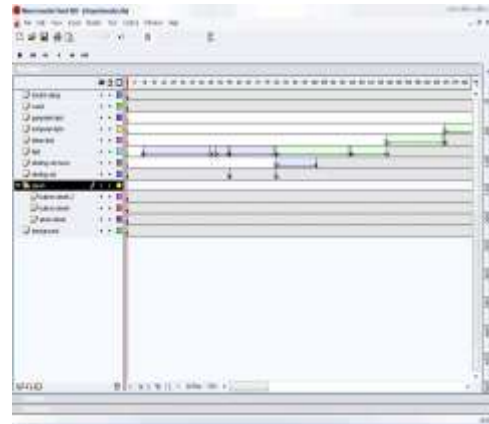
Timeline Angina Pectoris Tidak Stabil Tahap III



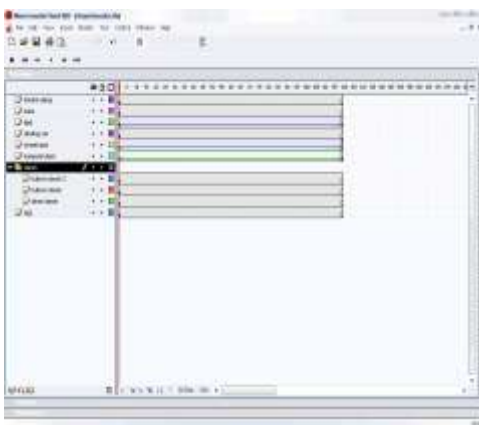
Asymtomatic



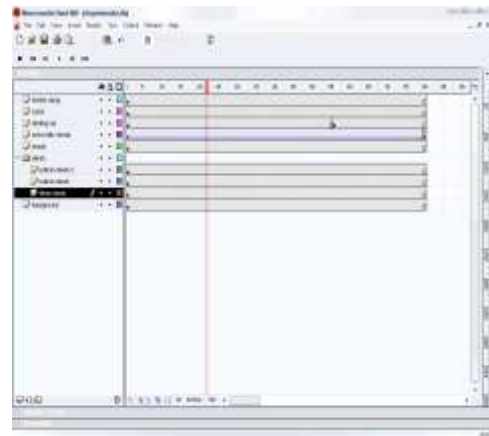
Grade I



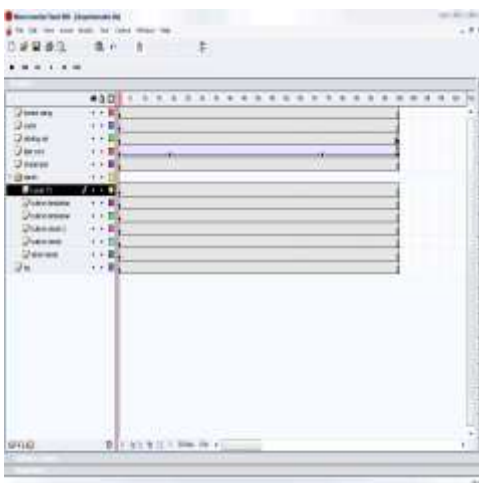
Grade II



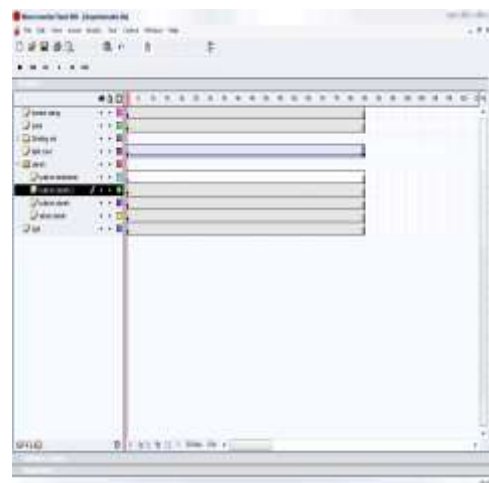
Grade III



Grade IV



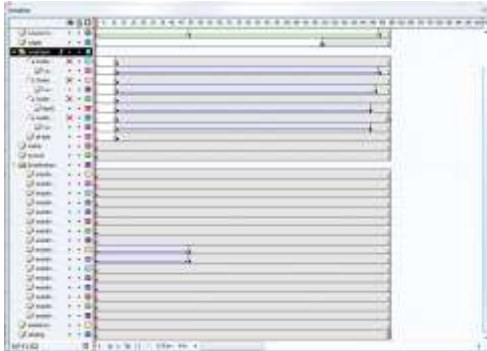
Grade V



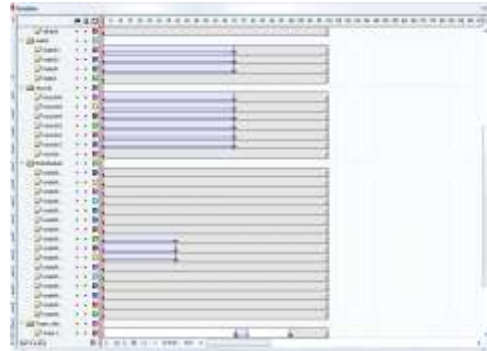
Grade VI

Akut miokard infak

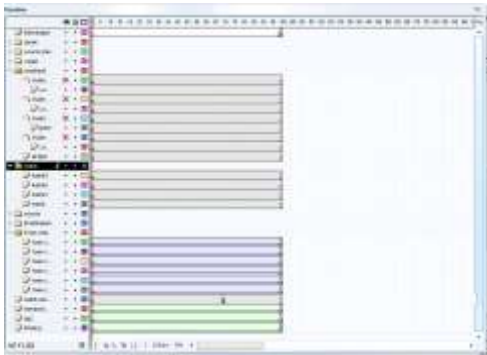
Grade I



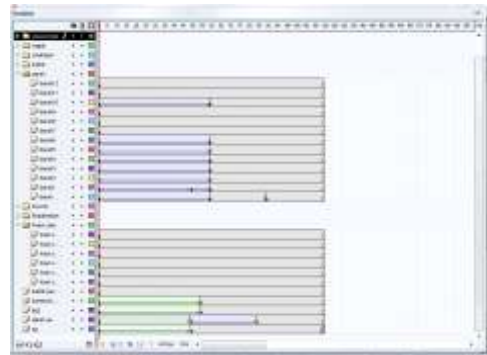
Grade II



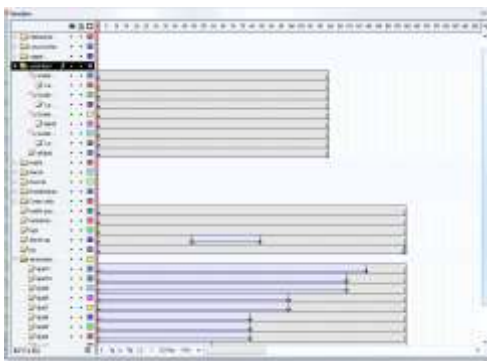Grade III



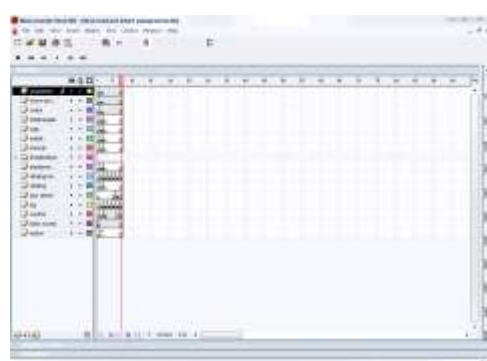
Grade IV



Grade V

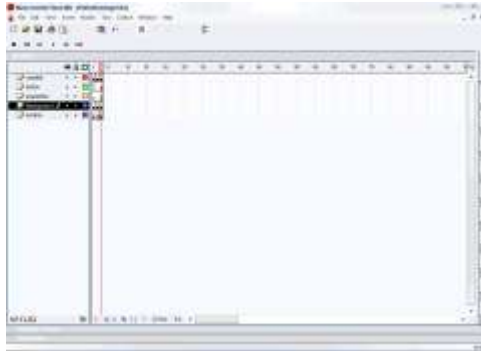


Grade VI

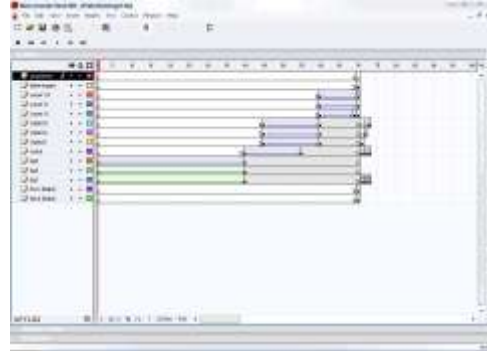


Penjelasan Umum

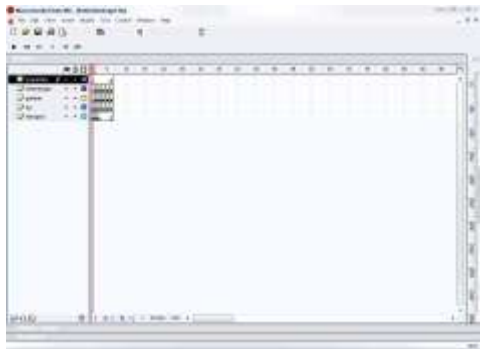
Scene I



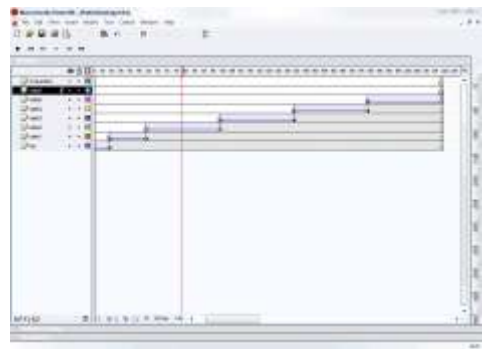
Scene II



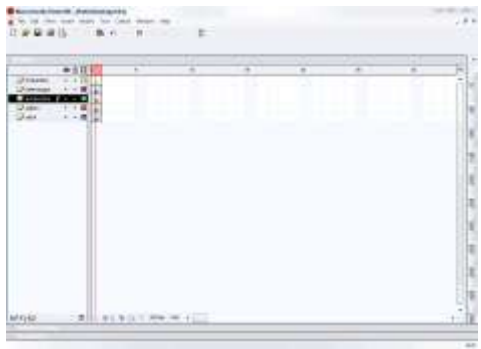Scene III



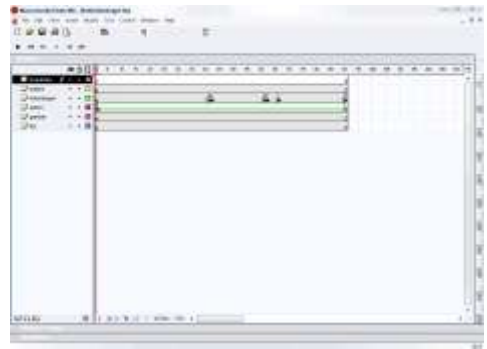
Scene IV



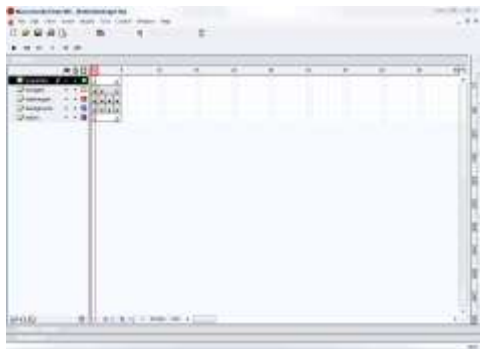Scene V



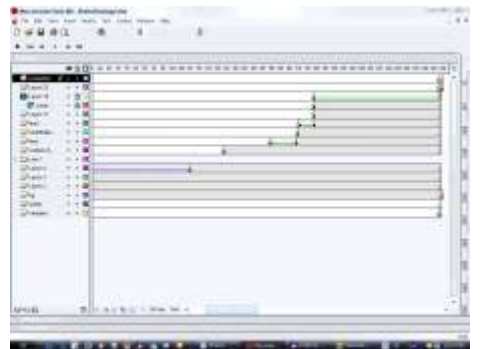Scene VI



Scene VII



Scene VIII

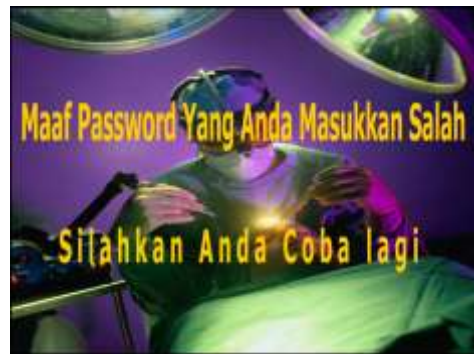
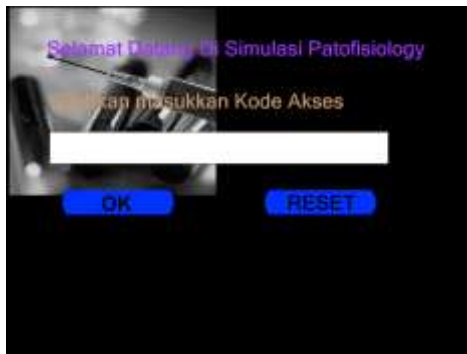
LAMPIRAN

B

Hasil Tampilan

Tampilan Kode Akses



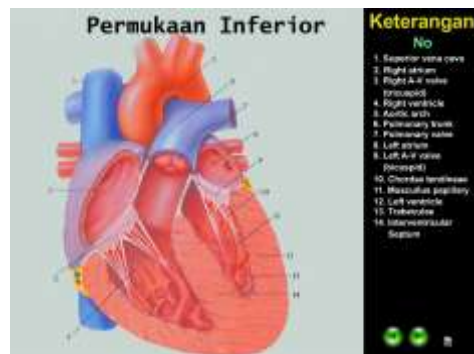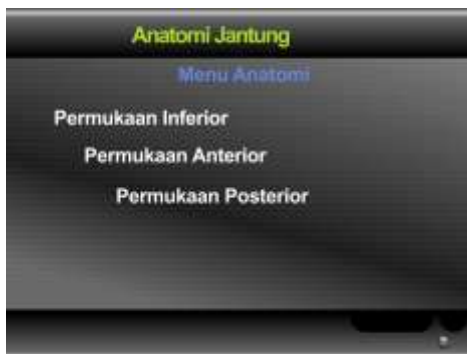Tampilan Intro

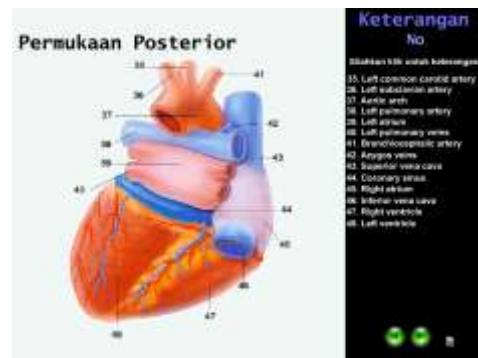
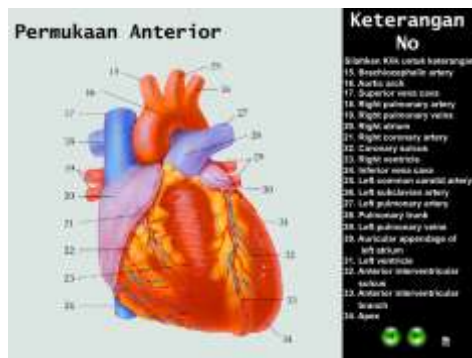


Tampilan Menu Utama



Tampilan Sub Menu Anatomi



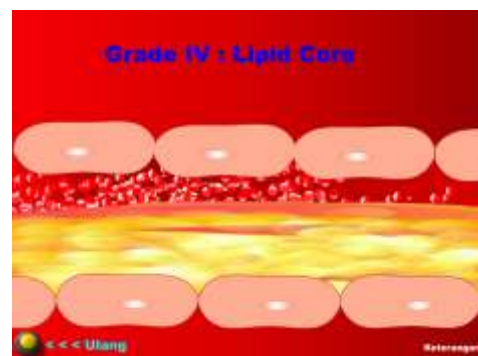
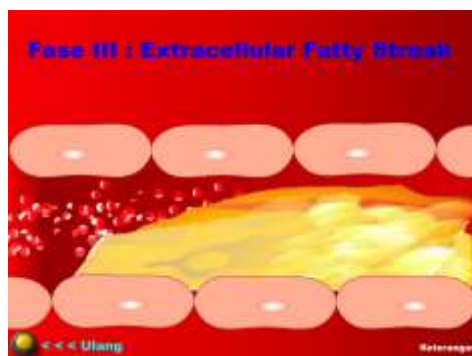
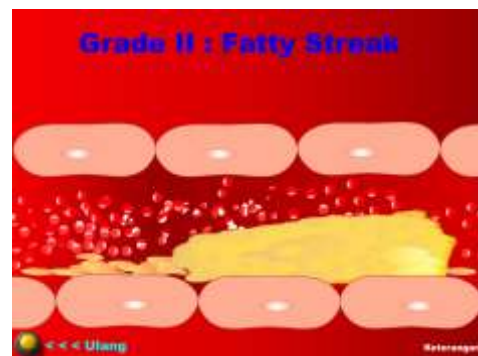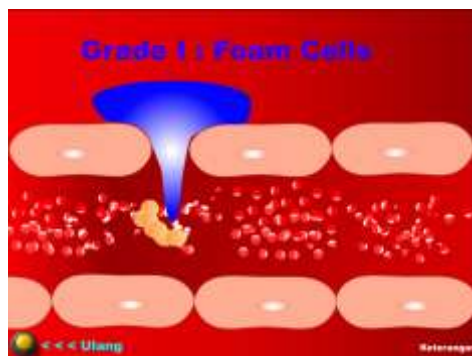


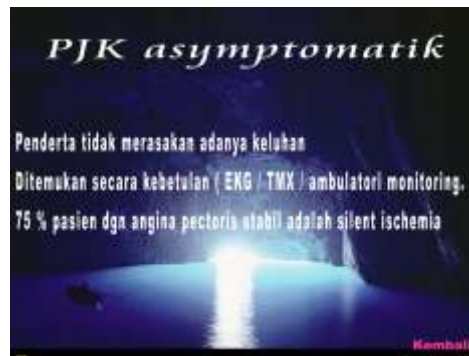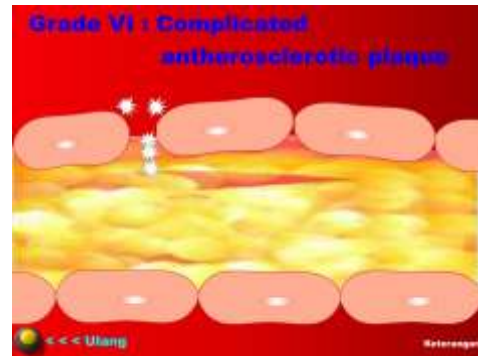
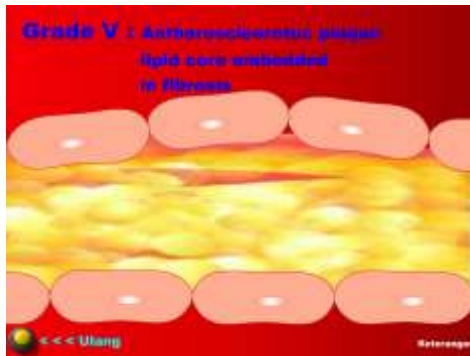
Right atrium

Atrium Kanan terdiri dari rongga utama dan auricula. Di luar, yang bagian dalam membentuk suatu rigi, crista terminalis. Bagian utama atrium yang terletak posterior terhadap rigi terdapat dinding halus dan secara embriologis berasal dari sinus venosus. Bagian Atrium yang terletak di depan rigi mengalami trabekulasi akibat berkas serabut-serabut otot, *musculi pectinati*, yang berjalan dari crista terminalis ke auricula. Bagian Anterior ini secara embriologis berasal dari atrium primitif

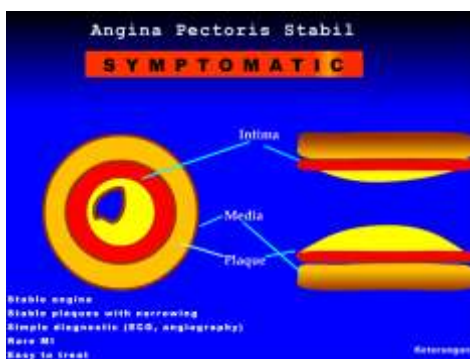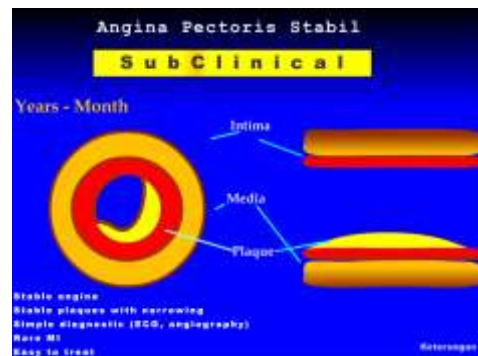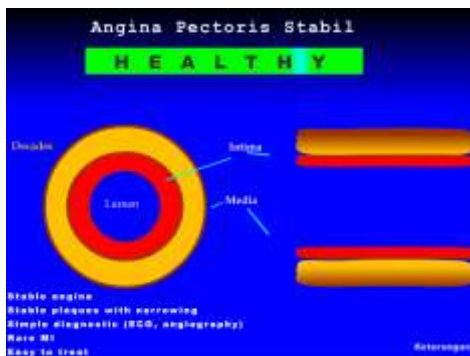Permukaan : Inferior Anterior Posterior.

Tampilan Sub Menu Asymtomatic



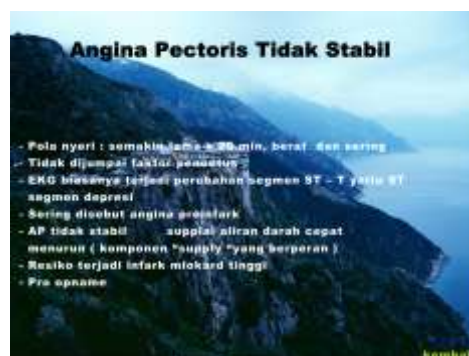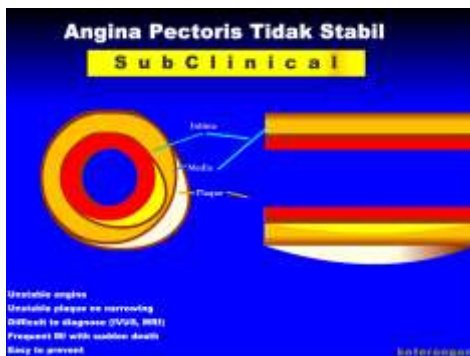
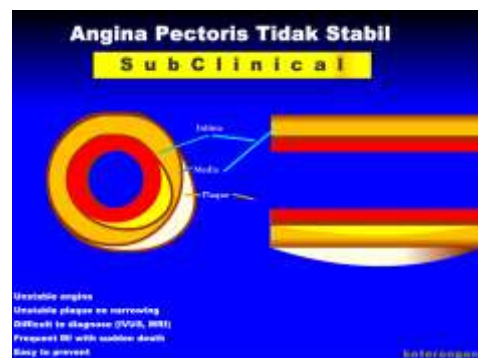

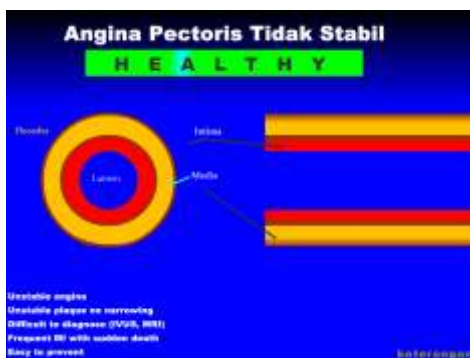
Tampilan Sub Menu Angina Pectoris Stabil

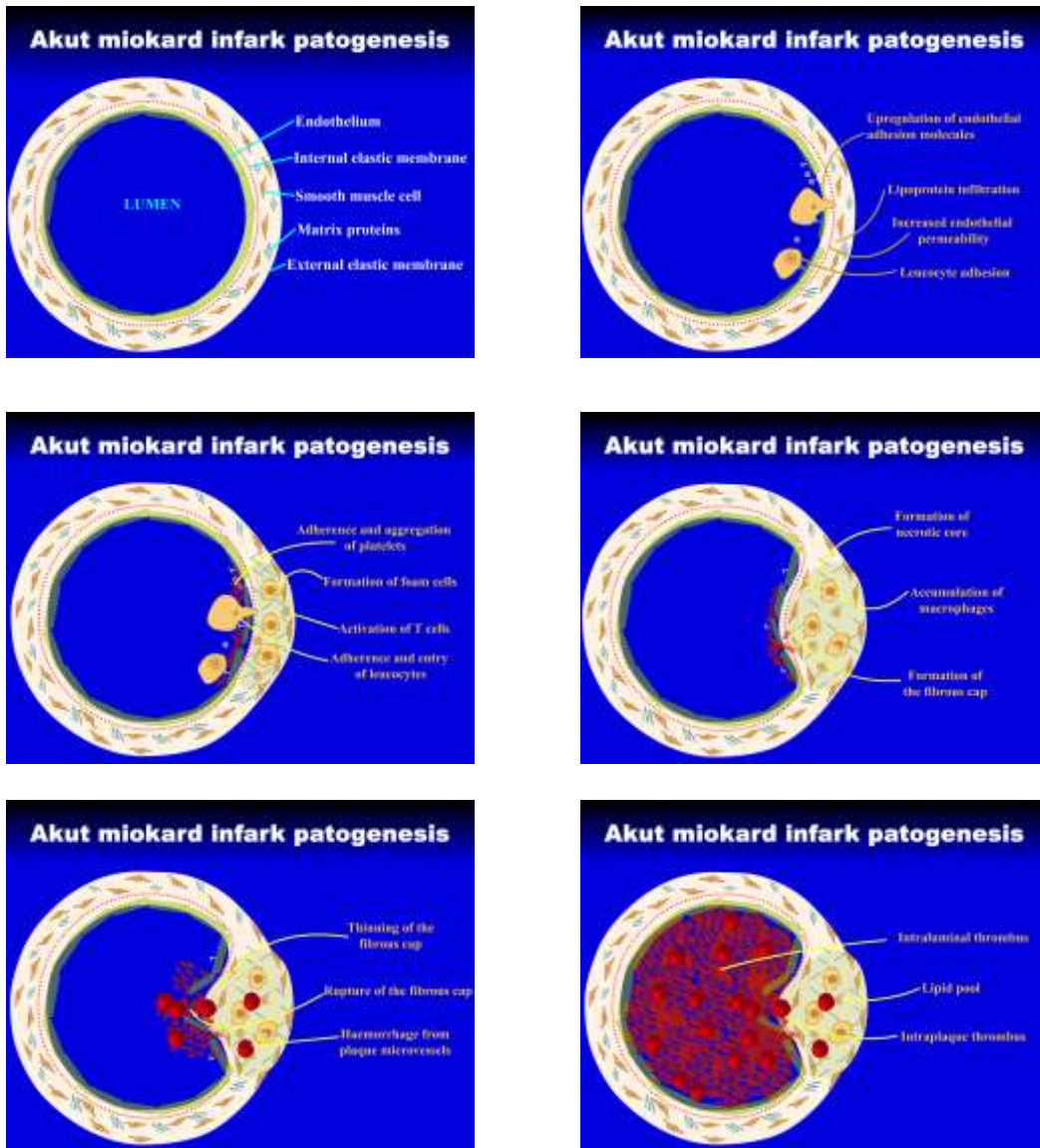


Angina Pectoris Stabil
 Canadian Cardiovascular Society grading scale
 Angina Class I : timbul saat aktifitas berat
 Angina Class II : timbul saat jalan mendaki
 Angina Class III : timbul saat pekerjaan sehari2
 Angina Class IV : timbul angina saat istirahat

Tampilan Sub Menu Angina Pectoris Tidak Stabil



Tampilan Sub Menu Akut Miokard Infark Patogenesis



Tampilan Sub Menu Keterangan Umum

Clinical Manifestations of Atherosclerosis

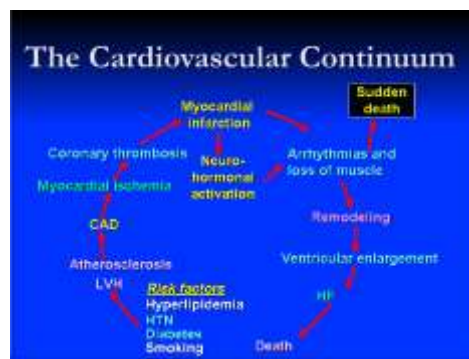

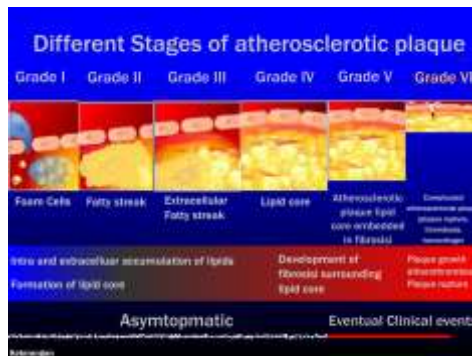
S
i
k
e
n
i
k

- Coronary heart disease**
Angina pectoris, myocardial infarction, sudden cardiac death
- Cerebrovascular disease**
Transient ischaemic attacks, stroke
- Peripheral vascular disease**
Intermittent claudication, gangrene

DINDING ARTERI NORMAL

Cholhan (2012) Jelaskan di Gambar di bawah ini!

- TUNICA ADVENTITIA
- TUNICA MEDIA
- TUNICA INTIMA
- ENDOTHELIUM
- SUBENDOTHELIAL PASNORATIVE TISSUE
- INTERNAL ELASTIC MEMBRANE
- SMOOTH MUSCLE CELLS
- ELASTIC / COLLAGEN FIBRES
- EXTERNAL ELASTIC MEMBRANE



Tampilan Sub Menu HELP

Petunjuk Penggunaan

1. Pilihlah menu yang tersedia sesuai dengan kebutuhan anda, cukup tinggal mengklik tombol yang tersedia.
2. Apabila di dalam tampilan animasi, anda menemukan ikon yang bergambar tangan pada bagian atau tulisan tertentu. Berarti pada bagian tersebut terdapat penjelasan atau informasi lebih lanjut.
3. Untuk navigasi dalam tampilan animasi, anda dapat menggunakan tombol yang telah tersedia atau menekan arah kiri atau kanan pada keyboard. Untuk kembali ke menu utama silahkan ke menu properties.
4. Menu properties terlihat pada setiap anda pindahkan kursor mouse ke kiri atas maka akan terlihat.
5. Untuk mengatur volume audio anda cukup menekan bagian properties.

Tampilan Sub Menu Keluar

FAKULTAS TEKNIK ELEKTRO
UNIVERSITAS KRISTEN MARANTHA

FAKULTAS KEDOKTERAN
UNIVERSITAS KRISTEN MARANTHA