

3. Protein Hydrolysate of Green Peas Bromelain Attenuates Kidney Fibrosis in Cisplatin-Induced Nephrotoxicity Rats

by Meilinah Hidayat, Retno Pangastuti, Sijani Prahastuti, Khomaini Hasan

Submission date: 26-Jul-2023 10:13AM (UTC+0700)

Submission ID: 2136914072

File name: 3._JURNAL_HAYATI_2023.pdf (863.26K)

Word count: 6415

Character count: 35170

Protein Hydrolysate of Green Peas Bromelain Attenuates Kidney Fibrosis in Cisplatin-Induced Nephrotoxicity Rats: Emphasis on Anti-Inflammatory Activities

Meilinah Hidayat^{1*}, Retno Pangastuti², Sijani Prahastuti³, Khomaini Hasan⁴

¹Nutrition Department Faculty of Medicine, Universitas Kristen Maranatha, Bandung, Indonesia

²Student of Faculty of Medicine, Universitas Kristen Maranatha, Bandung, Indonesia

³Biochemistry Department Faculty of Medicine, Universitas Kristen Maranatha, Bandung, Indonesia

⁴Biochemistry Department, Faculty of Medicine, Universitas Jendral Ahmad Yani, Cimahi, Indonesia

ARTICLE INFO

Article history:

Received September 19, 2021

Received in revised form October 23, 2022

Accepted November 9, 2022

KEYWORDS:

Beta-2-microglobulin,
green pea,
hs-CRP,
immunohistochemistry,
TGF- β

ABSTRACT

Massive tubule fibrosis is a histopathology hallmark of chronic renal failure (CRF). The previous study of protein hydrolysate of green pea (*Pisum sativum*) bromelain (PHGPB) showed promising results as an antifibrosis in glucose-induced renal mesangial culture cells, by decreasing their TGF- β levels. In this experiment the anti-inflammatory, anti-fibrotic effect of PHGPB in Cisplatin-induced chronic renal failure (CRF) rats was measured. The purpose of this study is to evaluate the anti-inflammatory and antifibrosis effect of PHGPB in Cisplatin-induced chronic renal failure rats. Five groups consisted of five rats: negative control, Cisplatin control, and three groups of Cisplatin+PHGPB (dose of 100, 200, and 400 mg/kg BW/day) treated for 56 days. The examined parameters are Beta-2-microglobulin (β 2MG), hs-CRP, histopathological observations of Masson's trichrome stain, and IHC. The level of β 2MG and hs-CRP in the Cisplatin+PHGPB group lowered and was highly different from Cisplatin control ($p < 0.05$) depending on doses. In histopathology, the Cisplatin+PHGPB 400 mg/kg BW group showed less fibrosis and no significant difference with the negative control in Masson trichrome staining. While in IHC histopathology, PHGPB treatment slightly ameliorated TGF- β expression and intensity of TGF- β values convincingly. In conclusion, PHGPB can relieve kidney fibrosis in cisplatin-induced nephrotoxicity rats: Emphasis on anti-inflammatory activities.

1. Introduction

Chronic renal failure occurs due to diseases or disorders that damage the kidneys since kidneys experience a decreased ability in their excretion function (Medical Dictionary 2021). Developing tubule fibrosis is a histopathology hallmark of chronic renal failure (CRF). Tubulointerstitial fibrosis (TIF) is the best predictor of kidney failure prognosis and a stamp of authenticity of chronic kidney disease. The development of TIF involves several types of cells such as renal tubular epithelial cells, renal muscle cells, myofibroblasts, endothelium, and inflammatory cells (Gewin 2018).

Ongoing inflammation is associated with elevated beta-2-microglobulin (β 2MG) levels (Tibúrcio *et al.*

2018). Beta-2-microglobulin which forms the light chain of the major histocompatibility complex (MHC) class I molecule (HLA, A, B, C) normally present on the surface of every nucleated cell in the human body (Li *et al.* 2016; Tibúrcio *et al.* 2018) is a low molecular weight protein (11.8 kDa approximately to 12 kDa) that will be filtered by the renal glomerulus. β 2MG is constantly released into the blood in small quantities. The β 2MG is rapidly filtered through the kidney since it has low molecular weight. Hence, in a healthy kidney, more than 99.9% of β 2MG is absorbed and metabolized in the renal proximal tubule. Kidney injury leads to damage in the nephron segment, i.e acute tubulointerstitial nephropathy, there is an increase in the number of B2M excreted into the urine. Renal is the primary clearance mechanism of β 2MG, therefore reduction of glomerular filtration

* Corresponding Author

E-mail Address: mellahidayat@yahoo.com

rate (GFR) will increase β 2MG serum (Burtism *et al.* 2015; Yue *et al.* 2020).

This underutilized metabolite like β 2MG can be useful in assessing renal function, especially in patients with chronic kidney disease undergoing transplantation or in patients with suspected renal tubulointerstitial fibrosis. In addition, β 2MG can be useful as a nonspecific marker of various inflammatory conditions and is relatively sensitive (Li *et al.* 2016). Thus, β 2MG can be a predictor of the prognosis of patients undergoing hemodialysis because it is a marker of intermediate molecular filtration and is also a sensitive but not specific parameter for cases of infection, cancer, and inflammation (Topçiu-Shufta *et al.* 2016).

Another specific but non-specific marker of inflammation is high-sensitivity C-reactive protein (hs-CRP). hs-CRP protein is elevated in the acute phase in response to inflammation (eg, arthritis, trauma, infection, and surgery) (Luan and Yao 2018). HsCRP levels can be elevated in any medical condition that can lead to infection, inflammation, or primary/secondary tissue injury (Landry *et al.* 2017; Luan and Yao 2018). Two studies demonstrated a role for elevated CRP levels in end-stage renal failure (eGFR <15) and chronic kidney disease patients undergoing dialysis (Bouteldja *et al.* 2013; Gusev *et al.* 2021). However, the role of CRP in the development of kidney damage and TIF is not completely clear.

These TIF conditions should be prevented, and many therapeutic drug candidates have been studied. Some natural substances showed promising results to control TIF through the TGF- β suppression pathway, like natural polyphenolic flavanone (Wan *et al.* 2022) and other natural plants, like resveratrol (3,5,4'-trihydroxy-trans-stilbene), betanin, tannic acid, curcumin (C21H20O6), genistein, paeoniflorin, gambogic acid and *Cinnamomum cassia* (Avila-Carrasco *et al.* 2019). Green peas (*Pisum sativum*) which are hydrolyzed by bromelain (PHGPB) showed promising potential as an anti-nephrotoxicity therapy. Proteins in PHGPB were separated using sodium dodecyl-sulphate-polyacrylamide gel electrophoresis (SDS-PAGE) (Spectra Multicolor Low Range Protein Ladder paints. No 26628) patterns showed many bands 14.4 kDa with much molecular weight smaller than ten kDa (Hidayat *et al.* 2019). PHGPB reduced the levels of TGF- β 1 and Fibronectin in glucose-induced mesangial cell lines (Hidayat *et al.* 2021). Provision PHGPB dose of 100 mg/kg BW/d for

28 days tends to improve the parameters of kidney function (Urea, Creatinine, Uric acid) and renal histopathology in Cisplatin-induced rats (Hidayat *et al.* 2019). However, in that 28-day study, induction of a single dose of Cisplatin 10 mg/kg BW (Nematbakhsh *et al.* 2013) has not caused the kidney histopathology signs of fibrosis. PHGPB treatment improved the appearance of cloudy swollen tubular degeneration, nuclear necrosis, and hyaline casts (Hidayat *et al.* 2019). It may take a longer time or a different regimen of Cisplatin to induce a histopathologic TIF condition.

Cisplatin, an anticancer drug with nephrotoxic effects, has been shown to induce fibrosis in renal interstitial rats. The prime lesion begins with extensive tubular impairment to the proximal tubule at the corticomedullary junction in the lower straight section (segment P3). Cisplatin-induced kidney lesions are proving to be a useful model for interstitial-fibrosis post-tubular injury (Mc Sweeney *et al.* 2021). The gold standard for assessing interstitial fibrosis is biopsy with histological techniques (Berchtod *et al.* 2017). However, the use of renal histopathological analysis to predict renal failure has not been established and is impractical (Gewin 2018). There is a postulate that excessive accumulation of β 2MG can trigger the dialysis-related amyloidosis (DRA) and lead to fibrosis in the kidney (Portales-Castillo *et al.* 2020). Our prior study showed that PHGPB reduced the levels of parameters of fibrosis in glucose-induced mesangial cell lines (Hidayat *et al.* 2021). Hence in this current study, the mechanisms of PHGPB as an antifibrosis will be examined by measuring levels of β 2MG and hs-CRP as inflammatory markers, kidney histopathology Masson trichrome staining, immunohistochemical (IHC) preparations with antibodies TGF- β in Cisplatin-induced rat kidneys.

1 This study aims to know the PHGPB effect on kidney fibrosis in cisplatin-induced nephrotoxicity rats: Emphasis on anti-inflammatory activities.

2. Materials and Methods

2.1. Preparation Protein Hydrolysate

A total of 500 g of dried green peas (*Pisum sativum*) 200116. The USA. Trinidad Benham Corp. Denver, Co 80237 was prepared for hydrolysis using the previously described simple hydrolysis method (Hidayat *et al.* 2019). The dry seeds were ground into powder, after sifting through a sieve 120-mesh,

poured in 2,000 ml of water. The bromelain protease enzyme from *Ananas sativus* pineapple was added to 10%, then a simple hydrolysis process was carried out according to the patent P 00201907647, (Universitas Kristen Maranatha 2021). The protein of PHGPB were separated using Low-Molecular-Weight-Protein-Ladders SDS-PAGE (mybiosource.com/355494) with a gel concentration of 15%, voltage 90V, and time 120 minutes (Laemmli 1970).

2.2. Experimental Animals

Twenty-five male Sprague Dawley (SD) rats, 6-8 weeks old, 160-182 g, were used for this test. The laboratory rats were purchased from Veterinary Laboratory Services, iRATco. Before the experiment started, all rats were acclimatized for seven days in a laboratory atmosphere, ventilated cage, the room temperature was maintained at 22-24°C, standard pellet diet and tap water ad libitum with a light/dark room cycle of approximately 12 hours. All rats were weighed once a week. This research has been approved by the Maranatha Animal Ethics Committee, Decree No. 497/II/S.Kep/2021. The rats were divided into five groups randomly: the control positive and negative control groups and three stratified dose treatment groups (low, medium, and high) ($n = 5$ males). After acclimatization, the entire rats have induced with a Cisplatin intra-peritoneally dose of 2 mg/kg BW/week for four weeks, except for the negative control group (Perse and Veceric-Haler 2018). The PHGPB was given orally every day for the following 28 days with a single dose of 100, 200, and 400 mg/kg BW/d, while the negative control group received only distilled water without Cisplatin-induced and the control positive were only received Cisplatin-induced. The rats were weighed once in two days.

2.3. Measurement of Beta-2-microglobulin, hs-CRP, and Creatinine Level

After 28 days of treatments, all animals were killed, initially with sedated using Xylazine 10 mg/Kg BW and Ketamine 100 mg/kg BW. Through a heart puncture blood samples were collected and put into tubes and centrifuge to obtain serum for measurement of Beta-2-microglobulin, hs-CRP, and Creatinine level.

2.4. MAQ Analysis

Kit of 0108047430190c501spV2.0 β 2MG Tina quant β 2 Microglobulin System ID 07 6864 2

No Ref 08047430 190 and were analysed using Cobas Roche c 311. Measurements of β 2MG were conducted using the assay of immunoturbidimetric. After agglutination the latex bound β 2MG antibody with the antigen from the sample forms an antigen/antibody complex. The results of the examination were determined turbidimetrically (Li *et al.* 2016). R1 (124 μ l): TRIS/HCl buffer: 23 g/L, NaCl: 19 g/L; EDTA: 1.3 g/L; preservative and pH 8.2; R2 (124 μ l): Latex particles coated with polyclonal β 2MG antibody (rabbit): 1.9 g/L; position B is for preservative R1 and position C is for R2. The analysis of β 2MG was carried out at Purwakarta Laboratory.

2.5. Hs-CRP, and Creatinine

The analysis of hs-CRP and creatinine was carried out using the kit and Cobas Roche c 311 at Purwakarta Laboratory.

2.6. Kidney Preparation for Histopathology Study

At the end of the treatment, the kidneys were sampled and weighed to calculate the relative weight with the following formula: Relative Kidney Weight (RKW) = (Kidney Weight (gr)) / (Bodyweight (gr)) \times 100%. Furthermore, the kidneys were fixed for 48 hours in a 10% Neutral buffered formalin solution and continued using the paraffin embedding method. The paraffin-embedded tissue was then micro-cut with a microtome with a thickness of 5 m and was ready for tissue staining on slides.

2.7. Masson Trichrome Stain Kidney Histopathology

Following standard procedures for tissue preparations, Masson trichrome staining begins with deparaffination, the slide is heated at a temperature of 56°C for 15 minutes and then immersed in Xylene for 5 minutes 3 times. Furthermore, rehydration was carried out with graded ethanol, namely absolute ethanol, continue with ethanol of 96%, 80%, and 70% each for 5 minutes, and continued to be immersed in running water for 5 minutes. The slides were fixed with Bouin's solution for 5 minutes and washed with running water for 5 minutes. Bouin's is very compatible with the trichrome stain due to its mordanting effect on the tissue (Microscopy Alliance 2022). Then the slides were immersed for 5 minutes in Wigert's iron hematoxylin solution and followed by washing in running water for 2 minutes. Then the

slides were immersed in a solution of acid fuchsin for 5 minutes and then washed 2 minutes with running water. Differentiation was carried out by immersing the slides in a phosphomolybdic-phosphotungstic acid solution for 5 minutes and then rinsing with running water for 2 minutes and 5 minutes transferring the slides to aniline blue solution and washing 5 minutes with running water. Next, the slides were rinsed in running water and dried in graded alcohol, cleared with xylene 3 times, and covered with a cover glass using a permount solution of entellan (gom).

By two independent and experienced histopathologist, the images were interpreted under a light microscope. The renal fibrosis in Masson trichrome stained section was calculated from the blue color area over the whole field area based on five randomly selected fields in the cortex at the location of outer stripe of the medulla. The analysis was carried out by calculating the proportion of fibrosis marked in blue to normal tissue.

Images of five random locations per mouse were analysed and quantitatively calculated from optical density (OP) using ImageJ (NIH) software (<https://imagej.nih.gov/ij/docs/pdfs/ImageJ.pdf>) (Algandaby 2021). After that, the average of the five sites per rats was calculated.

2.8. TGF-Beta Immunohistochemical (IHC) Staining

IHC staining begins with deparaffination, namely the slide is heated at a temperature of 56°C for 15 minutes and then immersed in Xylene for 5 minutes for 3 times. Furthermore, rehydration was carried out with graded ethanol, initially with absolute ethanol, then ethanol of 96%, 80%, and 70% each for five minutes, continued to be immersed in running water for 5 minutes. Furthermore, for 10 minutes, antigen was taken with citrate buffer pH 6.0 at 121°C in an autoclave. Next, the slides were allowed to cool down to 27-30°C and rinsed with PBS by immersing them for 5 minutes 3 times in an orbital shaker. The slides were then blocked by endogenous peroxidase with 3% H₂O₂ in methanol for 15 minutes and rinsed with PBS using the same method. Protein blocking was performed at room temperature for 30 minutes with normal Goat IgG 500 ug/ml and followed by incubation of the primary antibody, recombinant anti-TGF-β1 antibody (Abcam, cat. no. ab215715) with a concentration of 4 ug/ml for overnight at 4°C. the next day was rinsed with PBS and followed by

administration of secondary antibody Goat anti-rabbit IgG H and L-HRP conjugate (Abcam, cat no. 6721) with a concentration of 4 ug/ml for 30 minutes at room temperature. Then visualized with DAB until a brown color appears under the microscope. The slides were counterstained with Hematoxylin Mayer for 10 dips and rinsed for 2 minutes with running water. Next, using running water the slides were rinsed and dried in graded alcohol, followed with xylene 3 times, and covered with a cover glass using a permount solution of adhesive. The results were positive if brown coloration occurred indicating TGF-β number expression, and the intensity proportion of protein TGF-β expression. Finally, ImageJ (NIH) software was used (<https://imagej.nih.gov/ij/docs/pdfs/ImageJ.pdf>) (Algandaby 2021). Thereafter the mean count from five sections per animal was calculated.

2.9. Statistical Analysis

Windows SPSS 22.0 were used to analyse the data statistically. The Kolmogorov Smirnov and Shapiro-Wilk tests were used to test the normality and the data distribution. If the data was normal distributed; using a one-way ANOVA test and post hoc LSD test to compare Creatinine, β2MG, and immunohistochemical graph. Data was statistically significant if $p < 0.05$.

3. Results

3.1. Body Weight

The observation of the bodyweight of the rats showed results of a very significant difference between the negative control and the cisplatin or positive control ($p < 0.01$). The group of Cisplatin+PHGPB 100 and 200 mg/kg BW were significantly different from the negative control group ($p < 0.05$) but non-significant with the positive group. The Cisplatin+PHGPB 400 mg/kg BW group showed a significant difference from the positive control group ($p < 0.05$) and did not differ from the negative control group. The high dose group showed the best bodyweight results, shown in Figure 1.

3.2. Relative Kidney Weight (RKW)

Figure 2 showed comparison between relative kidney weight (RKW) left and right was not significantly different except for the group of Cisplatin+PHGPB 200 mg/kg BW.

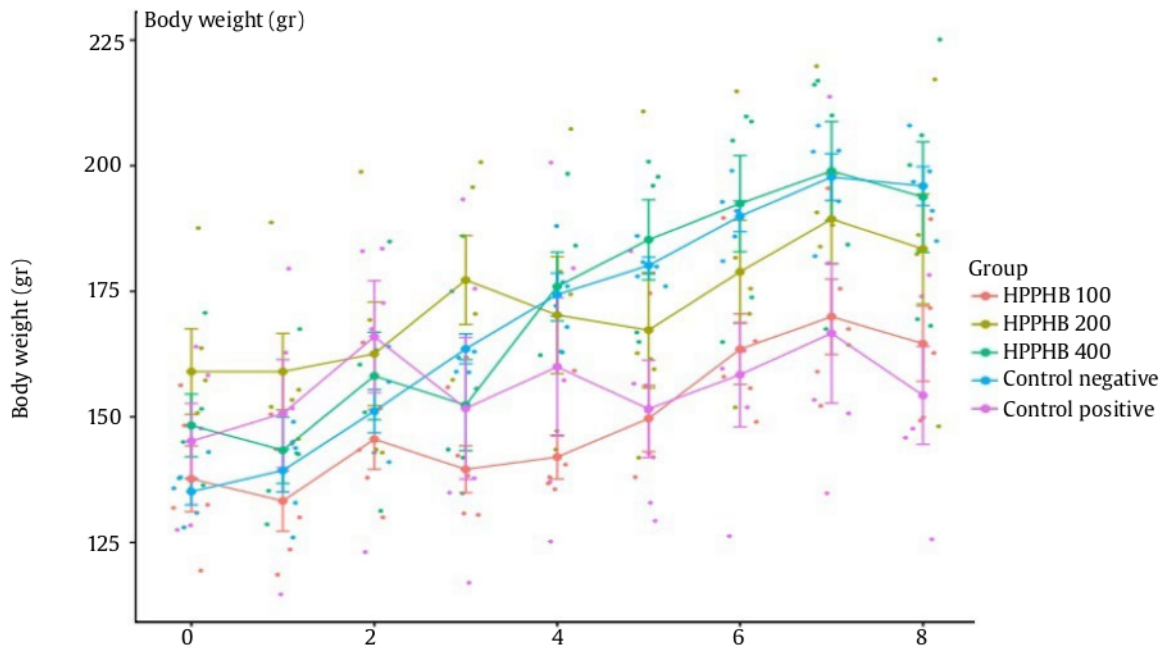


Figure 1. Observation of rat body weight. Weeks 1, 2, 3, 4 rats were induced Cisplatin 2 mg/kg BW/weeks. Weeks 5, 6, 7, 8 rats were given the dose of PHGPB treatment. The difference between the mean final body weight and the mean initial weight of the negative control group = 60.8 g; Cisplatin control = 9.1 g; group Cisplatin+PHGPB 100 = 24.4 g; group Cisplatin+PHGPB 200 = 26.9 g; group Cisplatin+PHGPB 400 = 45.5 g (*significant different from Cisplatin group)

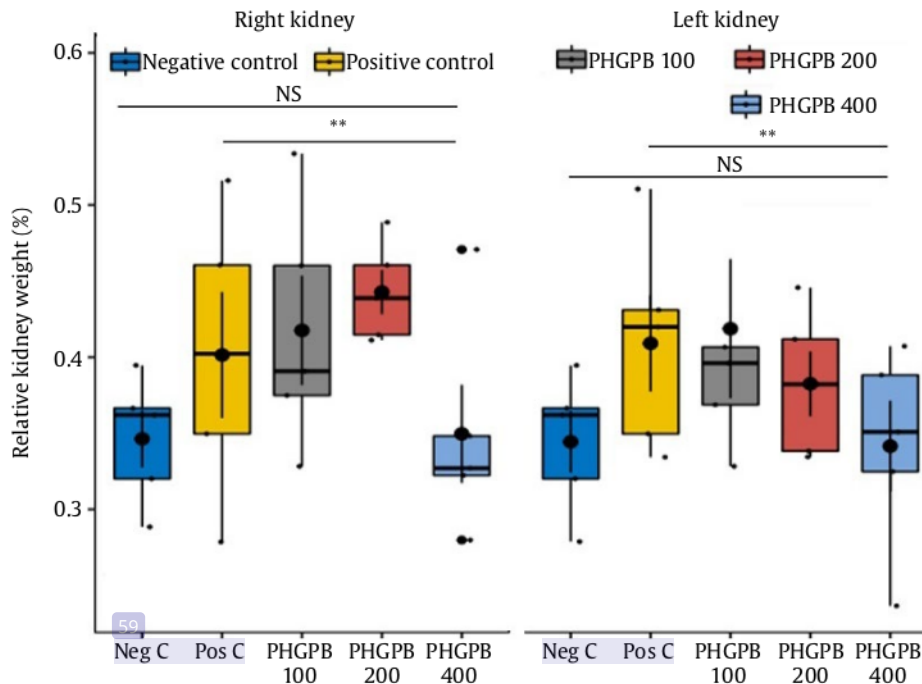


Figure 2. Relative right and left kidney weight of all group of treatment rats comparison between relative kidney weight (RKW) left and right was not significantly different except for the group of Cisplatin+PHGPB 200 mg/kg BW

In the right kidney, the result showed a significant difference between the RKW negative control and the RKW positive control, where the positive control RKW was greater than the negative control RKW. Following with the group of Cisplatin+PHGPB 100 and 200 mg/kg BW ($p < 0.05$). Between the negative control group RKW and the Cisplatin+PHGPB 400 mg/kg BW group there was no significant difference.

Between the RKW of the left kidney, there was a significant difference; the negative control RKW, and the positive control, where the positive control RKW was greater than the negative control RKW, as well as the Cisplatin+PHGPB 100 mg/kg BW group ($p < 0.05$). Between the negative control group, RKW with the dose group of Cisplatin+PHGPB 200 and 400 mg/kg BW did not show a significant difference.

The RKW of the positive control group was greater than the negative control RKW because the weight of the negative control rats was lighter while the kidney weight was a little reduced so that the results of the calculation of the RKW with a smaller divisor factor would show greater results. Our postulate that the Cisplatin-induction effect is much affected on overall body weight than on the kidneys.

3.3. Beta 2 Microglobulin ($\beta 2\text{MG}$)

The results analysis of the mean $\beta 2\text{MG}$ of the cisplatin group were highly significantly different from the negative control group and significantly different from the group of Cisplatin+PHGPB 200 and 400 mg/kg BW, as shown in Figure 3.

3.4. High Sensitive Cell Reactive Protein (hs-CRP)

The level of hs-CRP after 28 days of PHGPB treatment was shown in Figure 4. The results analysis of the mean hs-CRP of the cisplatin group were highly significantly different from the negative control group and Cisplatin+PHGPB 400 mg/kg BW group and significant differences from the Cisplatin+PHGPB 200 mg/kg BW group.

3.5. Histopathological Fibrosis Analysis by Masson Trichrome Staining

Comparative histopathological images between groups are shown in Figure 5. The calculation comparison results are shown in Figure 6.

The cisplatin group showed many blue-stained Aniline cells which indicated that the cells contained cytokeratin and fibroblasts. The results of the analysis of the Cisplatin group or the positive control

group were significantly different from the negative control and the group of Cisplatin+PHGPB 400 mg/kg BW. The Cisplatin+PHGPB 100 mg/kg BW also showed a lot of blue cells and the results of statistical analysis showed that quite a lot of cells had fibrosis and no significant difference with the cisplatin group. Meanwhile, the Cisplatin control showed a significant difference with the PHGPB group at a dose of 200 mg/kg BW ($p < 0.05$) and highly significantly different with the Cisplatin+PHGPB 400 mg/kg BW ($p < 0.01$).

3.6. Histopathology Immunohistochemistry of Cisplatin-induced kidney Rats

Figure 7 showed immunohistochemical staining demonstrated TGF- β expression and their intensity after 28 days of cisplatin injection and PHGPB treatments. A marked increase in TGF- β expression was observed in the cortex at the location of outer stripe of the medulla (tubular and glomerular cells) in Cisplatin group compared to the control group ($p < 0.001$).

3.6.1. Analyses of TGF- β Expression

The results of TGF- β expression comes from the average calculation obtained from ImageJ (NIH) software; the cisplatin group showed a large amount of brown color or TGF B expression indicated that the cells were undergoing a process of fibrosis. Figure 8 showed result analysis of TGF- β expression by immunohistochemistry of kidney histopathology in groups after treatment.

Results of the analysis of the Cisplatin group or the positive control group were significantly different from the negative control group and significantly different from the Cisplatin+PHGPB 400 mg/kg BW. The group of Cisplatin+PHGPB 100 and 200 mg/kg BW showed many brown cells then the results of statistical analysis showed quite a lot of TGF- β expression. The results showed that there was no significant difference with the cisplatin group.

3.6.2. Analysis of TGF- β Intensity

The average calculation results obtained from the ImageJ software (NIH), the cisplatin group showed a scattered and abundant brown color and a dark brown color gradation compared to normal cells indicating a high intensity of TGF- β . Result analysis of TGF- β intensity by immunohistochemistry of kidney histopathology in groups after treatment were shown in Figure 9.

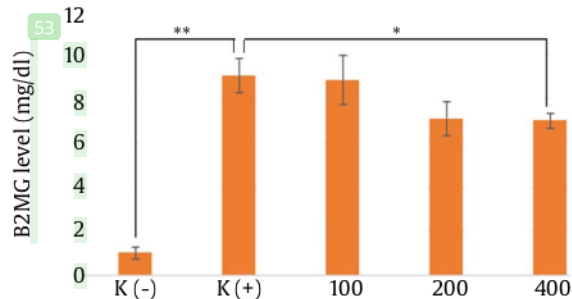


Figure 3. Level of B2MG after 28 days of PHGPB treatment

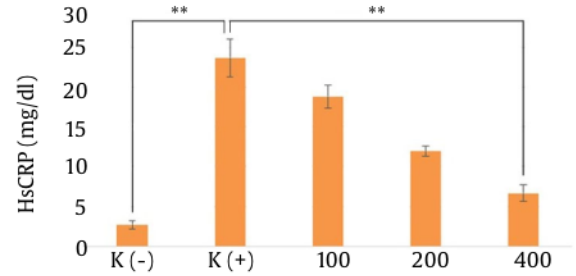


Figure 4. Level of hs-CRP after 28 days of PHGPB treatment

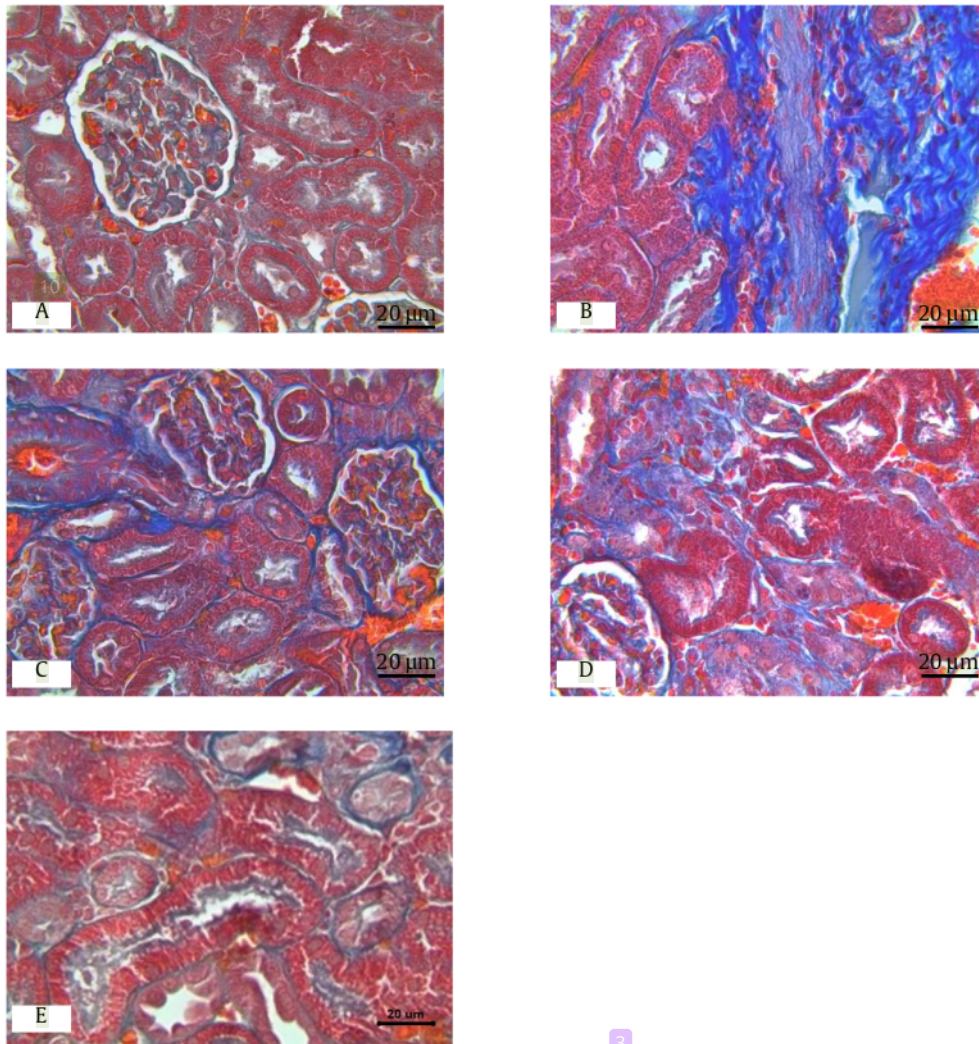


Figure 5. Masson trichrome was used to demonstrate fibrosis (blue color) in the cortex at the location of outer stripe of the medulla after 28 days of cisplatin injection and PHGPB treatments in rats. x 300. (A) Control negative, (B) Cisplatin/positive control, (C) Cisplatin+PHGPB dose of 100, (D) Cisplatin+PHGPB dose of 200, (E) Cisplatin+PHGPB dose of 400. The fibrosis was less evident the Cisplatin+PHGPB 400 (E) and 200 (D) kidneys of the PHGPB treated. Scale bar = 20 µm

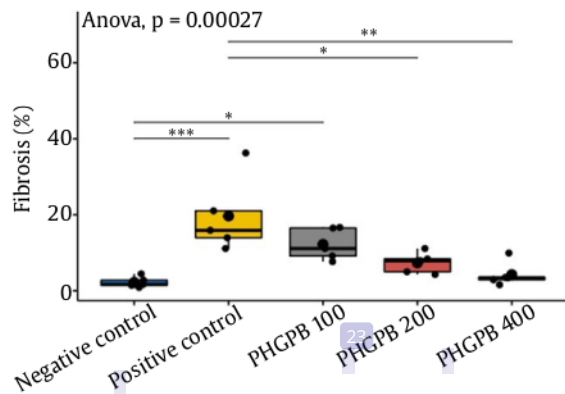


Figure 6. Result analysis of fibrosis percentage by Masson trichrome stain of kidney histopathology in groups after treatment

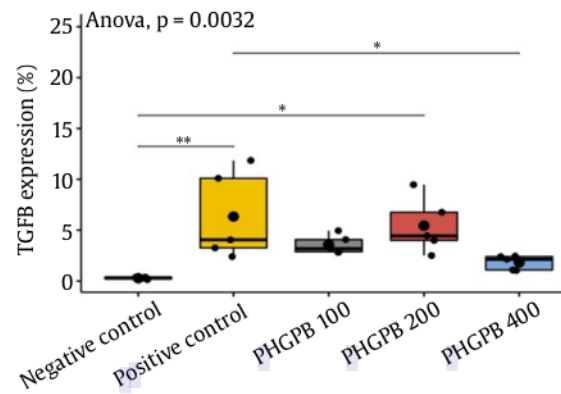


Figure 8. Result analysis of TGF- β expression by Immunohistochemistry of Kidney Histopathology in Groups after Treatment

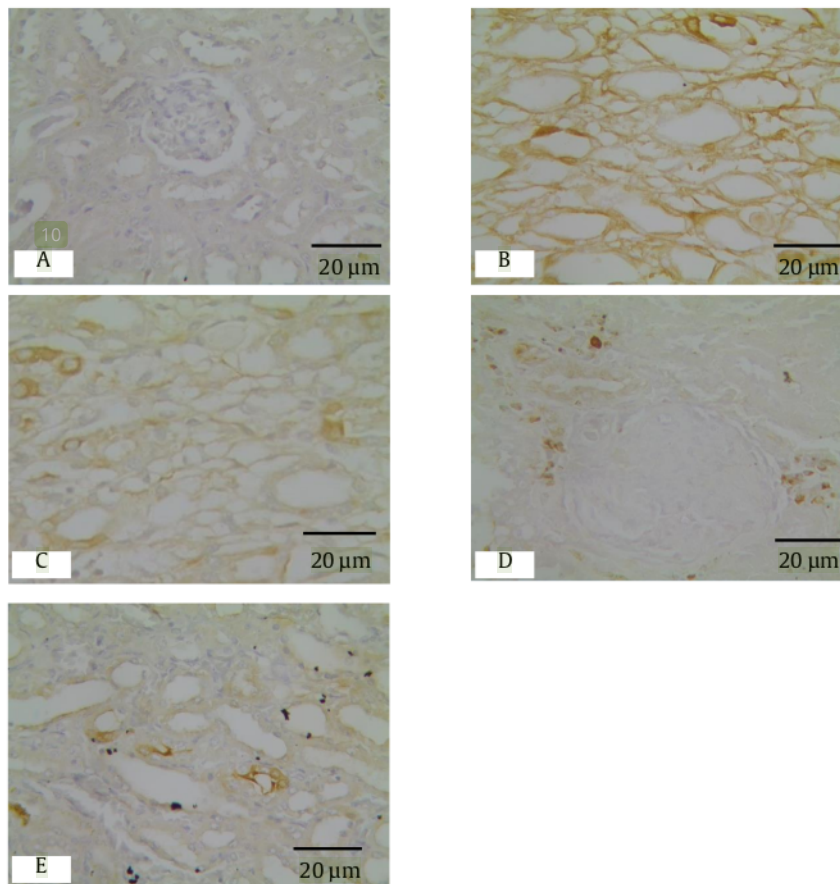


Figure 7. Immunohistochemical staining with TGF- β antibody was used to demonstrate TGF- β expression and their intensity after 28 days of cisplatin injection and PHGPB treatments in the cortex at the location of outer stripe of the medulla (tubular and glomerular cells) of kidney rats. x 300. (A) Negative control, (B) Cisplatin control, (C) Cisplatin+PHGPB dose of 100 mg/kg BW, (D) Cisplatin+PHGPB dose of 200 mg/kg BW, (E) Cisplatin+PHGPB dose of 400 mg/kg BW. The expression of TGF- β was calculated from the whole brown colour in the section. The intensity of TGF- β were counted from the gradual brown colour. Scale bar = 20 μ m.

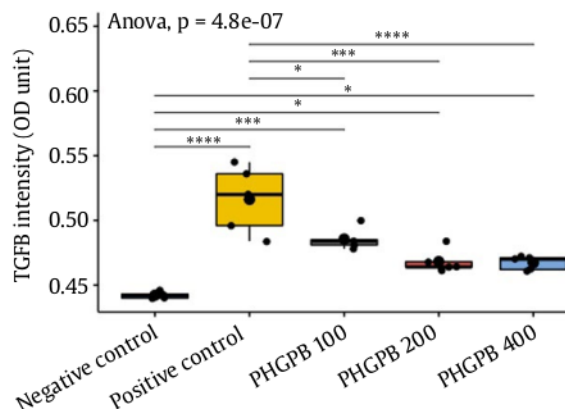


Figure 9. Result analysis of TGF-β intensity by Immunohistochemistry of Kidney Histopathology in Groups after Treatment

The results analysis was of the Cisplatin group significantly different from the negative control group and the Cisplatin+PHGPB 200 and 400 mg/kg BW and significantly different from the PHGPB group at 100 mg/kg BW. However, the Cisplatin+PHGPB group showed significantly different results from the negative control.

4. Discussion

In the current study, a dose of Cisplatin 2 mg/kg BW/week was used at for four weeks (Perse and Veceric-Haler 2018), which is a different dose and regimen from previous studies. It turned out that with the administration of multiple low doses of cisplatin, severe kidney damage and TIF had occurred in the kidneys of SD rats. Measurement of kidney damage with renal function parameters showed a convincing increase in creatinine results, the creatinine levels in the Cisplatin group showed very high mean creatinine results and were very significantly different from negative controls ($p < 0.01$). The Cisplatin+PHGPB groups at all doses showed improvement and a gradual decrease according to the increased dosage ($p < 0.01$) (data not presented). In bodyweight measurements, markedly suppressed body weight gains of the Cisplatin group indicated toxicological effects of Cisplatin. However, the RKW of the cisplatin group was higher than the negative control RKW because the bodyweight of the cisplatin control rats was very low while the kidney weight was few reduced so that the results of the calculation of the RKW with a smaller divisor

factor would show higher results. Our postulate that the effect of Cisplatin induction on overall body weight is much higher than on the kidney's weight. Cisplatin induction does not affect the weight of the kidneys greatly even though the TIF condition may already occur.

TIF is a common pathway leading to organ scarring, accumulation of extracellular membrane (ECM), and the development of CKD (Humphreys 2018). The condition of fibrosis compared to glomerulosclerosis, causes a greater impact on the development of CKD (Panizo *et al.* 2021).

The pivotal cells in the fibrosis process are monocyte-derived macrophages that trigger the production of growth factors such as TGF-β1 in the inflammatory process (Wynn and Vannella 2016). TGF-β1 further mediates the growth of myofibroblastic cells in the extra cellular membrane (ECM) such as collagen and fibronectin with the poor result of formation of fibrotic lesions (Ridruejo *et al.* 2021). Until now there is no effective therapy to inhibit this formation process. To date, there still no definitive effective treatment for renal fibrosis.

Some natural product that has anti-inflammatory actions showed a decreased cisplatin-induced histopathological organ damage. Research about Hesperidin, a natural flavonoid, with anti-inflammatory actions showed that provision of Hesperidin alleviates cisplatin-induced (7.5mg/kg, IP) in histopathologic liver rats without inhibiting its antitumor activity (Omar *et al.* 2016). Algandaby's study showed that quercetin, a dietary flavonoid, protects against cisplatin-induced ovarian toxicity in rats by its anti-inflammatory activities (Algandaby 2021). All the peptides exerted an anti-inflammatory activity, but peptide fraction between 1-3 kDa showed the highest anti-inflammatory effect (Chan-Zapata *et al.* 2019).

Soy-derived protein hydrolysate has shown to reduce inflammation by decreasing the concentration and mRNA expression of the cytokines TNF-α (tumor necrosis factor-alpha), IL-1β (interleukin-1 beta) and IL-6 (interleukin-6), and the expression of TNF-protein in a dose-dependent manner (de Medeiros 2022; Yi *et al.* 2020). A study conducted on rats confirmed the anti-inflammatory and antioxidant activity of yellow pea protein hydrolysate. This anti-inflammatory effect occurs through the mechanisms of inhibition of the production of IL-6 and TNF-α (Ndiaye *et al.* 2012). The anti-inflammatory effect

of PHGPB on β 2MG and hs-CRP assays in this study showed convincing results probably through the similar mechanism, inhibiting the secretion of pro-inflammatory cytokines: IL-6 and TNF- α ; in addition to other possibilities through the mechanism of its antioxidant activity.

The hydrolysates with small molecular weight obtained from ultrafiltration showed the highest antioxidant activities in all relevant assays (Ding and Lin 2020). The protein hydrolysate derived from the hydrolysis of *Pisum sativum* (green peas), whose amino acid sequence is LERGDT, has many bands with small molecular mass < 10 kDa, promising good potential as an antioxidant, especially as a source of SOD (Hidayat *et al.* 2019), and anti-inflammatory also.

In the former study, PHGPB showed a promising result as an antifibrosis treatment in the mesangial cell line (Hidayat *et al.* 2021). In this study, the group of Cisplatin+PHGPB 200 and 400 mg/kg BW showed an anti-fibrosis effect which showed in rat Cisplatin-induced histopathology using Masson trichrome staining ($p < 0.05$). Group of Cisplatin+PHGPB 400 mg/kg BW showed less fibrosis and no significant difference with negative control ($p < 0.01$). While in IHC histopathology, in Cisplatin+PHGPB 400 mg/kg BW group treatment showed a smaller number of TGF- β expression compared to Cisplatin group ($p < 0.005$). PHGPB treatment slightly ameliorated TGF- β expression values showed by the result of Cisplatin+PHGPB group compared to Cisplatin group (Figure 8). PHGPB treatment decreased the intensity of TGF- β convincingly in Cisplatin+PHGPB 200 and 400 mg/kg BW group compared to Cisplatin group ($p < 0.001$) (Figure 9). With a decrease in TGF- β markers, it is hoped that the fibrosis process will not occur.

Histopathological examination is the standard examination to determine the fibrosis process pity this test is invasive and impractical. Inflammatory markers assessment to diagnosed and prevent kidney damage is much more practical and simpler than histopathological examination. Therefore, knowing the role of the inflammatory process in the early stages of kidney fibrosis is very important to understand how to prevent TIF.

The results of the β 2MG and hs-CRP examination showed convincing results. Group of Cisplatin+PHGPB 400 mg/kg BW showed lower results of β 2MG levels than cisplatin control

($p < 0.05$). The administration of all doses showed a decrease in hs-CRP levels according to the number of doses, a higher the PHGPB dose was given a higher low in hs-CRP levels. These results of inflammatory markers are in line with the results of histopathologic analysis, clearly seen especially in the results of the measurement of hs-CRP levels, histopathology feature of fibrosis in Masson trichrome staining, and the intensity of TGF- β in IHC staining.

This result has further strengthened our hypothesis that PHGPB attenuates kidney fibrosis in cisplatin-induced nephrotoxicity rats by its anti-inflammatory activities.

In conclusions, PHGPB can relieve kidney fibrosis in cisplatin-induced nephrotoxicity rats: Emphasis on anti-inflammatory activities.

Acknowledgements

This work was supported by the financial support of Lembaga Penelitian dan Pengabdian Masyarakat (The Institute for Research and Community Service) Universitas Kristen Maranatha. Also, support by Dr Adrian Suhendra SpPK Purwakarta Laboratory, Bandung- Indonesia; Drh Mawar Subangkit in iRatCo Laboratory, Dramaga Bogor; and Dr Ronny Lesmana PhD., AIFO from Physiology Department Universitas Padjadjaran Bandung Indonesia.

References

- Algandaby, M.M., 2021. Quercetin attenuates cisplatin-induced ovarian toxicity in rats: emphasis on antioxidant, anti-inflammatory and anti-apoptotic activities. *Arabian. J. Chem.* 14, 103191. <https://doi.org/10.1016/j.arabjc.2021.103191>
- Avila-Carrasco, L., Majano, P., Sánchez-Toméro, J.P., Selgas, R., López-Cabrera, M., Aguilera, A., Mateo, G.G., 2019. Natural plants compounds as modulators of epithelial-to-mesenchymal transition. *Front. Pharmacol.* 10, 715. <https://doi.org/10.3389/fphar.2019.00715>
- Berchtold, L., Friedli, I., Vallée, J.P., Moll, S., Martin, P.Y., de Seigneux, S., 2017. Diagnosis, and assessment of renal fibrosis: the state of the art. *Swiss Med Wkly.* 11, 147: w14442. <https://doi.org/10.4414/smw.2017.14442>
- Bouteldja, N., Woodman, R.J., Hewitson, C.L., Domingo, E., Barbara, J.A., Mangoni, A.A., 2013. Methylated arginines and nitric oxide in end-stage renal disease: of inflammation, oxidative stress and haemodialysis. *Biomarkers.* 18, 357-364. <https://doi.org/10.3109/1354750X.2013.795608>
- Burtis, C.A., Ashwood, E.R., Bruns, D.E., 2015. Tietz fundamentals of clinical chemistry and molecular diagnostics. *Indian Journal of Clinical Biochemistry.* 28. <https://doi.org/10.1007/s12291-012-0287-7>

- Chan-Zapata, I., Arana-Argáez, V.E., Torres-Romero, J.C., Segura-Campos, M.R., 2019. Anti-inflammatory effects of the protein hydrolysate and peptide fractions isolated from *Salvia hispanica* L. seeds. *F. Agric. Immunol.* 30, 786-803. <https://doi.org/10.1080/09540105.2019.1632804>
- de Medeiros, A.F., de Queiroz, J., Maciel, B., de Araújo Morais, A.H., 2022. Hydrolyzed proteins and vegetable peptides: anti-inflammatory mechanisms in obesity and potential therapeutic targets. *Nutrients.* 14, 690. <https://doi.org/10.3390/nu14030690>
- Ding, J., Lin, S., 2020. Optimization of pea protein hydrolysate preparation and purification of antioxidant peptides based on an *in silico* analytical approach. *LWT Elsevier.* 2, 123. <https://doi.org/10.1016/j.lwt.2020.109126>
- Gewin, L.S., 2018. Renal fibrosis: primacy of the proximal tubule. *Matrix Biol.* 68-69, 248-262. <https://doi.org/10.1016/j.matbio.2018.02.006>
- Gusev, E., Solomatina, L., Zhuravleva, Y., Sarapultsev, A., 2021. The pathogenesis of end-stage renal disease from the standpoint of the theory of general pathological processes of inflammation. *Int. J. Mol. Sci.* 22, 11453. <https://doi.org/10.3390/ijms222111453>
- Hidayat, M., Prahastuti, S., Wahyudianingsih, R., Wargasetia, T.L., Ferdinand, V., Soemardji, A.A., Rachmawati, S.F., Suliska, N., Hasan, K., 2019. Role of pea protein hydrolysates as anti-nephrotoxicity. *J. Pharm. Res. Sci.* 8, 55-60. https://doi.org/10.4103/jrptps.jrptps.14_17
- Hidayat, M., Prahastuti, S., Yusuf, M., Hasan, K., 2021. Nutrition profile and role of RGD in protein hydrolysate green peas as antifibrosis in chronic kidney disease. *Iran. J. B. Med. Sci.* 24, 734-743.
- Humphreys, B.D., 2018. Mechanisms of renal fibrosis. *Annu. Rev. Physiol.* 80, 309-326. <https://doi.org/10.1146/annurev-physiol-022516-034227>
- Laemmli, U.K., 1970. Cleavage of structural proteins during the assembly of the head of the bacteriophage T4. *Nature.* 227, 679-685. <https://doi.org/10.1038/227680a0>
- Landry, A., Docherty, P., Ouellette, S., Cartier, L.J., 2017. Causes and outcomes of markedly elevated C-reactive protein levels. *Canadian Fam Phy (Medecin de famille canadien).* 63, 316-323.
- Li, L., Dong, M., Wang, X.G., 2016. The implication and significance of beta 2 microglobulin: a conservative multifunctional regulator. *Chin. Med. J. (Engl).* 129, 448-455. <https://doi.org/10.4103/0366-6999.176084>
- Luan, Y.Y., Yao, Y.M., 2018. The clinical significance and potential role of c-reactive protein in chronic inflammatory and neurodegenerative diseases. *Frontiers in Immunology.* 9, 1302. <https://doi.org/10.3389/fimmu.2018.01302>
- Mc Sweeney, K.R., Gadanec, L.K., Qaradakh, T., Ali, B.A., Zulli, A., Apostolopoulos, V., 2021. Mechanisms of Cisplatin-induced acute kidney injury: pathological mechanisms, pharmacological interventions, and genetic mitigations. *Cancers.* 13, 1572. <https://doi.org/10.3390/cancers13071572>
- Medical Dictionary, 2021. Available at: <https://medical-dictionary.thefreedictionary.com/Chronic+Kidney+Failure>. [Date accessed: 16 August 2021]
- Microscopy Alliance the University of Arizona, 2022. Bouin's Fixative. Available at: <https://www.microscopy.arizona.edu/learn/bouins-fixative>. [Date accessed: 19 October 2022]
- Ndiaye, F., Vuong, T., Duarte, J., Aluko, R.E., Matar, C., 2012. Antioxidant, anti-inflammatory and immunomodulating properties of an enzymatic protein hydrolysate from yellow field pea seeds. *Eur J Nutr.* 51, 29-37. <https://doi.org/10.1007/s00394-011-0186-3>
- Nematbakhsh, M., Ebrahimian, S., Tooyserkani, M., Eshraghi-Jazi, F., Talebi, A., Ashrafi, F., 2013. Gender difference in Cisplatin-induced nephrotoxicity in a rat model: Greater intensity of damage in male than female. *Nephro-Urol Monthly.* 5, 818-821.
- Omar, H.A., Mohamed, W.R., Arafa, el-S.A., Shehata, B.A., El Sherbiny, G.A., Arab, H.H., Elgendy, A.N., 2016. Hesperidin alleviates cisplatin-induced hepatotoxicity in rats without inhibiting its antitumor activity. *Pharmacological Reports.* 68, 349-356. <https://doi.org/10.1016/j.pharep.2015.09.007>
- Panizo, S., Martínez-Arias, L., Alonso-Montes, C., Cannata, P., Martín-Carro, B., Fernández-Martín, J.L., Naves-Díaz, M., Carrillo-López, N., Cannata-Andía, J.B., 2021. Fibrosis in chronic kidney disease: pathogenesis and consequences. *Int. J. Mol. Sci.* 22, 408. <https://doi.org/10.3390/ijms22010408>
- Perse, Veceric-Haler, 2018. Cisplatin-induced rodent model of kidney injury: characteristics and challenges. *BioMed. Res. Int.* 2018, 1-29. <https://doi.org/10.1155/2018/1462802>
- Portales-Castillo, I., Yee, J., Tanaka, H., Fenves, A.Z., 2020. Beta-2 microglobulin amyloidosis: past, present, and future. *Kidney360.* 1, 1447-1455. <http://doi.org/10.34067/KID.0004922020>
- Ridruejo, E., Romero Caimi, G., Miret, N., Obregón, M.J., Randi, A., Deza, Z., Kleiman de Pisarev, D., Alvarez, L., 2021. TGF-β1 mediates cell proliferation and development of hepatocarcinogenesis by downregulating deiodinase 1 expression. La desregulación de la deiodinasa 1, mediada por TGF-β1, impulsa la proliferación celular y el desarrollo de hepatocarcinogénesis. *Medicina.* 81, 346-358.
- Tibúrcio, F.R., Rodrigues, K.E.S., Belisário, A.R., Simões-E-Silva, A.C., 2018. Glomerular hyperfiltration and β-2 microglobulin as biomarkers of incipient renal dysfunction in cancer survivors. *Future Sci OA.* 4, F50333. <https://doi.org/10.4155/fsoa-2018-0045>
- Topçiu-Shufta, V., Miftari, R., Haxhibeqiri, V., Haxhibeqiri, S., 2016. Association of beta-2 microglobulin with inflammation and dislipidemia in high-flux membrane hemodialysis patients. *Med. Arch.* 70, 348-350. <https://doi.org/10.5455/medarh.2016.70.348-350>
- Universitas Kristen Maranatha, Bandung Indonesia. Patent P 00201907647. Granted: August 24, 2021. Pembuatan dan Pengujian Hidrolisat Protein Kacang Polong Hijau (*Pisum sativum*) sebagai Antifibrosis untuk Terapi Penyakit Ginjal Kronis. Production and Testing of Green Pea Protein Hydrolysate (*Pisum sativum*) as Antifibrosis for Chronic Kidney Disease Therapy.
- Wan, C., Nisar, M.F., Wu, H., 2022. Pharmacological activities of natural products through the TGF-β signalling pathway. Editorial. *Evidence-Based Compl Alt Med. Hindawi.* 2022, 1-2. <https://doi.org/10.1155/2022/9823258>. DOI 10.1155/2022/9823258
- Wynn, T.A., Vannella, K.M., 2016. Macrophages in tissue repair, regeneration, and fibrosis. *Immunity.* 44, 450-462. <https://doi.org/10.1016/j.immuni.2016.02.015>
- Yi G., Li H., Liu M., Ying Z., Zhang J., Liu X., 2020. Soybean protein-derived peptides inhibit inflammation in LPS-induced RAW264.7 macrophages via the suppression of TLR4-mediated MAPK-JNK and NF-kappa B activation. *J. Food Biochem.* 44, e13289. <https://doi.org/10.1111/jfbc.13289>
- Yue, L., Pan, B., Shi, X., Du, X., 2020. Comparison between the Beta-2 microglobulin-based equation and the CKD-EPI equation for estimating GFR in CKD patients in China: ES-CKD Study. *Kidney Diseases.* 6, 204-214. <https://doi.org/10.1159/000505850>

3. Protein Hydrolysate of Green Peas Bromelain Attenuates Kidney Fibrosis in Cisplatin-Induced Nephrotoxicity Rats

ORIGINALITY REPORT

24%

SIMILARITY INDEX

18%

INTERNET SOURCES

16%

PUBLICATIONS

4%

STUDENT PAPERS

PRIMARY SOURCES

- 1 Meilinah Hidayat, Khomaini Hasan, Muhamad Yusuf, Sriwidodo Sriwidodo, Camellia Panatarani, I Made Joni. "Nano Delivery Chitosan-Protein/Hydrolysate of Green Peas Bromelain (PHGPB) Synthesized by Colloidal-Spray Drying Method", *Polymers*, 2023
Publication 2%
- 2 Meilinah Hidayat, Sijani Prahastuti, Anggie S. Rakasiwi, Sipra Prisilia, Khomaini Hasan. "Sub-chronic toxicity study of green peas protein hydrolysate in rats", *Toxicology Reports*, 2022
Publication 1%
- 3 www.nature.com
Internet Source 1%
- 4 www.journal-jop.org
Internet Source 1%
- 5 www.mdpi.com
Internet Source 1%
- 6 dmec.moh.gov.vn
Internet Source 1%

7	IFMBE Proceedings, 2009. Publication	1 %
8	www.frontiersin.org Internet Source	1 %
9	journalarticle.ukm.my Internet Source	1 %
10	core.ac.uk Internet Source	1 %
11	Meilinah Hidayat, Sijani Prahastuti, Ervi Afifah, Wahyu Widowati, Muhammad Yusuf, Khomaini Hasan. "The role of green peas protein hydrolysate in TGF/ SMAD signaling to prevent renal fibrosis", Journal of King Saud University - Science, 2022 Publication	1 %
12	scholar.unand.ac.id Internet Source	<1 %
13	"Renal Fibrosis: Mechanisms and Therapies", Springer Science and Business Media LLC, 2019 Publication	<1 %
14	epdf.tips Internet Source	<1 %
15	ijbms.mums.ac.ir Internet Source	<1 %

16	oamjms.eu Internet Source	<1 %
17	www.jlbsr.org Internet Source	<1 %
18	Submitted to Universitas Jenderal Achmad Yani Student Paper	<1 %
19	www.tandfonline.com Internet Source	<1 %
20	acervodigital.ufpr.br Internet Source	<1 %
21	journal2.unusa.ac.id Internet Source	<1 %
22	Submitted to Queen Mary and Westfield College Student Paper	<1 %
23	inchem.org Internet Source	<1 %
24	Submitted to Sheffield Hallam University Student Paper	<1 %
25	journals.lww.com Internet Source	<1 %
26	swehsc.pharmacy.arizona.edu Internet Source	<1 %

27	repository.maranatha.edu Internet Source	<1 %
28	Ehab A.M. El-Shoura, Basim A.S. Messiha, Souty M.Z. Sharkawi, Ramadan A.M. Hemeida. "Perindopril ameliorates lipopolysaccharide-induced brain injury through modulation of angiotensin-II/angiotensin-1-7 and related signaling pathways", <i>European Journal of Pharmacology</i> , 2018 Publication	<1 %
29	patents.justia.com Internet Source	<1 %
30	www.steviainfo.com Internet Source	<1 %
31	Julia Windi Gunadi, Vita Murniati Tarawan, Iwan Setiawan, Hanna Goenawan et al. "Adaptation of aerobic training essentially involved autophagy, mitochondrial marker and muscle fibre genetic modulation in rat cardiac muscles", <i>Journal of Animal Physiology and Animal Nutrition</i> , 2019 Publication	<1 %
32	coek.info Internet Source	<1 %
33	Amal Al-Shahat, Mohey A. E. Hulail, Nada M. M. Soliman, Tarek Khamis et al. "Melatonin	<1 %

Mitigates Cisplatin-Induced Ovarian Dysfunction via Altering Steroidogenesis, Inflammation, Apoptosis, Oxidative Stress, and PTEN/PI3K/Akt/mTOR/AMPK Signaling Pathway in Female Rats", *Pharmaceutics*, 2022

Publication

34

Qinghua Wang, Tongxin Zhi, Panpan Han, Siting Li, Junxia Xia, Zhou Chen, Chong Wang, Yongling Wu, Yingmin Jia, Aijin Ma. "Potential anti-inflammatory activity of walnut protein derived peptide leucine-proline-phenylalanine in lipopolysaccharides-irritated RAW264.7 cells", *Food and Agricultural Immunology*, 2021

Publication

<1 %

35

ejournal.umm.ac.id

Internet Source

<1 %

36

phcogj.com

Internet Source

<1 %

37

worldwidescience.org

Internet Source

<1 %

38

www.koreascience.or.kr

Internet Source

<1 %

39

www.preprints.org

Internet Source

<1 %

40	www.dovepress.com Internet Source	<1 %
41	Enrico Campioli, Sunghoon Lee, Matthew Lau, Lucas Marques, Vassilios Papadopoulos. "Effect of prenatal DINCH plasticizer exposure on rat offspring testicular function and metabolism", Scientific Reports, 2017 Publication	<1 %
42	elifesciences.org Internet Source	<1 %
43	journals.plos.org Internet Source	<1 %
44	link.springer.com Internet Source	<1 %
45	macsphere.mcmaster.ca Internet Source	<1 %
46	theses.gla.ac.uk Internet Source	<1 %
47	Changlu Xu, Jian He, Hongtao Wang, Yingnan Zhang et al. "Single-cell transcriptomic analysis identifies an immune-prone population in erythroid precursors during human ontogenesis", Nature Immunology, 2022 Publication	<1 %

48 Evelin Fabjan, Etje Hulzebos, W. Mennes, A. H. Piersma. "A Category Approach for Reproductive Effects of Phthalates", Critical Reviews in Toxicology, 2008

Publication

<1 %

49 K. W. Allen, M. Smith. "A Cold Chromate Etch Treatment for some Aluminium Alloys", The Journal of Adhesion, 2007

Publication

<1 %

50 Submitted to School of Business and Management ITB

Student Paper

<1 %

51 bmcgenomics.biomedcentral.com

Internet Source

<1 %

52 eprints.mums.ac.ir

Internet Source

<1 %

53 ir.uiowa.edu

Internet Source

<1 %

54 mdpi-res.com

Internet Source

<1 %

55 pubmed.ncbi.nlm.nih.gov

Internet Source

<1 %

56 rcastoragev2.blob.core.windows.net

Internet Source

<1 %

57 smw.ch

Internet Source

<1 %

58

static.frontiersin.org

Internet Source

<1 %

59

Decui Liang, Dun Liu. "Systematic studies on three-way decisions with interval-valued decision-theoretic rough sets", Information Sciences, 2014

Publication

<1 %

60

JuXiang Mei, LingLing Yang, Deqin Wang, HaiXia Wang. "Efficacy and safety of Shenkang injection in the treatment of chronic renal failure", Medicine, 2021

Publication

<1 %

61

Mahrous A. Ibrahim, Athar M. Khalifa, Alaa A. Mohamed, Rania A. Galhom et al. "Bone-Marrow-Derived Mesenchymal Stem Cells, Their Conditioned Media, and Olive Leaf Extract Protect against Cisplatin-Induced Toxicity by Alleviating Oxidative Stress, Inflammation, and Apoptosis in Rats", Toxics, 2022

Publication

<1 %

62

downloads.hindawi.com

Internet Source

<1 %

63

wprim.whoocc.org.cn

Internet Source

<1 %

64

Liang Xiong, Jinyu Huang, Chunmei Wu, Qiong Yuan, Sihui Wang, Liye Zhu, Zilu Li, Ziyue Sun, Yi Fang, Weisong Li, Gonghua Hu. "Yttrium chloride induces ferroptosis in cardiomyocytes via iron accumulation and triggers cardiac lipid peroxidation and inflammation that cause heart adverse events in mice", *Ecotoxicology and Environmental Safety*, 2023

Publication

<1 %

65

Shuai Hu, Juanli Yuan, Jinyan Gao, Yong Wu, Xuanyi Meng, Ping Tong, Hongbing Chen. "Antioxidant and Anti-Inflammatory Potential of Peptides Derived from In Vitro Gastrointestinal Digestion of Germinated and Heat-Treated Foxtail Millet () Proteins ", *Journal of Agricultural and Food Chemistry*, 2020

Publication

<1 %

66

Xilin Zhao, Xuelan He, Wentao Wei, Kaipeng Huang. "USP22 aggravated diabetic renal tubulointerstitial fibrosis progression through deubiquitinating and stabilizing Snail1", *European Journal of Pharmacology*, 2023

Publication

<1 %

Exclude bibliography On