




## Vol. 9 No. 2 (2023): July



Published: 2023-06-25

### Research Article

#### **RADIOLOGICAL EVALUATION OF SINONASAL, INTRAORBITAL AND INTRACRANIAL EXTENSION OF MUCORMYCOSIS IN POSTCOVID PATIENTS**

Tushar Kalekar, Varsha Rangankar, Pooja Karanjule, Radhika Jaipuria, Sahil Kathuria, Neeraj Patil, Girish NK  
76-81



PDF

#### **SUSCEPTIBILITY WEIGHTED IMAGING TECHNIQUE UTILITY IN DIVERSE NEUROLOGICAL ENTITIES**

Vijetha Chanabasanavar, Sanjay Khaladkar, Darshana Dilip, Satvik Dhirawani, Vinay Kumar Parripati  
82-87



PDF

#### **EFFICACY OF INTRAVENOUS TIROFIBAN THERAPY IN LACUNAR STROKE PATIENTS**

Ahmet Yabalak, Petek Sarli, Murat Yilmaz, Hilmiye Tokmak, Muhammed Nur Ogun  
88-92



PDF

## **ASSOCIATION BETWEEN SLEEP QUALITY AND GERIATRIC SYNDROMES IN NURSING HOME RESIDENTS**

Tuğba Turgut, Remzi Bahşi, Deniz Mut Sürmeli, Hande Selvi Özturun, Çağlar Coşardereİiğođlu, Volkan Atmıř, Ahmet Yalçın, Murat Varlı, Sevgi Aras

93-98



PDF

## **THE RELATIONSHIP OF EPILEPTIFORM WAVES IN ELECTROENCEPHALOGRAM WITH EPILEPSY TYPE OF SCHOOL-AGE EPILEPSY PATIENTS**

Jerome Constantine Lekatompessy, Bertha Jean Que, Laura Bianca Sylvia Huwae

99-101



PDF

## **POOR COGNITIVE RESERVE STATUS AS PREDICTORS OF MEMORY IMPAIRMENT AMONG ELDERLY**

Herpan Syafii Harahap, Yanna Indrayana

102-106



PDF

## **ASSOCIATION OF PHYSICIAN BURNOUT WITH HEADACHE AND LOW BACK PAIN DURING PANDEMIC COVID-19**

Kharisma Ridho Husodo, Dea Hadfina Kartika Sari, Lintang Daru Jati, Airin Angelina

107-112



PDF

## **NEUROPROTECTANT OF 7,8-DIHYDROXYFLAVONE IN ISCHEMIC STROKE THROUGH MODULATION GLUTATHIONE S-TRANSFERASE AND TYROSINE RECEPTOR KINASE C: A BIOINFORMATICS STUDY**

Aldita Husna Violita, Safira Dita Arviana, Rislan Faiz Muhammad, Basyar Adnani, Titin Andri Wihastuti, Husnul Khotimah, Shahdevi Nandar Kurniawan, Yuyun Yueniwati

113-121



PDF

## **CLINICAL CHARACTERISTICS OF LACUNAR ISCHEMIC STROKE PATIENTS**

Anindyta Murfia Khairunnisa, Lisda Amalia , Eppy Buchori Aristiady, Harry Galuh Nugraha, Asep Nugraha Hermawan

122-128



PDF

## **THE DEPICTION OF GENERAL PHYSICIAN'S KNOWLEDGE LEVEL OF PARKINSON'S DISEASE IN INDONESIA**

Neila Raisa, Adeliza Firzarosany Insanitaqwa, Masruroh Rahayu

129-133



PDF

## **PATTERN OF ANTICOAGULANT THERAPY IN CARDIOEMBOLIC STROKE**

Reihan Achmad Reza, Lisda Amalia, Nushrotul Lailiyya Dahlan, Cep Juli, Hanna Goenawan

134-138



PDF

## **BIOINFORMATICS STUDY OF 7,8-DIHYDROXYFLAVONE AS A NEUROPROTECTIVE AGENT IN ISCHEMIC STROKE VIA TRKB REGULATION AND GLUTAMINASE INHIBITION**

Rislan Faiz Muhammad, Basya Adnani, Safira Dita Arviana, Aldita Husna Violita, Husnul Khotimah, Shahdevi Nandar Kurniawan, Mokhamad Fahmi Rizki Syaban, Yuyun Yueniwati Prabowowati Wadjib, Masruroh Rahayu

139-145



PDF

## **Review**

### **SLEEP DISTURBANCE AFTER TRAUMATIC BRAIN INJURY: NEW INSIGHT**

Desak Ketut Indrasari Utami, Faldi Yaputra

145-148



PDF

### **CLINICAL SIGNIFICANCE OF INTRAOPERATIVE NEUROPHYSIOLOGICAL MONITORING DURING SCOLIOSIS SURGERY: A LITERATURE REVIEW**

Sylvia Tanumihardja, Dedeh Supantini, Julia Windi Gunadi, Ardo Sanjaya, Katherine Marcella

149-153



PDF

### **THE POTENTIAL OF STEM CELL THERAPY AS A MANAGEMENT OF CHRONIC PAIN: A SYSTEMATIC REVIEW**

Putu Yogi Pramana, Agung Bagus Sista Satyarsa, Ida Ayu Sri Wijayanti, Anak Agung Raka Sudewi

154-160



PDF

# Case Report

## PSYCHOLOGICAL TREATMENT VARIANT WITH EYE MOVEMENT DESENSITIZATION AND REPROCESSING: A CASE REPORT

Alejandro Checa

161-164

 PDF

## MULTIPLE SCHMORL'S NODES ON YOUNG ADULT WITH MYOFASCIAL PAIN SYNDROME: A CASE REPORT

I Gusti Agung Ayu Andra Yusari, Putu Gede Sudira, Ida Ayu Sri Wijayanti

165-167

 PDF

## PANCOAST TUMOR PRESENTING WITH HORNER SYNDROME: A CASE REPORT

Raden Andi Ario Tedjo, Hillary Hillary, Vivienne Tjung, Stefanus Erdana Putra, Muhammad Hafizhan

168-171

 PDF

## THE IMPORTANT OF NEUROPHYSIOLOGY EXAMINATION IN DIAGNOSING SEGMENTAL ZOSTER PARESIS: CASE REPORT

Eric Hartono Tedyanto, Ni Made Dwita Pratiwi, I Komang Arimbawa, I Putu Eka Widyadharma

172-174

 PDF

[Make a Submission](#)

## AUTHOR GUIDELINES

[Online Version](#)

[PDF Version](#)


[MNJ Template](#)

[Copyright Transfer Agreement Form](#)

## ABOUT MNJ

[Aim and Scope](#)  
[Editorial Board](#)  
[Indexing](#)  
[Citedness in Scopus](#)

## TOOLS








[Mendeley User Guide](#)

INDEX





DAILY VISITOR STATISTIC

COUNTRY	UNIQUE VISITORS
 United States	64.9% 98
 Indonesia	7.9% 12
 Brazil	4.6% 7
 Taiwan	4.6% 7
 Turkey	4% 6

1–5 of 15

Note: You are using the default location provider, which means Matomo will guess the visitor's location based on the language they use. [Read this](#) to learn how to setup more accurate geolocation.

## Information

[For Readers](#)

[For Authors](#)

[For Librarians](#)

## Current Issue

[ATOM 1.0](#)

[RSS 2.0](#)

[RSS 1.0](#)

Platform &  
workflow by  
**OJS / PKP**



# CLINICAL SIGNIFICANCE OF INTRAOPERATIVE NEUROPHYSIOLOGICAL MONITORING DURING SCOLIOSIS SURGERY: A LITERATURE REVIEW

Sylvia Tanumihardja<sup>1</sup>, Dedeh Supantini<sup>1</sup>, Julia Windi Gunadi<sup>2</sup>, Ardo Sanjaya<sup>3</sup>, Katherine Marcella<sup>4</sup>

**Correspondence:** [katherinemarcellaliem@gmail.com](mailto:katherinemarcellaliem@gmail.com)

<sup>1</sup> Department of Neurology, Faculty of Medicine, Maranatha Christian University, Bandung, Indonesia.

<sup>2</sup> Department of Physiology, Faculty of Medicine, Maranatha Christian University, Bandung, Indonesia.

<sup>3</sup> Department of Anatomy, Faculty of Medicine, Maranatha Christian University, Bandung, Indonesia.

<sup>4</sup> Faculty of Medicine, Maranatha Christian University, Bandung, Indonesia.

## Article History:

Received: September 20, 2022

Accepted: April 27, 2023

Published: July 1, 2023

## Cite this as:

Utami DKI, Yaputra F. Clinical significance of intraoperative neurophysiological monitoring during scoliosis surgery: A literature review. *Malang Neurology Journal*; 2023.9:149-153. DOI: <http://dx.doi.org/10.21776/ub.mnj.2023.009.02.14>

## ABSTRACT

Mechanical damage to nerve fibers during scoliosis correction can result in severe neurological disorders. It has been demonstrated that intraoperative neurophysiological monitoring during spinal surgery reduces the risk of motor deficits or paraplegia. Despite significant advances in the technique and application of IONM (intraoperative neurophysiological monitoring), data reporting the impact of implementing intraoperative neurophysiological monitoring on scoliosis surgery intervention remains very limited. Therefore, this review aims to investigate the correlation between the application of IONM and the risk of neurologic deficits in scoliosis patients undergoing surgery. The database sourced from PubMed (Jan 2010 to Jan 2022) was used to identify all studies evaluating the effectiveness and impact of intraoperative neurophysiological monitoring during scoliosis surgery and reducing the risk of postoperative complications. This systematic review included five studies. Multimodal IONM, with its high sensitivity and specificity, provides an objective benchmark that surgeons can implement to review surgical strategies to reduce the risk of permanent neurologic deficits. Multimodal IONM can be considered the gold standard of IONM in scoliosis surgery to prevent neurological damage and provide a more satisfactory result of surgical intervention.

**Keywords:** Intraoperative neurophysiological monitoring, neuromonitoring, neurological deficit, scoliosis surgery, spinal cord compression.

## Introduction

Scoliosis is a spinal deformity characterized by lateral curvature and spine rotation. The causes of scoliosis are varied and broadly classified as congenital, neuromuscular, syndrome-related, idiopathic, and scoliosis due to secondary etiology.<sup>1</sup> Although it can be caused by various factors, more than 60% of all cases of scoliosis is considered idiopathic, of which 80% occur in adolescence.<sup>2</sup> According to the American Family Physician, women are ten times more likely than men to develop the degree of curvature of the scoliosis curve.<sup>3</sup>

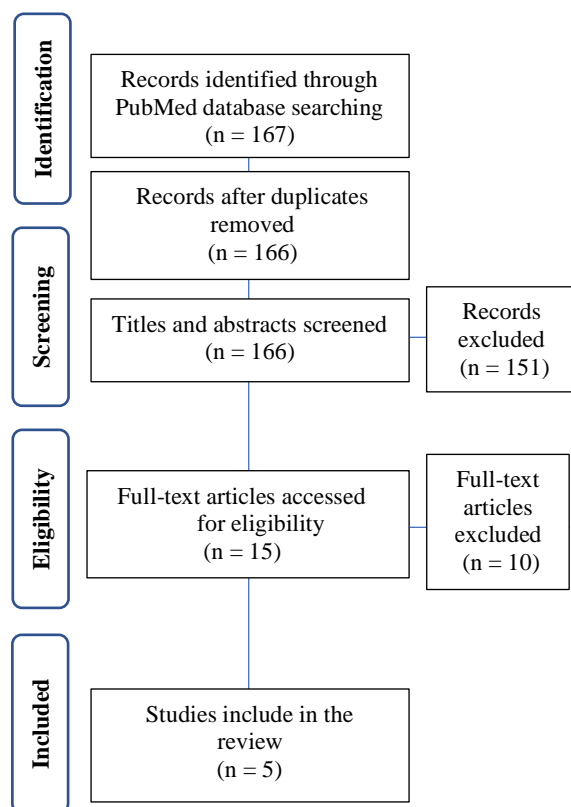
Scoliosis patients can benefit from surgery as one of their treatment options. The surgical intervention aims to halt the progression of scoliosis, correct the deformity permanently, and improve posture balance.<sup>4</sup> Currently, osteotomy, scoliosis correction, and screw implantation are the main options in treating scoliosis cases. However, this surgery is not entirely exempt from the risk of neurological damage in both the intra- and postoperative periods. Mechanical damage caused by nerve fiber stretching during scoliosis correction can result in severe neurological disorders. Furthermore, the incidence of misplaced screw implantation

cases ranges from 20% to 30%, and 1% suffer nerve damage, which leads to severe consequences such as paralysis.<sup>5</sup>

A monitoring system that provides real-time feedback on the patient's nerve function during the surgical procedure is required to mitigate this risk. Intraoperative neurophysiological monitoring (IONM) is used to monitor the functional modalities of a particular neural structure (nerves, spinal cord, and parts of the brain) during surgery. It has been demonstrated that intraoperative neurophysiological monitoring during spinal surgery reduces the risk of motor deficits or paraplegia.<sup>6</sup> The procedure has recently proliferated, and more than 800,000 surgical procedures are implemented in the US each year to reduce the incidence of neurological complications.<sup>7,8</sup> Despite significant advances in the technique and application of IONM, data reporting the impact of implementing intraoperative neurophysiological monitoring on scoliosis surgery remains very limited. Therefore, this review aims to investigate the correlation between the application of IONM and the risk of neurologic deficits in scoliosis patients undergoing surgery.

## Methods

The database sourced from PubMed (Jan 2010 to Jan 2022) was used to identify all studies evaluating the effectiveness and impact of intraoperative neurophysiological monitoring during the surgical intervention process to treat scoliosis and reduce the risk of postoperative complications. Excluded literature included conference abstracts, book chapters, editorial work, dissertations or theses, and unfinished research. Laboratories and non-human studies, as well as articles with unavailable full-text, languages other than English, and irrelevant topics, were omitted. Every study with intraoperative neurophysiological monitoring in scoliosis patients is included. The following medical subject headings were used for a literature search: (scoliosis) AND (neuromonitoring).



**Figure 1.** Flow Diagram of Study Selection

## Results

The study selection is presented in Figure 1. We performed a PubMed search. A total of 167 records were observed, with 166 remaining after duplicate removal. Title and abstracts were screened, leaving 15 potential studies. Full-text paper of each 15 studies was evaluated for eligibility criteria, and 10 were excluded due to insufficient data on intraoperative neurophysiological monitoring. The remaining five studies were included in this systematic review. There are two retrospective studies and one study population in table 1, which evaluate the application of intraoperative neurophysiological neuromonitoring during scoliosis surgery. These studies were conducted by Nassef *et al.*<sup>9</sup>; George *et al.*<sup>10</sup>; Ajiboye *et al.*<sup>11</sup>. Table 2, on the other hand, includes one retrospective and one prospective study that compares the implication of unimodal and multimodal

IONM. These studies include Bhagat *et al.*<sup>12</sup>; Kundnani *et al.*<sup>13</sup>

## Discussion

Intraoperative neurophysiological monitoring (IONM) is a monitoring procedure that applies electrophysiological techniques to detect the functional status of the nervous system during the operation.<sup>14</sup> The application of IONM correlates surgical intervention with neurophysiological changes simultaneously (real-time), avoiding the possibility of trauma and nerve damage and thus providing more optimal postoperative results. IONM includes several modalities, each specific for integrating certain neural pathways. Some of the modalities include electroencephalography (EEG), electroneuromyography (EMG), somatosensory evoked potentials (SSEP), brainstem auditory evoked potentials (BAEP), and motor evoked potentials (MEP).<sup>15</sup>

Clinically, IONM modalities can be applied individually in surgical interventions, a technique known as unimodal IONM. Each modality has drawbacks that limit its overall sensitivity and specificity when applied as unimodal IONM.<sup>16</sup> The combination of several IONM (multimodal) modalities has been shown to increase the effectiveness of monitoring neurological function while decreasing the rate of negative findings compared to unimodal. Therefore, multimodal IONM (MIONM) has the potential to compensate for the limitations arising from the unimodal application. Thus MIONM has been established as standard practice in various spinal surgical.<sup>16,17</sup>

In its implementation, the IONM modality is evaluated based on considerations regarding the severity of the case or what kind of operative action will be carried out.<sup>18</sup> In the case of scoliosis, both unimodal and multimodal IONM facilitate the identification of the damage or deficit of nerve function throughout the surgical intervention. Somatosensory evoked potentials (SSEP) are a widely used modality that is the primary mode of intraoperative monitoring during scoliosis surgical procedures.<sup>19</sup> In addition, several studies have reported that applying IONM during surgical intervention for scoliosis has significantly improved neurological outcomes.

Nassef *et al.* (2021) published a case series involving 547 patients who underwent scoliosis surgery. This study revealed that IONM was associated with reducing the incidence of new neural deficits (NND) after correcting idiopathic scoliosis. This is indicated by the difference in the occurrence of neurological deficits in scoliosis patients. Neurological injuries occurred in 3.3% and 8.1% of patients that had surgery with and without IONM, respectively.<sup>9</sup> In line with this, George *et al.* (2019) reported a population study involving 32,305 scoliosis patients under the age of 18 who had spinal fusion surgery. Patients undergoing surgical intervention were diagnosed with adolescent idiopathic scoliosis, congenital scoliosis, and neuromuscular scoliosis. The publication shows a trend towards lower rates of neurologic complications in IONM surgery, where as many as 0.9% of patients with IONM had neurological deficits and 1.4% of patients without IONM had neurological deficits.

**Table 1.** Comparison of Scoliosis Surgery Cases with and without Intraoperative Neurophysiological Monitoring

Author/Year/ Methods/ Sample Resource	Number of Patient			IONM Modality	Neurological Deficit	
	With IONM	Without IONM	Total		With IONM	Without IONM
Nassef <i>et al</i> <sup>9</sup> /2021/ retrospective/ Children's Hospital (Hamilton, Ontario) McMaster	359	186	547	SSEP; MEP	12 (3.3%)	15 (8.1%)
George <i>et al</i> <sup>10</sup> /2019/study population/National Inpatient Sampel (NIS)	5,706	26,599	32,305	NI	52 (0.9%)	368 (1.4%)
Ajiboye <i>et al</i> <sup>11</sup> /2017/ retrospective/PearlDiver Database	1,361	2,257	3,618	SSEP; MEP; EMG	24 (1.8%)	46 (2.0%)

IONM : Intraoperative Neurophysiological Monitoring, SSEP : Somatosensory Evoked Potential, MEP : Motor-Evoked Potential, EMG : Electromyography, NI: Not Informed

**Table 2.** Sensitivity and Specificity of Various Intraoperative Neurophysiological Monitoring Techniques

Author/ Year	Total Patient	Neurological Deficit	IONM Modality	Sensitivity	Spesificity	
Bhagat <i>et al</i> <sup>12</sup> /2015	320	5	Unimodal	SSEP	56.5 %	99.7 %
				MEP	95.5 %	99.3 %
			Multimodal	SSEP + MEP	100%	99.3 %
Kundnani <i>et al</i> <sup>13</sup> /2010	354	2	Unimodal	SSEP	51%	100%
				NMEP	100%	96%
			Multimodal	SSEP + NMEP	100%	99%

SSEP : Somatosensory Evoked Potential, NMEP: Neurogenic motor-evoked potential, MEP : Motor-Evoked Potential

Moreover, IONM was significantly associated with increased home discharge in postoperative patients.<sup>10</sup> Furthermore, Ajiboye et al. (2017) reported cases covering 3618 patients with surgical intervention for scoliosis. The most commonly used IONM modality in this publication is multimodal IONM, a combination of SSEP and EMG, while the least used modality is unimodal, namely MEP. According to the report, neurologic injury occurred in 1.8% of patients undergoing surgery with IONM and 2.0% in patients without IONM.<sup>11</sup>

The data presented above provide a whole picture of the difference in the incidence of neurological deficits between patients undergoing surgical interventional scoliosis procedures with and without IONM. All of these studies reported that patients with IONM had lower rates of neurologic impairment than patients without IONM. It occurred due to IONM's application of various physiological principles, each with a specific implementation that aims to improve patient outcomes.<sup>20</sup> When the benefits of intraoperative neurophysiological monitoring are demonstrated to be appropriate, neuromonitoring techniques should be further developed and established as a standard medical practice.

In clinical practice, IONM has not been fully integrated into all scoliosis corrective procedures.<sup>9-11</sup> The high cost is one factor that has become controversial in implementing IONM. Another study also reported several cases of unimodal IONM, which showed false positive and false negative results in detecting neurological damage. These limitations ultimately impact variations in the sensitivity and specificity of IONM, so its effectiveness is often still debated.<sup>21</sup> Several studies argue about the magnitude of sensitivity and specificity of each modality applied during scoliosis surgery. Bhagat et al. reported the results of a study involving 320 (female = 251; male = 69) patients who underwent a total of 354 bone deformity surgeries. The overall incidence of permanent neurologic deficits was 1.6% (5 of 320 patients), and the condition for significant alerts in the study was 7.1% (25 alerts of 354 operative episodes). Significant alerts occur

when there is a change in waves with specific criteria during monitoring. In such circumstances, the operation monitoring team will conduct a series of examinations, such as correlating changes in the level of the operated spine, blood pressure, anaesthetic level, temperature, and monitoring leads. In response to the significant alert, surgeons must intervene as soon as possible to prevent neurological damage. In the study, SSEP monitoring was applied to 352 surgical procedures, where 13 true positives, 10 false negatives, 1 false positive, and 328 true negative conditions were found from all monitoring activities, resulting in a sensitivity of 56.5% and specificity of 99.7%.

The study, on the other hand, used MEP monitoring on 316 patients and discovered 21 true positives, 1 false negative, 2 false positives, and 292 true negative conditions from all monitoring activities. Thus, the MEP sensitivity and specificity were 95.5% and 99.3%, respectively. The specificity of SSEP (99.7%) was higher than MEP (99.3%); however, the sensitivity of MEP (95.5%) was much better than SSEP (56.5%). When the two modalities are combined, the sensitivity increases to 100%, while the specificity reaches 99.3%.<sup>12</sup> The study group of Kundnani et al. involved 354 (female = 309; male = 45) patients who underwent spinal surgery. The study reported that thirteen cases showed a significant alert condition. All thirteen cases were detected on monitoring using the NMEP modality, whereas, in the use of SSEP, significant alerts were only detected in 8 cases. Meanwhile, two patients showed significant alert with SSEP + NMEP monitoring and had new neurological deficits (0.56%). Monitoring with SSEP revealed no false positive conditions, indicating a high specificity value. Nonetheless, it was found that 5 patients experienced false negative conditions (38%), resulting in reduced SSEP sensitivity. In contrast to NMEP monitoring, it was reported that there were no false negative cases but 2 false positive cases (15%). The specificity of SSEP (100%) was higher than NMEP (96%); however, the sensitivity of NMEP (100%) was much better than SSEP (51%). Nevertheless, the application of the SSEP + NMEP modality

combination showed better sensitivity (100%) and specificity (99%) compared to unimodality.<sup>13</sup>

Although the sensitivity of unimodal IONM was low, the specificity remained in a relatively high range of magnitudes. Each IONM modality has a different and specific working system. The SSEP monitors the dorsal column-medial lemniscal pathway, which mediates tactile, vibrational, and proprioceptive discrimination. In addition, MEP monitors motor pathways, whereby transcranial electrical stimulation elicits excitation of corticospinal projections at various levels.<sup>18</sup> Meanwhile, NMEP can be stimulated by transcranial electrical impulses from the motor cortex, which results in direct depolarization of pyramidal tract neurons and subsequent spinal tract conduction. This results in the use of NMEP to provide information on monitoring the combination of motor and sensory functions of the spinal tract<sup>22</sup>, since NMEP basically represents a monitoring of both motor and somatosensory tracts.

The studies depict the overall IONM modality, which provides high sensitivity and specificity when used in conjunction with multimodal IONM. It arises as a result of multimodal IONM mediating different neural pathways in other vascular areas, so monitoring both can provide a more comprehensive assessment of spinal function.<sup>13</sup> Furthermore, it should be emphasized that the use of IONM necessitates multidisciplinary collaboration involving the deliberation and monitoring of surgeons, anesthesiologists, and neurologists. With the aim that the resulting assessment can describe the patient's holistic condition so that false negative and false positive cases can be prevented<sup>15</sup>.

This study has some limitations. First, we include retrospective studies with the potential of inaccurate or incomplete data (information bias). We aimed to reduce this by meticulously designing the study to ensure proper data extraction and analysis. Second, this review does not include critical clinical information such as operative time, disease severity, surgical complexity, intraoperative events, the number of false positives and negatives, and information on the type and severity of neurological complications. Although these are genuine issues, the lack of evidence and evidence-based reports in contemporary literature cannot be overlooked.

Future research could, for instance, scrutinize the correlation between disease severity and surgical complexity, influencing the sensitivity and specificity of IONM in scoliosis surgery.

## Conclusion

Early detection through intraoperative neurophysiological monitoring (IONM) has been shown to contribute to identifying risk signs of neurologic deficits and postoperative scoliosis sequelae. With its high sensitivity and specificity, multimodal IONM provides an objective benchmark that surgeons can implement to review surgical strategies to reduce the risk of permanent neurologic deficits. Multimodal IONM can be considered the gold standard application of IONM in scoliosis surgery to prevent neurological damage and provide more satisfactory result of surgical intervention.

## Acknowledgement

None.

## Conflict of Interest

None.

## References

1. Popko J, Kwiatkowski M, Galczyk M. Scoliosis: Review of diagnosis and treatment. *Polish J Appl Sci*; 2018. 4(1):31–5. DOI: 10.19260/PJAS.2018.4.1.06
2. Rosenberg JJ. Scoliosis. *Pediatr Rev*; 2011. Sep;32(9):397–8; discussion 398. DOI: 10.1542/pir.32-9-397
3. Horne JP, Flannery R, Usman S. Adolescent idiopathic scoliosis: Diagnosis and management. *Am Fam Physician*; 2014. 89(3):193–8. Available from: <https://pubmed.ncbi.nlm.nih.gov/24506121/>
4. Chen L, Sun Z, He J, Xu Y, Li Z, Zou Q, et al. Effectiveness and safety of surgical interventions for treating adolescent idiopathic scoliosis: A bayesian meta-analysis. *BMC Musculoskelet Disord*; 2020. 21(1):1–15. Available from: <https://bmcmusculoskeletdisord.biomedcentral.com/articles/10.1186/s12891-020-03233-1>
5. Yu T, Li QJ, Zhang XW, Wang Y, Jiang QY, Zhu XJ, et al. Multimodal intraoperative monitoring during surgical correction of scoliosis to avoid neurologic damage. *Med (United States)*; 2019. 98(15):1–7. DOI: 10.1097/MD.00000000000015067
6. Thirumala PD, Cheng HL, Loke YK, Kojo Hamilton D, Balzer J, Crammond DJ. Diagnostic accuracy of somatosensory evoked potential monitoring during scoliosis fusion. *J Clin Neurosci*; 2016. 30:8–14. DOI: 10.1016/j.jocn.2016.01.017
7. Potentials S. Intraoperative neurophysiologic monitoring corporate medical policy. BlueCross BlueShield of North Carolina; 2019. 1–9. Available from: [https://www.bluecrossnc.com/sites/default/files/document/attachment/services/public/pdfs/medicalpolicy/intraoperative\\_neurophysiologic\\_monitoring.pdf](https://www.bluecrossnc.com/sites/default/files/document/attachment/services/public/pdfs/medicalpolicy/intraoperative_neurophysiologic_monitoring.pdf)
8. Thirumala PD, Bodily L, Tint D, Ward WT, Deeney VF, Crammond DJ, et al. Somatosensory-evoked potential monitoring during instrumented scoliosis corrective procedures: Validity revisited. *Spine J*; 2014. 14(8):1572–80. DOI: 10.1016/j.spinee.2013.09.035
9. Nassef M, Splinter W, Lidster N, Al-Kalbani A, Nashed A, Ilton S, et al. Intraoperative neurophysiologic monitoring in idiopathic scoliosis surgery: A retrospective observational study of new neurologic deficits. *Can J Anesth*; 2021. 68(4):477–84. DOI: 10.1007/s12630-020-01898-9
10. George J, Das S, Egger AC, Chambers RC, Kuivila TE, Goodwin RC. Influence of intraoperative neuromonitoring on the outcomes of surgeries for pediatric scoliosis in the United States. *Spine Deform*; 2019. 7(1):27–32. DOI: 10.1016/j.jspd.2018.05.013
11. Ajiboye RM, Park HY, Cohen JR, Vellios EE, Lord EL, Ashana AO, et al. Demographic trends in the use of intraoperative neuromonitoring for scoliosis surgery in

- the United States. *Int J Spine Surg*; 2017. 11(5):271–7. DOI: 10.14444/4033
12. Bhagat S, Durst A, Grover H, Blake J, Lutchman L, Rai AS, et al. An evaluation of multimodal spinal cord monitoring in scoliosis surgery: A single centre experience of 354 operations. *Eur Spine J*; 2015. 24(7):1399–407. DOI: 10.1007/s00586-015-3766-8
  13. Kundnani V, Zhu L, Tak H, Wong H. Multimodal intraoperative neuromonitoring in corrective surgery for adolescent idiopathic scoliosis: Evaluation of 354 consecutive cases. *Indian J Orthop*; 2010. 44(1):64–72. DOI: 10.4103/0019-5413.58608
  14. *Intraoperative Neurophysiological*; 2007. p. 33–41.
  15. Nunes RR, Bersot CDA, Garritano JG. Intraoperative neurophysiological monitoring in neuroanesthesia. *Curr Opin Anaesthesiol*; 2018. 31(5):532–8. DOI: 10.1097/ACO.0000000000000645
  16. Lall RR, Hauptman JS, Munoz C, Cybulski GR, Koski T, Ganju A, et al. Intraoperative neurophysiological monitoring in spine surgery: Indications, efficacy, and role of the preoperative checklist. *Neurosurg Focus*; 2012. 33(5):1–10. DOI: 10.3171/2012.9.FOCUS12235
  17. Sutter M, Eggspuehler A, Jeszenszky D, Kleinstueck F, Fekete TF, Haschtmann D, et al. The impact and value of uni- and multimodal intraoperative neurophysiological monitoring (IONM) on neurological complications during spine surgery: A prospective study of 2728 patients. *Eur Spine J*; 2019. 28(3):599–610. DOI: 10.1007/s00586-018-5861-0
  18. Ghatol D, Widrich J. *Intraoperative Neurophysiological Monitoring* [Internet]. Treasure Island: StatPearls Publishing; 2022. Available from: <https://www.ncbi.nlm.nih.gov/books/NBK563203/?report=classic>
  19. Glover CD, Carling NP. Neuromonitoring for Scoliosis Surgery. *Anesthesiol Clin*; 2014. 32(1):101–14. DOI: 10.1016/j.anclin.2013.10.001
  20. Kim SM, Kim SH, Seo DW, Lee KW. Intraoperative neurophysiologic monitoring: Basic principles and recent update. *J Korean Med Sci*; 2013. 28(9):1261–9. DOI: 10.3346/jkms.2013.28.9.1261
  21. Charalampidis A, Jiang F, Wilson JRF, Badhiwala JH, Brodke DS, Fehlings MG. The use of intraoperative neurophysiological monitoring in spine surgery. *Glob Spine J*; 2020. 10(1\_suppl):104S–114S. DOI: 10.1177/2192568219859314
  22. Park J-H. Intraoperative neurophysiological monitoring in spinal surgery. *World J Clin Cases*; 2015. 3(9):765. DOI: 10.12998/wjcc.v3.i9.765