

ScienceDirect Journals & Books

Journal of Traditional and Complementary Medicine

Open access

7.8 CiteScore | 4.221 Impact Factor

Articles & Issues | About | Publish | Search in this journal | Submit your article | Guide for authors

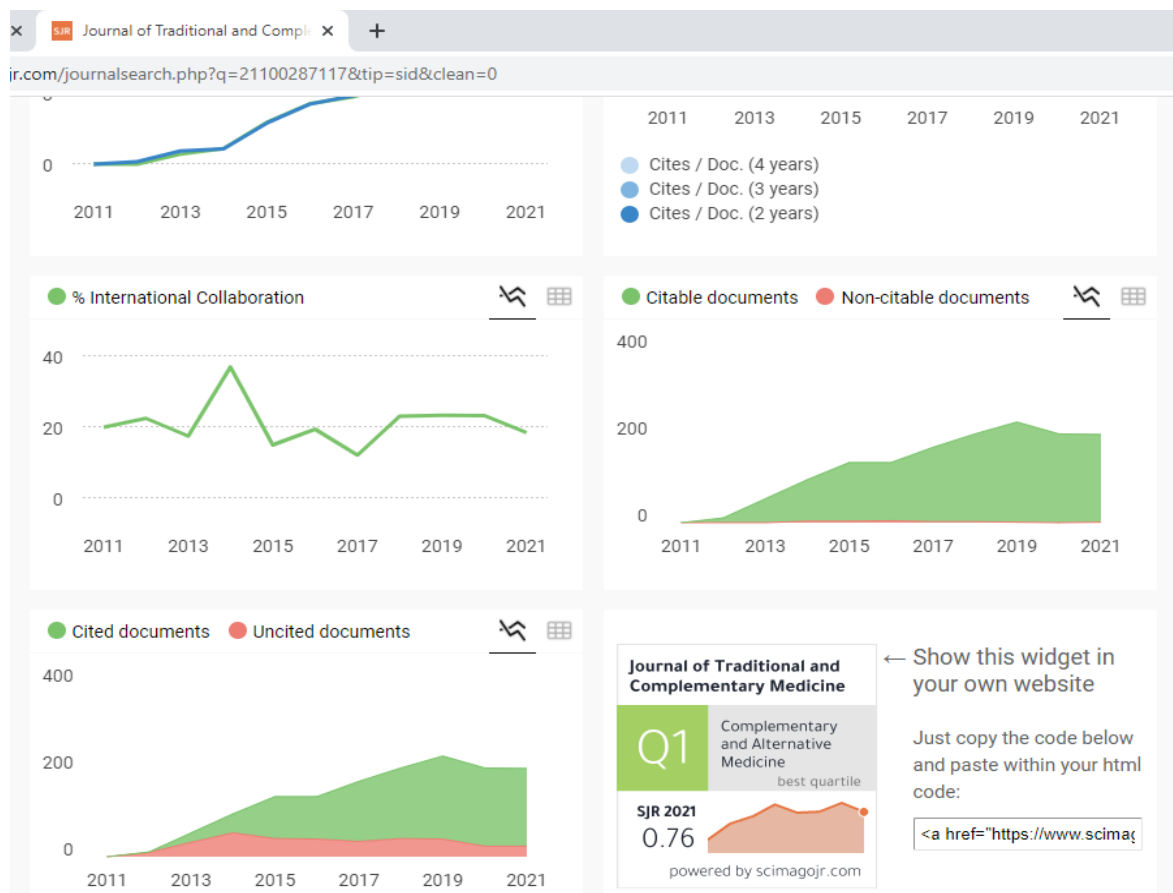
Latest issue: **Volume 13, Issue 2** (March 2023)

About the journal: FOR AUTHORS: Before you submit, please carefully read the AIMS and REASONS FOR PROMPT REJECTION. AIMS: eJTCM is committed to publish research providing the biological and clinical grounds for using Traditional and

Alamat jurnal: <https://www.sciencedirect.com/journal/journal-of-traditional-and-complementary-medicine>

Laman daftar isi: <https://www.sciencedirect.com/journal/journal-of-traditional-and-complementary-medicine/vol/12/issue/4>

Link scimago: <https://www.scimagojr.com/journalsearch.php?q=21100287117&tip=sid&clean=0>





Contents lists available at ScienceDirect

Journal of Traditional and Complementary Medicine

journal homepage: <http://www.elsevier.com/locate/jtcm>

Detam 1 black soybean against cisplatin-induced acute ren failure on rat model via antioxidant, antiinflammatory and antiapoptosis potential

Wahyu Widowati ^{a,*}, Sijani Prahastuti ^a, Meilinah Hidayat ^a, Stella Tinia Hasianna ^a, Roro Wahyudianingsih ^a, The Fransiska Eltania ^a, Alya Mardhotillah Azizah ^b, Jenifer Kiem Aviani ^b, Mawar Subangkit ^c, Rr Anisa Siwianti Handayani ^b, Hanna Sari Widya Kusuma ^b

^a Faculty of Medicine, Maranatha Christian University, Jl. Prof. Drg. Surya Sumantri 65, Bandung, 40164, West Java, Indonesia

^b Aretha Medika Utama, Biomolecular and Biomedical Research Center, Jl. Babakan Jeruk II No. 9, Bandung, 40163, West Java, Indonesia

^c Laboratory of Veterinary Pathology, Faculty of Veterinary Medicine, IPB University, Jl. Agathis No. 1, IPB University Darmaga Campus, Bogor, 16680, West Java, Indonesia

ARTICLE INFO

Article history:

Received 4 September 2020

Received in revised form

23 November 2021

Accepted 11 January 2022

Available online 13 January 2022

Keywords:

Blood urea nitrogen

Catalase

Fibronectin

Glycine max L. Merr.

Nephrotoxicity

ABSTRACT

Background and aim: Cis-Diamminedichloroplatinum (II) (Cisplatin) is one of the most synthetic anti-cancer drug but have several adverse effects and one of them is acute ren failure. Cisplatin can induce nephrotoxicity occur via the toxic generation of reactive oxygen species (ROS). Black soybean (*Glycine max* L. Merr.) has been reported contain high levels of phenolics and anthocyanins that has antioxidant activity. This study aims to determine the effect of ethanol extract of black soybean (EEBS) against cisplatin-induced nephrotoxicity in rats.

Experimental procedure: Cisplatin-induced nephrotoxicity rats treated with EEBS and the blood samples taken on days 0, 9, and 18. The effects of EEBS was evaluated by determining Interferon- γ (IFN- γ), Caspase-3 (Casp-3), and Interleukin-1 β (IL-1 β) expression using immunohistochemistry (IHC), blood urea nitrogen (BUN), Uric Acid (UA) content and catalase (CAT) content in the blood plasma with colorimetric assay kit.

Results and conclusion: Based on the results, EEBS treatment had successfully reduced pro-inflammatory cytokines IL-1 β and IFN- γ , and improved physiological condition by lowering BUN and UA content while increasing CAT activity. No significant effect was found in Casp-3 expression. EEBS has potential to improve acute renal failure condition through inflammatory suppression and renal function improvement.

© 2022 Center for Food and Biomolecules, National Taiwan University. Production and hosting by Elsevier Taiwan LLC. This is an open access article under the CC BY-NC-ND license (<http://creativecommons.org/licenses/by-nc-nd/4.0/>).

1. Introduction

Many anticancer drugs have teratogenic and other serious effects on biological systems which prompting restricted usage.¹ Cis-

Diamminedichloroplatinum (II), typically known as cisplatin, is one of the most effective anti-neoplastic drugs currently available because of its high-therapeutic efficacy.^{1,2} However, several adverse effects of cisplatin have been reported, mainly neurotoxicity and nephrotoxicity. Long-term cisplatin nephrotoxic effects causes Acute Kidney Injury (AKI) which occurs in 20–30% of patients.³ As reported in previous studies, nephrotoxicity was most likely caused by generation of Reactive Oxygen Species (ROS) which causes molecular damage to the cells.^{4,5} Therefore, compounds with antioxidant activity will offer therapeutic effect to inhibit cisplatin side-effect.

* Corresponding author. Medical Research Center, Faculty of Medicine, Maranatha Christian University, Prof. Drg. Suria Sumantri 65, Bandung, 40164, West Java, Indonesia.

E-mail addresses: wahyu_w60@yahoo.com, wahyu.widowati@maranatha.edu (W. Widowati).

Peer review under responsibility of The Center for Food and Biomolecules, National Taiwan University.

List of abbreviations

ADP	Adenosine diphosphate	IL-1 β	Interleukin-1 β
AKI	Acute Kidney Injury	IL-18	Interleukin-18
AMP	Adenosine monophosphate	LPS	lipopolysaccharide
ATP	Adenosine triphosphate	MAPK	Mitogen-activated protein kinase
BUN	Blood urea nitrogen	MCP-1	monocyte chemoattractant protein-1
Casp-1	Caspase -1	NF- κ B	Nuclear factor-kappa B
Casp-3	Caspase -3	NLRP-3	NLR family pyrin domain containing-3
Casp-8	Caspase -8	OCT-2	Organic cation transporter-2
CAT	Catalase	PGE-2	Prostaglandin-2
CTR-1	Copper transporter-1	ROS	Reactive oxygen spesies
EEBS	Ethanol extract of black soybean	SD	Sprague-Dawley
GFR	Glomerular filtration rate	SOD	Superoxide dismutase
GSH	Glutathione	TGF- β 1	Transforming Growth Factor- β 1
HK-2	human kidney cell	TLR-4	Toll Like Receptor-4
IFN- γ	Interferon- γ	TNF- α	Tumor Necrosis Factor- α
IHC	Immunohistochemistry	TNFR	TNF-receptor
		UA	Uric acid

AKI is an abrupt decrease in kidney function caused by damage in renal parenchyma or reduction in renal perfusion. Cisplatin has been known to cause kidney damage, mainly through ROS generation. Several antioxidant enzymes in the kidney play a role in protecting against nephrotoxicity. Among the antioxidant enzymes, hydrogen peroxide (H₂O₂) is considered the most effective target molecule to reduce ROS toxicity. However, cisplatin has been known also to block the innate antioxidant enzymes activity, including catalase (CAT).⁶ Cisplatin nephrotoxicity is also highly related to kidney proximal tubule uptake of cisplatin at higher concentrations compared to other tissues. Cisplatin-induced ROS causes activation innate Tumor Necrosis Factor- α (TNF- α) which activates caspase-3 (Casp-3) that leads to apoptosis. TNF- α also activates other inflammatory related cytokines including Interleukin-1 β (IL-1 β) and Interferon- γ (IFN- γ).⁵ AKI causes decrease in renal perfusion which leads to reduction of glomerular filtration rate (GFR). Blood uric acid and urea nitrogen often used as indicator of AKI that these two substances are regularly excreted through urine.^{7,8}

Black soybean (*Glycine max* L. Merr.) has long been consumed in Indonesia as one of Indonesia's traditional food, the soybean sauce.⁹ Black soybean contains plenty of protein, isoflavone, and vitamins.¹⁰ Black soybean has also been reported to contain high levels of anthocyanins in the seed coat and also has polysaccharides which has ability for preventing such oxidation-related diseases,^{9,11} antioxidant activity,^{12,13} and antiinflammatory potential.¹⁴ Therefore, black soybean is a potential candidate to reduce cisplatin side-effect. Besides that, black soybean has arabinogalactan compound that has antioxidant activity and also has hepatoprotective effect through reduction of serum alanine aminotransferase (ALT), alkaline phosphatase (ALP), aspartate aminotransferase (AST), increase activity superoxide dismutase (SOD) and CAT.¹⁵

The novelty of this research rest in the usage of ethanol extract of black soybeans (EEBS) to improve nephrotic kidney condition and acute renal failure condition through inflammaory suppression by lowering proinflammatory cytokines, blood urea nitrogen (BUN), and uric acid (UA) level, while increasing the activity of CAT and improving physiological condition. This study aims to determine the effect of ethanol extract of black soybean (EEBS) against cisplatin-induced nephrotoxicity in rats by measuring BUN, UA content and CAT activity in the blood plasma and immunohistochemistry (IHC) of kidney for IFN- γ , Casp-3, IL-1 β expression.

2. Materials and methods

2.1. Extract preparation

Detam variety of black soybeans (*Glycine max* L. Merr.) was collected from Unit Pengelolaan Benih Sumber (UPBS) Balai Penelitian Tanaman Aneka Kacang dan Umbi, Malang, East Java, Indonesia. The plants were identified by herbarium staff, Department of Biology, School of Life Science and Technology, Bandung Institute of Technology, Bandung, West Java, Indonesia. Black soybean seed was kept in drier tunnel service and chopped. The extraction of *detam* black soybeans was performed based on maceration method using distilled ethanol 70% as the solvent. The filtrate was evaporated using a rotary evaporator (Zhengzhou Well-known, RE-201D) until a paste extract. The ethanolic extract of black soybeans (EEBS) stored at -20 °C.^{12,14,16} The extract were then analyzed by liquid chromatography and liquid chromatography mass spectrometry (LC-MS/MS) profiling for identifying the qualitative bioactive compound composition¹⁷ using isoflavone as standard and methanol as solvent. Analysis using Hypersil Gold column (150 mm \times 2.1 mm \times 1.9 mm). The sample injected 1 μ L to the column. The mobile phase was 0.1% formic acid with the flow rate 350 μ L/min. MS/MS Triple Q (quadrupole) mass spectrophotometer TSQ Quantum Access with Electrospray Ionization (ESI) be used and controlled by software TSQ Tune operated with positive polarity with condition such as voltage 3 kV; evaporation temperature 275 °C; capillary temperature 300 °C; nitrogen 40 psi; and Aux 10 psi with argon gas.

2.2. Acute renal disease rat model

Male Sprague-Dawley (SD) rats (6 weeks old, 160–180 g BW) were obtained from the National Agency of Drugs and Food Control (Jakarta, Indonesia). The research has been approved by the Research Ethic Committee from Faculty of Medicine, Maranatha Christian University and Immanuel Hospital, Bandung, Indonesia (No.138/KEP/IV/2019). The rats were housed in plastic-bottom wire-upper cages and acclimated for 1 week under laboratory conditions (25–27 °C, humidity 60%, 12-h light/dark cycle). The acute renal disease rat model were randomly divided into four different groups containing five rats each group. Group I (negative control) rats treated with 0.5 mL distilled water once every day.

Group II (positive control) containing cisplatin-induced rats, while group III and IV were positive control given EEBS at the dose of 300 and 600 mg/kg BW. Rats were kept in single system cages, each cage contain 1 rat. Rats were fed with basal diet (water content 12%, crude protein 15%, crude fat 3–7%, crude fiber 6%, Ca 0.9–1.1%, P 0.6–0.9%, energy 4400 kkal). Rats were induced with cisplatin 8 mg/kg BW intraperitoneally for three days before EEBS treatment except the negative control group. On the fourth day, cisplatin induction was stopped and EEBS treatment was started for 18 days by giving orally 300 and 600 mg/kg BW, except for negative and positive control group for 18 days. Bloods were collected from the orbital veins at day 0, 9, and 18 during treatment for BUN, UA, and CAT level analysis. At day 18, rats were anesthetized using ketamine HCl (Ikapharmindo Putramas) 100 mg/kg BW, xyla (Interchemie, 361453) 15 mg/kg BW intraperitoneal and rats were terminated, the kidneys were collected. Kidneys were weighted on Analytical Balance (AXIS, ACN/G) and prepared for IHC assay.^{1,2}

2.3. Immunohistochemistry assay of kidney IFN- γ , Casp-3, IL-1 β expression

Kidneys were embedded in paraffin and fixed with formalin. Deparaffinization was done by placing the slides in 56 °C oven for 15 min and bathing in xylene. Later serial rehydration was done by placing the slides in absolute ethanol, 90% ethanol, 70% ethanol and final washing with water. Slides were place in PBS bath for further rehydration for 30 min. Antigen retrieval were done in citrate buffer pH 6.0 (Abcam, ab208572) in 121 °C for 10 min. Endogenous peroxidase were blocked with 3% H₂O₂ (Merck, 107209) in methanol (Merck, 106009) for 15 min at room temperature. Samples were then pre-incubated with 5% Bovine Serum Albumin for 10 min prior to primary antibody reaction. The primary antibody reaction using rabbit-anti rat IFN- γ (Elabsci, E-AB-R0009), rabbit-anti rat Casp-3 (ElabScience, E-AB-63602), and rabbit-anti rat IL-1 β (Elabsci, E-AB-70048) were done overnight in room temperature. The protein target were visualized with rabbit specific HRP/DAB (ABC) detection IHC kit (Abcam, ab64261). Haematoxyline was used for counterstain. The stained tissue were observed in primostar (Zeiss) microscope and lumenera infinity 1-3c was used for photography. The IHC result ware compare qualitatively based on number positive cells and intensity of expressions. The quantification method using ImageJ software to assess indices of positive on immunohistochemical slides.^{18,19}

2.4. Blood urea nitrogen assay

The BUN level was measured using Blood Urea Nitrogen (BUN) Assay Kit (Elabscience, E-BC-K183). The reaction absorbance was read at 580 nm according to the manufacturer's protocol using the micro-plate reader (Multiskan™ GO Micro plate Spectrophotometer, Thermo Scientific).²⁰

2.5. Uric acid assay

UA level was measured using Uric Acid (UA) Assay Kit (Elabscience, E-BC-K016). The absorbance was then read at 690 nm using the microplate reader according to the manufacturer's protocol.²¹

2.6. Catalase assay

CAT activity was measured using Catalase (CAT) Assay Kit (Elabscience, E-BC-K031). The absorbance was read at 405 nm using the microplate reader according to the manufacturer's protocol.²²

2.7. Statistical analysis

The data was analyzed using IBM SPSS Statistics 20.0 version. One-way ANOVA with Tukey HSD post hoc test were used to show significance among treatments. P-value <0.05 was considered as significant.

3. Results and discussion

3.1. Secondary metabolite composition of extract

The results of the LC-MS/MS analysis can describe difference in the compound of the soybean extract. The content of these differences is illustrated by the peak chromatogram of compounds with different molecular weights. Based on the result of LC-MS/MS analysis in our study and compared to the standard (isoflavone), as shown in Figs. 1 and 2, daidzein has retention time at 2.58 min, daidzin at 1.21 min, genistin at 1.43 min, biochanin A at 1.22 min, while glycitein has retention time at 2.72 min. This result was indicated that soybean extract contained daidzein, daidzin, genistin, biochanin A, and glycitein. This results show the most well-known isoflavone in soybeans as shown in the previous study except biochanin A.²³ Biochanin A is also a part of isoflavones, but have small concentration in soybean so in the previous study biochanin A was not determined. The difference between our results and previous study can caused by the variation of external condition which is can reduce the isoflavone before detected.²⁴ Soybeans contain high amount of secondary metabolite especially their isoflavones, as shown in Fig. 1 so that isoflavone used as the standard in this study. The soybeans isoflavone have been shown to have many pharmacological effect such as antioxidant, anti-inflammatory, anticarcinogenic, and antiviral activity.²⁵ All the isoflavone determined in our study has an potential activity to reducing oxidative stress or inflammatory disease.^{12,14}

3.2. Effect of EEBS toward IFN- γ expression in acute renal disease rat model

Cisplatin is one of the most effective drugs used to treat a variety of cancer but has side effect that can cause nephrotoxicity. Based on our result, cisplatin induction caused inflammation as marked by significant elevation of IL-1 β and IFN- γ and cell apoptosis as marked by Casp-3 elevation. Moreover, cisplatin induction has resulted in slight renal hypertrophy. Cisplatin induction caused nephrotoxicity because of cisplatin high affinity copper transporter (CTR-1) and organic cation transporter (OCT-2) located at basolateral membrane of proximal tubule cells. There are several proposed mechanism how cisplatin caused nephrotoxicity. The well-known mechanism is through generation of ROS and binding to various cytoplasmic anti-oxidant including glutathione (GSH), superoxide dismutase (SOD) and CAT which shift the redox status within cells leading to ROS toxic level. Nephrotoxicity effects caused by cisplatin can occur via ROS generation. For protecting from this effect, compound with antioxidant activity have been studied and in our research was tested by EEBS. The seed coat of black soybeans has been known to contain high concentration of flavonoids especially proanthocyanidin and anthocyanin which possess high level of antioxidant activity.¹² Anthocyanins is a phenolic compound from flavonoid class which is soluble in polar solvents and highly deposited in flowers, fruits, and seed coats that gives red to black pigmentation. Black soybean seed and its compound daidzein, genistein have been studied to possess anti-inflammatory activity which reducing IL-1 β , TNF- α , prostaglandin 2 (PGE-2) by *in vitro* study toward inflammatory macrophage cells.¹⁴ The best studied mechanism is through its antiradical

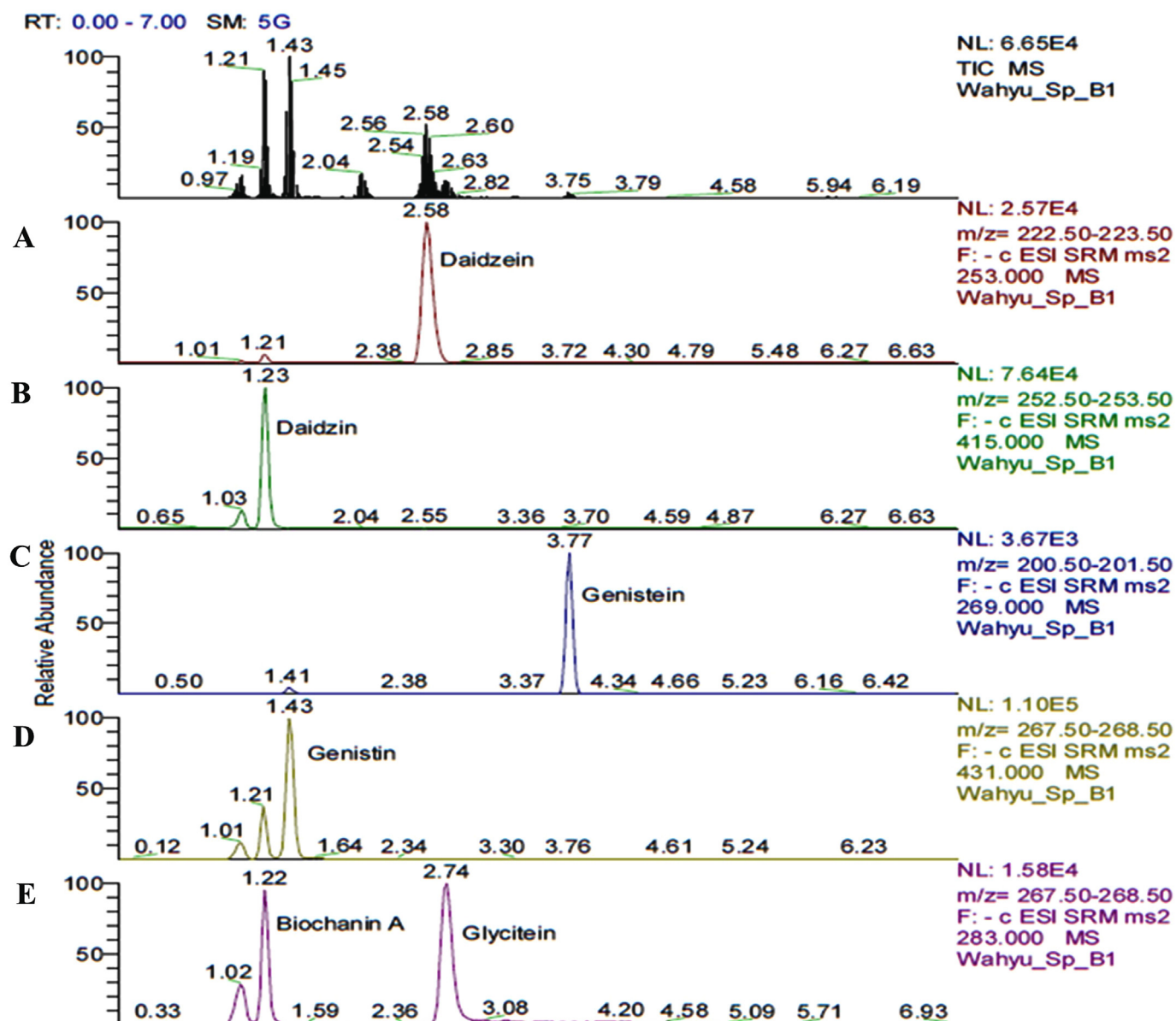


Fig. 1. Chromatogram of Isoflavones as a standard using LC-MS/MS method. (A. Daidzein (RT 2.58), B. Daidzin (RT 1.23), C. Genistein (RT 3.77), D. Genistin (1.43), E. Biochanin A (RT 1.22) and Glycitein (RT 2.72)).

activity.²⁶ Flavonoid or more specifically isoflavones including genistein, daidzein, and glycitein dose-dependently suppress NO might, attenuate excessive NO generation at inflammatory sites in LPS-induced macrophage cells.²⁷

The inflammation caused by cisplatin induction has been reported in several study as marked by increased in several cytokine such as IL-1 β , IL-1 α , IL-6, TNF- α .^{28,29} In our study, we also found that cisplatin induction trigger releasing pro-inflammatory cytokine IFN- γ as marked by significant elevation of the expression which is supported that higher expression of pro-inflammatory cytokine correlated with renal injury.³⁰ As shown in Fig. 3A and E, presents that the negative control (healthy rats) showed scattered and weak cytoplasmic staining of IFN- γ in renal tubules epithelium as shown by brown coloration inside the cytoplasm compared to the positive control group (cisplatin-induced rat) as shown in Fig. 3B and F, that has high expression of IFN- γ that showed by diffuse and strong cytoplasmic staining (see Fig. 3). The

IFN- γ expression of positive control significant difference compare to negative control ($p < 0.05$) as present in Fig. 4. The increasing IFN- γ expression has been demonstrated that it has an associated with the NACHT, LRR, and PYD domains-containing protein-3 (NLRP-3) downstream secretion of IL-18.³¹ To reduce the severity happened by inflammation, the expression of cytokine should be reduced with one of them is flavonoid specifically isoflavone compound found in black soybeans as mentioned in section 3.1. Several isoflavone has already shown a protective effect such as anti-inflammatory for acute renal injury and improved kidney function on in vivo model studies especially daidzein as mentioned in that ameliorated kidney injury.³² Genistein and daidzein have anti-inflammatory by inhibiting inflammatory marker TNF- α , IL-1 β in LPS-induced macrophage cells as inflammation cells model.³³ Based on our results, the treatment of EEBS caused a significant reduction in cytoplasmic IFN- γ expression dose dependently (Fig. 3C and G, D and H). This study showed that EEBS 600 mg/kg

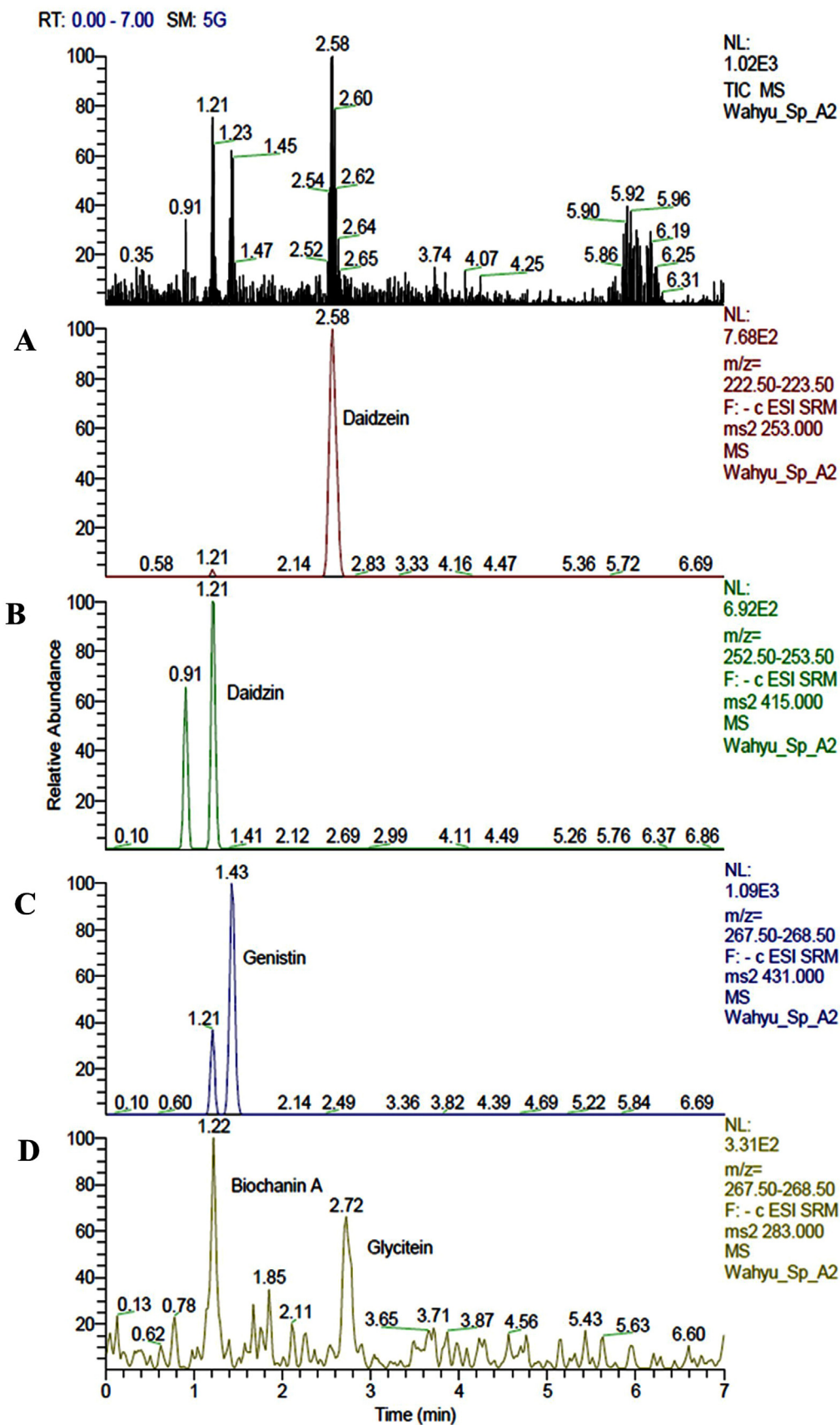


Fig. 2. Chromatogram of EEBS using LC-MS/MS method. EEBS contained A. Daidzein (RT 2.58), B. Daidzin (RT 1.21), C. Genistin (RT 1.43), D. Biochanin A (RT 1.22) and Glycitein (RT 2.72).

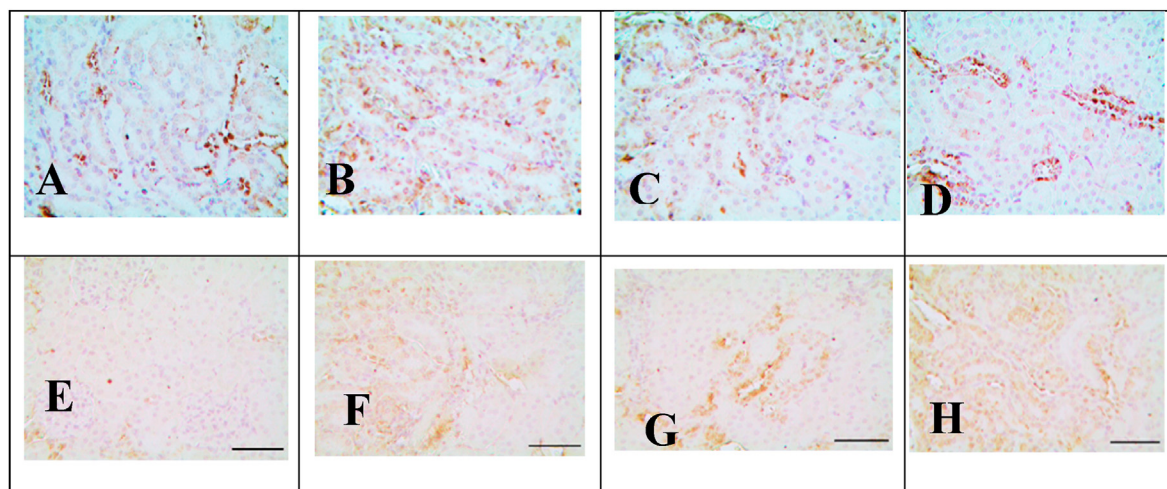


Fig. 3. Effect of EEBS towards IFN- γ expression in acute renal disease rat model. The slides are seen at 400 \times (A–D) and 1000 \times (E–H) magnification. *A and E are Negative Control (normal rat); B and F are Positive Control (acute renal disease); C and G are EEBS 300 (Positive Control + EEBS 300 mg/kg BW); D and H are EEBS 600 (Positive Control + EEBS 600 mg/kg BW).

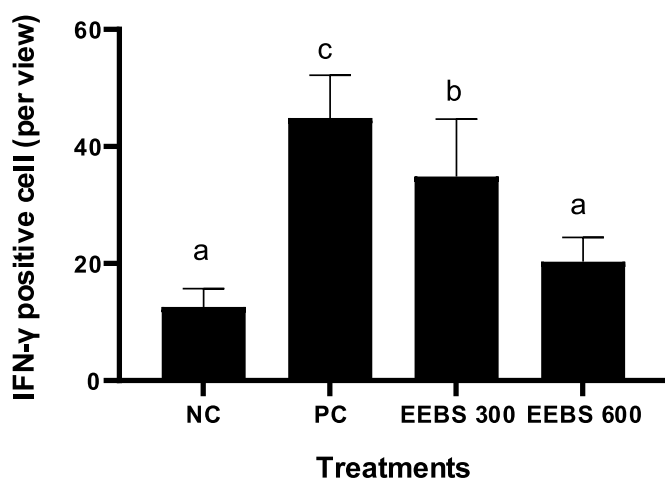


Fig. 4. Effect of EEBS toward IFN- γ expression in acute renal disease rat model. Data are presented as mean \pm SD. NC: negative control (normal rat + untreated EEBS); PC: positive control (Cisplatin-induced rat); EEBS 300: positive control + EEBS 300 mg/kg BW; EEBS 600: positive control + EEBS 600 mg/kg BW. Different letters (a,b,c) show significant difference of IFN- γ positive cell number among treatments based on Tukey HSD post hoc test ($p < 0.05$).

BW had significantly ($p < 0.05$) reduced inflammation as marked by reduced pro-inflammatory cytokines IFN- γ expression (Fig. 4).

3.3. Effect of EEBS toward Casp-3 expression in acute renal disease rat model

ROS generation within cells trigger Mitogen-Activated Protein Kinase (MAPK) activation which in turn trigger the intercellular production of TNF- α . TNF- α production activates extrinsic pathway of apoptosis, where it triggers the activation of Casp-8 and Casp-3.⁵ Casp-3 play an important role as an apoptotic marker where high apoptosis marked by high expression of Casp-3.³⁴ In our result, cisplatin induction caused cell apoptosis as marked by the significant elevation of Casp-3 compared to the negative control ($p < 0.05$) (Fig. 5B and 5F, Fig. 6). The negative control (healthy rats) showed scattered, weak cytoplasmic staining of Casp-3 in renal

tubules epithelium as shown by brown coloration inside the cells cytoplasm (Fig. 5A and 5E), while the positive control group (cisplatin-induced rats) showed diffuse, strong cytoplasmic staining as an indication of high expression of Casp-3 (Fig. 5B and 5F). EEBS treatment (EEBS 300, EEBS 600) reduced Casp-3 expression compared to positive control ($p < 0.05$) Fig. 6. This result was similar with the previous study that Casp-3 as an apoptotic marker will be down regulated their expression after flavonoid specifically daidzein as part of isoflavone treatments.³² Genistein decreased cisplatin-induced apoptosis by regulating P53 induction in kidney injury.³³

3.4. Effect of EEBS toward IL-1 β expression in acute renal disease rat model

Increased levels of inflammatory cytokines such as IL-1 β , TNF- α , and monocyte chemoattractant protein-1 (MCP-1) have become a focus of study in kidney injury.³⁵ In Fig. 7 showed the immunohistochemical protein expression of IL-1 β in renal cortex. The brown color has indicated the positive staining area of IL-1 β . Furthermore, IHC study revealed that cytoplasmic immunoreactivity of IL-1 β in the renal cortex was significantly increased compared to negative control group (Fig. 7). The treatment of EEBS in the highest dose (600 mg/kg BW) can decrease the IL-1 β production, this result indicate the lowest of IL-1 β protein expression (Fig. 7D and 7H, Fig. 8). Based on He (2019) research showed that soybean product significantly improved the histopathological damage in chronic kidney disease mice model. The soybean treatments decreased the serum levels of kidney toxicity and inflammatory biomarkers such as IL-6, IL-1 β , Transforming Growth Factor- β 1 (TGF- β 1), Toll Like Receptor-4 (TLR-4), F4/80 and TNF- α in kidney samples.³⁶

3.5. Effect of EEBS toward blood urea nitrogen, uric acid in acute renal disease rat model

Edema in the kidney caused by inflammation will cause increasing in intratubular pressure, hypoxia, and decrease the GFR. The decrease in GFR causes elevation of BUN which is excreted through urine. Moreover, the renal proximal tubules cells have high energy demand (ATP) as they reabsorb nearly 80 meq Na/g kidney/

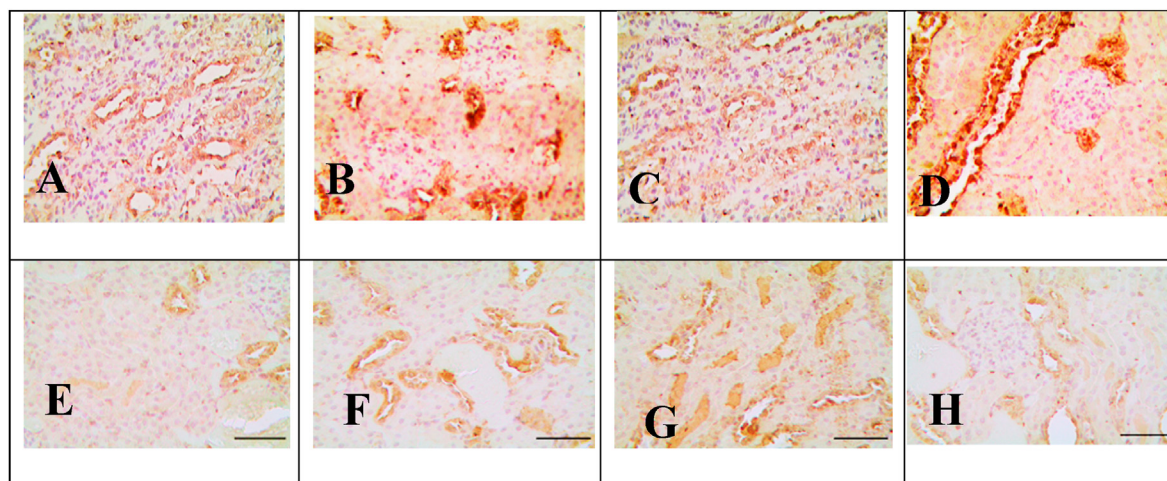


Fig. 5. Effect EEBS towards Casp-3 expression in acute renal disease rat model The slides is seen at 400× (A–D) and 1000× (E–H) magnification. *A and E are Negative Control (normal rat); B and F are Positive Control (acute renal disease); C and G are EEBS 300 (Positive Control + EEBS 300 mg/kg BW); D and H are EEBS 600 (Positive Control + EEBS 600 mg/kg BW).

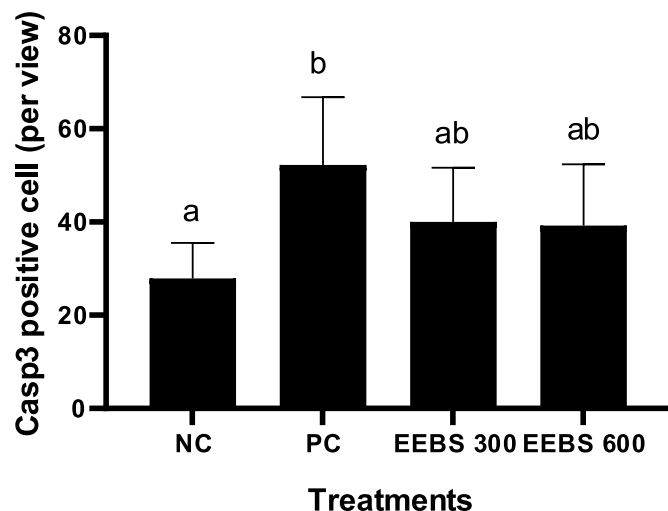


Fig. 6. Effect EEBS towards Casp-3 expression in acute renal disease rat model Data are presented as mean \pm SD. NC: negative control (normal rat + untreated EEBS); PC: positive control (Cisplatin-induced rat); EEBS 300: positive control + EEBS 300 mg/kg BW; EEBS 600: positive control + EEBS 600 mg/kg BW. Different letters (a,ab,b) show significant difference of Casp-3 expression among treatments based on Tukey HSD post hoc test ($p < 0.05$).

day. Hypoxic condition causes drop in renal ATP concentrations and increase in ADP and AMP formation. The activity of 5' nucleotidase with AMP forms adenosine, inosine and hypoxanthine. Hypoxanthine is converted by xanthine oxidase to UA.³⁷ Our result shows significant increase in BUN and UA level in nephrotic rat models ($p < 0.05$). Increasing level of BUN and UA has an associated with the renal injury or any disease in kidney. Therefore, reducing both level will be ameliorate the kidney's function.^{39,40} In our study, EEBS treatment had improved physiological condition as marked by lower BUN and UA level. The BUN and UA level lowered significantly compared to positive control ($p < 0.05$). However, 300 mg/kg BW was not enough to lower BUN and UA to normal level. The level of BUN and UA with EEBS 600 g/kg BW were comparable to negative control (Figs. 9 and 10). This treatment showed a potential effect from EEBS to reduce the progression of kidney disease in cisplatin-induced rat models. This results was similar with previous

study that the urea content was decreased significantly in cisplatin-induced rats by using *Hibiscus sabdariffa* treatment that contain high level of anthocyanins.⁴¹

A significant correlation has been found between renal proinflammatory cytokines and level of BUN and UA.^{42,43} Isoflavonoid in EEBS improves reverse glomerular functions in cisplatin-administered rats.⁴⁴ Moreover, the considerable reduction in BUN and UA in cisplatin-administered rats due to EEBS treatment improved renal tubular function.⁴⁴

3.6. Effect of EEBS toward catalase level in acute renal disease rat model

Increasing ROS in our models indicate of kidney injury (see Fig. 8). To regulate the level of ROS especially in kidney injury, there are many antioxidants system that has been described in many studies. One of the mostly used is SOD which will form oxygen (O_2) and hydrogen peroxide (H_2O_2) from dismutation of superoxide ($O_2^{\cdot-}$), and H_2O_2 converted by CAT into molecular O_2 and H_2O .⁴⁵ CAT is free radical scavengers or electron donors that can react with free radicals to form harmless product which is it would converting H_2O_2 into molecular O_2 and H_2O .^{46,47} Therefore, cisplatin-induced rat inhibits the renal activities of CAT which indicated by decrement of CAT activity.⁴⁸ Our result shows that cisplatin-induced rats shows significantly decrease plasma CAT level ($p < 0.05$) Fig. 11. Cisplatin also directly bind to cytochrome P450 in mitochondria which leads to mitochondrial ROS generation.⁵ In our study, EEBS treatment had improved physiological condition as marked by higher CAT content. After the EEBS treatment, CAT level elevated significantly compared to positive control ($p < 0.05$). EEBS was able to increase CAT level in nephrotoxic rat (Fig. 11). This results was validated with previous study that CAT activity increased in cisplatin-induced nephrotoxic mice when using antioxidant vitamins C and E treatments 500 mg/kg.²

The flavonoid content of soybean extract has been known exhibited nephroprotective activity due to preventing oxidative damage in renal tubular mediate by iron (Fe) and also blocking of P38 MAPK activation mechanisms.^{49,50} These findings reveal that Adenosine Monophosphate cyclic (AMPC) protects renal tubular cells from cisplatin-induced oxidative stress by obliterating ROS and reducing the generation of proinflammatory cytokines through

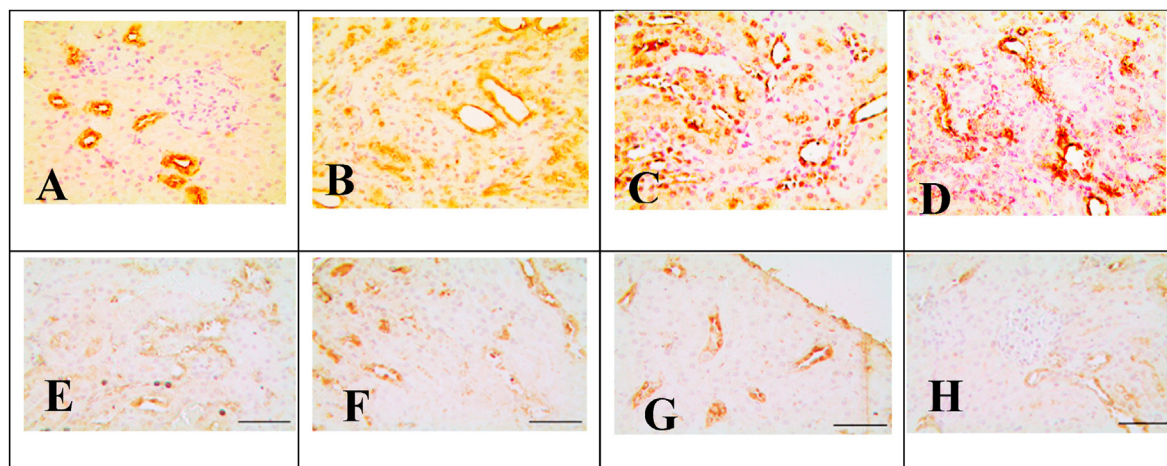


Fig. 7. Effect of EEBS towards IL-1 β expression in acute renal disease rat model. The slides are seen at 400 \times (A–D) and 1000 \times (E–H) magnification. *A and E are Negative Control (normal rat); B and F are Positive Control (acute renal disease); C and G are EEBS 300 (Positive Control + EEBS 300 mg/kg BW); D and H are EEBS 600 (Positive Control + EEBS 600 mg/kg BW).

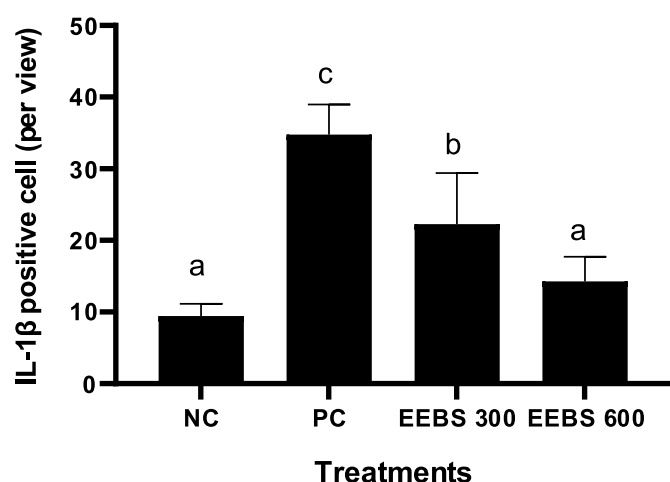


Fig. 8. Effect of EEBS towards IL-1 β expression in acute renal disease rat model. Data are presented as mean \pm SD. NC: negative control (normal rat + untreated EEBS); PC: positive control (Cisplatin-induced rat); EEBS 300: positive control + EEBS 300 mg/kg BW; EEBS 600: positive control + EEBS 600 mg/kg BW. Different letters (a, b, c) show significant difference of IL-1 β expression among treatments based on Tukey HSD post hoc test ($p < 0.05$).

suppressing P38 MAPK activation.^{42,49} The P38 MAPK may be an important mediator of proinflammatory cytokines production in a variety of forms of renal injury in proximal tubule cells in response to cisplatin.⁵¹ Genistein reduced ROS production in cisplatin-induced human kidney HK-2 cells, genistein one of EEBS compound have ability to prevent cisplatin-induced renal injury.³³ Genistein possesses protective effects on renal ischemia-reperfusion injury through apoptosis inhibition and regeneration.⁵²

3.7. Effect EEBS toward renal weight in acute renal disease rat model

Inflammation in the kidney tubular cells can lead to injury of the endothelium. This may lead to renal vasoconstriction which causes water retention and edema (swelling) of the kidney.³⁷ Our model shows cisplatin-induced rats experienced significant renal weight gain that probably is caused by edema (Fig. 12) which marked renal hypertrophy. The increased of renal weight can be caused by the

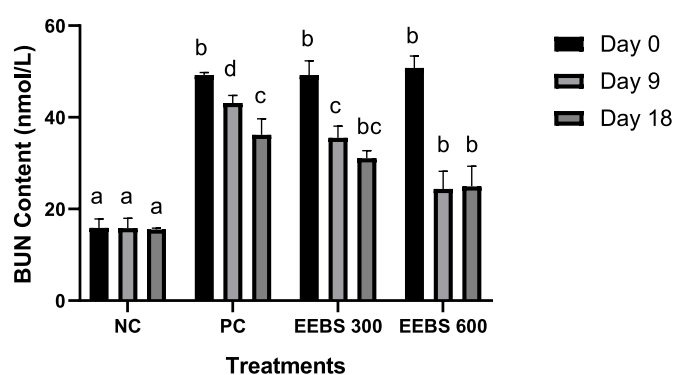


Fig. 9. Effect EEBS toward BUN level in acute renal disease rat model. Data are presented as mean \pm SD. NC: negative control (normal rat + untreated EEBS); PC: positive control (Cisplatin-induced rat); EEBS 300: positive control + EEBS 300 mg/kg BW; EEBS 600: positive control + EEBS 600 mg/kg BW. Different letters (a,b) show significant difference of BUN level among treatments in day 0, different letters (a,b,c,d) show significant difference of BUN content among treatments in day 9, and different letters (a,b,bc) show significant difference of BUN content among treatments in day 18. All statistical different was based on Tukey HSD post hoc test ($p < 0.05$).

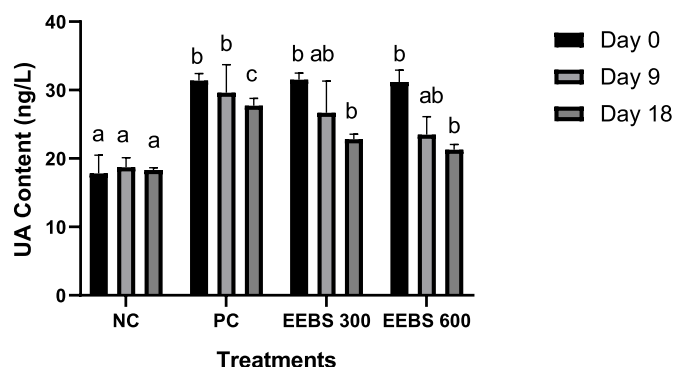


Fig. 10. Effect EEBS toward UA level in acute renal disease rat model*. Data are presented as mean \pm SD. NC: negative control (normal rat + untreated EEBS); PC: positive control (Cisplatin-induced rat); EEBS 300: positive control + EEBS 300 mg/kg BW; EEBS 600: positive control + EEBS 600 mg/kg BW. Different letters (a,b) show significant difference of UA content among treatments in day 0, different letters (a,b,ab) show significant difference of UA content among treatments in day 9, and different letters (a,b,c) show significant difference of UA content among treatments in day 18. All statistical different was based on Tukey HSD post hoc test ($p < 0.05$).

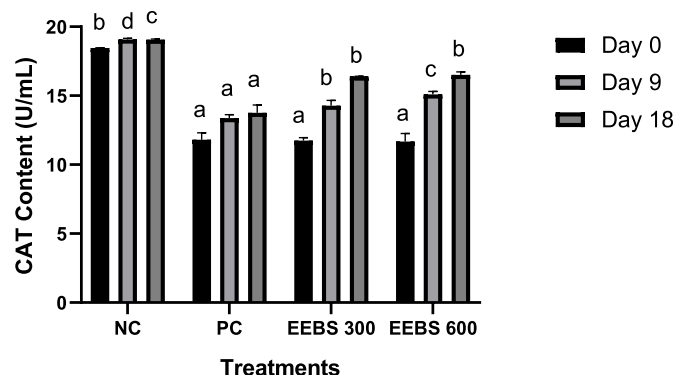


Fig. 11. Effect EEBS toward CAT activity in acute renal disease rat model* Data are presented as mean \pm SD. NC: negative control (normal rat + untreated EEBS); PC: positive control (Cisplatin-induced rat); EEBS 300: positive control + EEBS 300 mg/kg BW; EEBS 600: positive control + EEBS 600 mg/kg BW. Different letters (a,b) show significant difference of CAT content among treatments in day 0, different letters (a,b,c,d) show significant difference of CAT content among treatments in day 9, and different letters (a,b,c) show significant difference of CAT content among treatments in day 18. All statistical different was based on Tukey HSD post hoc test ($p < 0.05$).

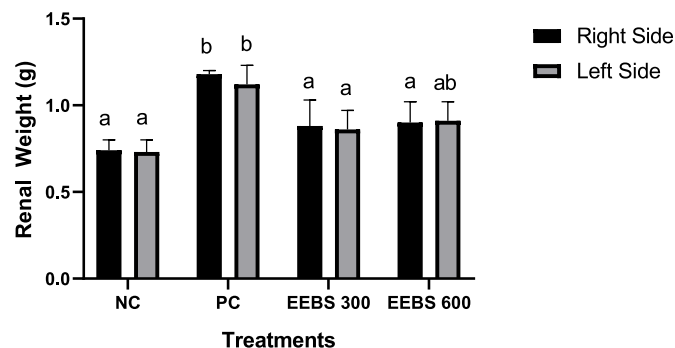


Fig. 12. Effect EEBS toward renal weight in acute renal disease rat model* Data are presented as mean \pm SD. NC: negative control (normal rat + untreated EEBS); PC: positive control (Cisplatin-induced rat); EEBS 300: positive control + EEBS 300 mg/kg BW; EEBS 600: positive control + EEBS 600 mg/kg BW. Different letters (a,b) show significant difference of renal weight among treatments in right side, different letters (a,b) show significant difference of renal weight among treatments in left side. All statistical different was based on Tukey HSD post hoc test ($p < 0.05$).

fluid accumulation or increasing of capillary wall permeability.³⁸ EEBS treatment seemed to protect nephrotic kidney from hypertrophy, although the result was not significant compared to positive control nor negative control. Moreover, increased of renal weight also can be caused by the increasing of capillary wall permeability.³⁸

4. Conclusion

The ethanol extract of black soybean (*Glycine max* L. Merr.) contained daidzein, daidzin, genistin, biochanin A, and glycitein. The black soybean extract treatments has ability to improve nephrotic kidney condition that caused by cisplatin induction by lowering pro-inflammatory cytokines IL-1 β and IFN- γ , and improve physiological condition as marked by lowering BUN and UA level, while elevating CAT activity. However, black soybean extract has potential to improve acute renal failure through inflammatory suppression and renal function improvement.

Declaration of competing interest

There is no conflict of interest.

Acknowledgment

We are gratefully acknowledge the financial support of Penelitian Terapan Unggulan Perguruan Tinggi 2019 from Directorate General of Higher Education, Ministry of Research, Technology and Higher Education of the Republic of Indonesia. This research supported by Aretha Medika Utama-Biomolecular and Biomedical Research Center, Bandung, Indonesia for methodology and laboratory facilities. We would also extend our gratitude to Seila Arumwardana, Cahyaning Riski Wijayanti, Cintani Dewi Wahyuni and Ervi Afifah from Aretha Medika Utama Biomolecular and Biomedical Research Center, Bandung, Indonesia for their technical support.

References

- Soliman A, Desouky S, Marzouk M, et al. *Origanum majorana* attenuates nephrotoxicity of cisplatin anticancer drug through ameliorating oxidative stress. *Nutrients*. 2016;8:1–9.
- Ajith TA, Usha S, Nivitha V. Ascorbic acid and α -tocopherol protect anticancer drug cisplatin induced nephrotoxicity in mice: a comparative study. *Clin Chim Acta*. 2007;375:82–86.
- Miller RP, Tadagavadi RK, Ramesh G, et al. Mechanisms of cisplatin nephrotoxicity. *Toxins (Basel)*. 2010;2:2490–2518.
- Manohar S, Leung N. Cisplatin nephrotoxicity: a review of the literature. *J Nephrol*. 2018;31:15–25.
- Karasawa T, Steyger PS. An integrated view of cisplatin-induced nephrotoxicity and ototoxicity. *Toxicol Lett*. 2015;237:219–227.
- Niu C, Ma M, Han X, et al. Hyperin protects against cisplatin-induced liver injury in mice. *Acta Cir Bras*. 2017;32:633–640.
- Lu HY, Ning XY, Chen YQ, et al. Predictive value of serum creatinine, blood urea nitrogen, uric acid, and β 2-microglobulin in the evaluation of acute kidney injury after orthotopic liver transplantation. *Chin Med J (Engl)*. 2018;131:1059–1066.
- Zhu H, Cao R. The relationship between serum levels of uric acid and prognosis of infection in critically ill patients. *World J Emerg Med*. 2012;3:186–190.
- Astadi IR, Astuti M, Santoso U, et al. In vitro antioxidant activity of anthocyanins of black soybean seed coat in human low density lipoprotein (LDL). *Food Chem*. 2009;112:659–663.
- Hung Y-H, Huang H-Y, Chou C-C. Mutagenic and antimutagenic effects of methanol extracts of unfermented and fermented black soybeans. *Int J Food Microbiol [Internet]*. 2007;118:62–68.
- Takahashi R, Ohmori R, Kiyose C, et al. Antioxidant activities of black and yellow soybeans against low density lipoprotein oxidation. *J Agric Food Chem*. 2005;53:4578–4582.
- Prahastuti S, Hidayat M, Hasiana ST, et al. The ethanol extract of the bastard cedar (*Guazuma ulmifolia* L.) as antioxidants. *Pharmaciana*. 2020;10:77–88.
- Liu J, Wen XY, Zhang XQ, et al. Extraction, characterization and in vitro antioxidant activity of polysaccharides from black soybean. *Int J Biol Macromol*. 2015;72:1182–1190.
- Widowati W, Prahastuti S, Ekayanti NLW, et al. Anti-inflammation assay of black soybean extract and its compounds on lipopolysaccharide-induced RAW 264.7 cell. *J Phys Conf Ser*. 2019;1374:1–11, 012052.
- Sun J, Wen X, Liu J, et al. Protective effect of an arabinogalactan from black soybean against carbon tetrachloride-induced acute liver injury in mice. *Int J Biol Macromol*. 2018;117:659–664.
- Hidayat M, Prahastuti S, Fauziah N, et al. Modulation of adipogenesis-related gene expression by ethanol extracts of Detam 1 soybean and jati belanda leaf in 3T3-L1 cells. *Bangladesh J Pharmacol*. 2016;11:697–702.
- Gondokusumo ME, Pradjianto B, Sumitro SB, et al. Xanthones analysis and antioxidant activity analysis (Applying ESR) of six different maturity levels of mangosteen rind extract (*Garcinia mangostana* Linn.). *Phcog J*. 2019;11:369–373.
- Akca G, Eren H, Tumkaya L, et al. The protective effect of astaxanthin against cisplatin-induced nephrotoxicity in rats. *Biomed Pharmacother*. 2018;100:575–582.
- Pang M, Fang Y, Chen S, et al. Gypenosides inhibits xanthine oxidoreductase and ameliorates urate excretion in hyperuricemic rats induced by high cholesterol and high fat food (lipid emulsion). *Med Sci Monit*. 2017;23:1129–1140.
- Al-Kuraishy HM, Al-Gareeb AI, Al-Naimi MS. Renoprotective effect of irbesartan in a rat model of gentamicin-induced nephrotoxicity: role of oxidative stress. *J Lab Phys*. 2019;11:200–205.
- Soliman MM, Nassan MA, Aldahrani A, et al. Molecular and histopathological study on the ameliorative impacts of *Petroselinum crispum* and *Apium graveolens* against experimental hyperuricemia. *Sci Rep*. 2020;10:1–11.
- Darband SG, Sadighparvar S, Yousefi B, et al. Combination of exercise training and l-arginine reverses aging process through suppression of oxidative stress, inflammation, and apoptosis in the rat heart. *Pflügers Arch - Eur J Physiol*. 2020;472:169–178.

23. de Camargo AC, Favero BT, Morzelle MC, et al. Is chickpea a potential substitute for soybean? Phenolic bioactive and potential health benefits. *Int J Mol Sci.* 2019;20:1–42.
24. Zhou R, Cai W, Xu B. Phytochemical profiles of black and yellow soybeans as affected by roasting. *Int J Food Prop.* 2017;20:3179–3190.
25. Kim IS. Current perspectives on the beneficial effects of soybean isoflavones and their metabolites for human. *Antioxidants.* 2021;10:1–54.
26. Phommalath S, Teraishi M, Yoshikawa T, et al. Wide genetic variation in phenolic compound content of seed coats among black soybean cultivars. *Breed Sci.* 2014;64:409–415.
27. Sheu F, Lai H-H, Yen G-C. Suppression effect of soy isoflavones on Nitric Oxide production in RAW 264.7 macrophages. *Agric Food Chem.* 2001;49:1767–1772.
28. Ozkok A, Edelstein CL. Pathophysiology of cisplatin-induced acute kidney injury. *BioMed Res Int.* 2014;2014:1–18.
29. Humanes B, Camano S, Lara JM, et al. Cisplatin-induced renal inflammation is ameliorated by cilastatin nephroprotection. *Nephrol Dial Transplant.* 2017;32:1645–1655.
30. Grabulosa CC, Batista MC, Cendoroglo M, et al. Frequency of TGF- β and IFN- γ genotype as risk factors for acute kidney injury and death in intensive care unit patients. *BioMed Res Int.* 2014;2014:1–7.
31. Karan D. Inflammasomes: emerging central players in cancer immunology and immunotherapy. *Front Immunol.* 2018;9:1–8.
32. Meng H, Fu G, Shen J, et al. Ameliorative effect of daidzein on cisplatin-induced nephrotoxicity in mice via modulation of inflammation, oxidative stress, and cell death. *Oxid Med Cell Longev.* 2017:1–21.
33. Sung MJ, Kim DH, Jung YJ, et al. Protects the kidney from cisplatin-induced injury. *Kidney Int.* 2008;27:1538–1547.
34. Vargas F, Romecín P, García-Guillén AI, et al. Flavonoids in kidney health and disease. *Front Physiol.* 2018;9:1–12.
35. Yu G, Liu Q, Dong X, et al. Inhibition of inflammation using diacerein markedly improved renal function in endotoxemic acute kidney injured mice. *Cell Mol Biol Lett.* 2018;23:1–12.
36. He L. Dietary fermented soy extract and active lactic acid alleviate chronic kidney disease in mice via inhibition of inflammation and modulation of gut microbiota (FS15-07-19). *CDN.* 2019;3. nzz031-FS15.
37. Sahu BD, Kumar JM, Sistla R. Baicalein, a bioflavonoid, prevents cisplatin-induced acute kidney injury by up-regulating antioxidant defenses and down-regulating the MAPKs and NF- κ B pathways. *PLoS One.* 2015;10:1–19.
38. Basile DP, Anderson MD, Sutton TA. Pathophysiology of acute kidney injury. *Compr Physiol.* 2012;2:1303–1353.
39. Bobkova I, Chebotareva N, Kozlovskaya L, et al. Edema in renal diseases – current view on pathogenesis. *Nephrol @ Point Care.* 2016;2:e49–e55.
40. Giordano C, Karasik O, King-Morris K, et al. Uric acid as a marker of kidney disease: review of the current literature. *Dis Markers.* 2015;2015:1–7.
41. Seki M, Nakayama M, Sakoh T, et al. Blood urea nitrogen is independently associated with renal outcomes in Japanese patients with stage 3–5 chronic kidney disease: a prospective observational study. *BMC Nephrol.* 2019;20:1–10.
42. Ademiluyi AO, Oboh G, Agbebi OJ, et al. Anthocyanin - rich red dye of *Hibiscus sabdariffa* calyx modulates cisplatin-induced nephrotoxicity and oxidative stress in rats. *Int J Biomed Sci.* 2013;9:243–248.
43. Mishima K, Baba A, Matsuo M, et al. Protective effect of cyclic AMP against cisplatin-induced nephrotoxicity. *Free Radic Biol Med.* 2006;40:1564–1577.
44. Wu YL, Chen JF, Jiang LY, et al. The extract of *Sonneratia apetala* leaves and branches ameliorates hyperuricemia in mice by regulating renal uric acid transporters and suppressing the activation of the JAK/STAT signaling pathway. *Front Pharmacol.* 2021;12:1–14.
45. Suliman FA, Khodeer DM, Ibrahim A, et al. Renoprotective effect of the isoflavonoid biochanin A against cisplatin induced acute kidney injury in mice: effect on inflammatory burden and p53 apoptosis. *Int Immunopharm.* 2018;61:8–19.
46. Ratliff BB, Abdulmahdi W, Pawar R, et al. Oxidant mechanisms in renal injury and disease. *Antioxidants Redox Signal.* 2016;25:119–146.
47. Yoo KM, Al-Farsi M, Lee H, et al. Antiproliferative effects of cherry juice and wine in Chinese hamster lung fibroblast cells and their phenolic constituents and antioxidant activities. *Food Chem.* 2010;123:734–740.
48. Naqshbandi A, Khan W, Rizwan S, et al. Studies on the protective effect of flaxseed oil on cisplatin-induced hepatotoxicity. *Hum Exp Toxicol.* 2012;31:364–375.
49. Yousef MI, Hussien HM. Cisplatin-induced renal toxicity via tumor necrosis factor- α , interleukin 6, tumor suppressor P53, DNA damage, xanthine oxidase, histological changes, oxidative stress and nitric oxide in rats: protective effect of ginseng. *Food Chem Toxicol.* 2015;78:17–25.
50. Ekor M, Emerole GO, Farombi EO. Phenolic extract of soybean (*Glycine max*) attenuates cisplatin-induced nephrotoxicity in rats. *Food Chem Toxicol.* 2010;48:1005–1012.
51. Okazaki Y, Iqbal M, Kawakami N, et al. A beverage containing fermented black soybean ameliorates ferric nitrilotriacetate-induced renal oxidative damage in rats. *J Clin Biochem Nutr.* 2010;47:198–207.
52. Li W-F, Yang K, Zhu P, et al. Genistein ameliorates ischemia/reperfusion-induced renal injury in a SIRT1-dependent manner. *Nutrients.* 2017;9:1–21.