



RESEARCH ARTICLE

Garcinia Mangostana Extract Enhances Skin Epithelialization in Rat Induced Burn Injury

Marisca Evalina Gondokesumo^{1,2#}, Bambang Pardjianto³, Kusworini Handono⁴, Sutiman Bambang Sumitro⁵, Wahyu Widowati⁶, Okta Wismandanu⁷, Tyagita Hartady⁷, Aziiz Mardanarian Rosdianto⁷, Hanna Goenawan^{7,8,9}, Ronny Lesmana^{7,8,9}, Nasrul Wathoni¹⁰ and Unang Supratman^{9,11}

¹Biomedical Sciences Doctoral Study, Faculty of Medicine, Brawijaya University, Malang, Indonesia; ²Faculty of Pharmacy, University of Surabaya, Surabaya, Indonesia; Department of Plastic Surgery Saiful Anwar General Hospital, Faculty of Medicine, Brawijaya University, Malang, Indonesia; ⁴Department of Clinical Pathology, Faculty of Medicine, Brawijaya University, Malang, Indonesia; ⁵Biology Department, Faculty of Mathematics and Natural Sciences, Brawijaya University, Malang, Indonesia; ⁶Faculty of Medicine, Maranatha Christian University, Bandung, Indonesia; ⁷Veterinary Medicine Study Program, Universitas Padjadjaran, Bandung, Indonesia; Physiology Division, Department of Biomedical Sciences, Faculty of Medicine, Universitas Padjadjaran, Bandung, Indonesia; Division of Biological Activity, Central Laboratory, Universitas Padjadjaran, Bandung, Indonesia; Department of Pharmaceutics and Pharmaceutical Technology, Faculty of Pharmacy, Universitas Padjadjaran, Bandung, Indonesia; ¹¹Department of Chemistry, Faculty of Mathematics and Natural Sciences, Universitas Padjadjaran, Bandung, Indonesia

*Corresponding author: mariscaevalina@gmail.com

ARTICLE HISTORY (18-314)

Received: August 31, 2018
Revised: March 24, 2019
Accepted: April 07, 2019
Published online: April 23, 2019

Key words:

Burn injury
EGF
Mangosteen
Wound healing

ABSTRACT

Mangosteen has several important elements for biological activities such as anti-oxidant, anti-inflammatory, anti-bacterial and anti-cancer. There are γ -mangostin, α -mangostin, flavonoids, saponins, and tannins which could stimulate the collagen deposition and accelerate wound healing process. Burn injury cause deep wound in the skin and often cause cicatrix and keloid scar on the skin. However, there is limited information about role of mangosteen in skin wound healing after burn injury. Fifty 10 week-old male rats, were subjected to burn injury using automatic temperature control. Burn injury was created by direct contact of hot plate (170°C) for 15 seconds on rats' inter scapula region. We elaborated the role of extract mangosteen in skin wound healing by applying daily gel contain with active compound derived from mangosteen. There was no significant weight change during treatment period. We observed that there was significant increase of Epidermal Growth Factors (EGF) expression in 14 as shown in immunohistochemistry and confirmed by western blot protein results. Taken together, mangosteen peel extract-mediated changes in the expression of growth factors in burned rat skins. Mangosteen peel extract might have a role in the acceleration of skin wound healing.

©2019 PVJ. All rights reserved

To Cite This Article: Gondokesumo ME, Pardjianto B, Handono K, Sumitro SB, Widowati W, Wismandanu O, Goenawan H, Hartady T, Rosdianto AM, Lesmana R, Wathoni N and Supratman U, 2019. *Garcinia Mangostana* extract enhances skin epithelialization in rat induced burn injury. *Pak Vet J*, 39(3): 365-370. <http://dx.doi.org/10.29261/pakvetj/2019.059>

INTRODUCTION

Burn injury is one of devastating traumas that affected numerous organ systems. Burn injury causes more than 300,000 deaths per year globally (Branski *et al.*, 2009). The resources needed to treat burn patients generate an immense burden on the health care system. Even though important advances have been made in reducing the complication and mortality rate in burn injury, burns management and treatments are still not optimal especially in Indonesian rural areas.

The use of plant extraction for wound was reported in many areas of Indonesia (Elfahmi *et al.*, 2014). Harnessing herbal medicine is a promising way to reduce

the financial burden of wound treatments and could promote local community economic development. Furthermore, reliable researches could support the rational use of natural ingredients as medications for burns. At present, mangosteen peel-based products are very popular in Indonesia mainly attributes to its anti-oxidant properties (Kurniawati, 2017). Xanthone is the major active compound found in mangosteen peel extract (MPE). MPE are consisted with bioactive compounds such as α -mangosteen and γ -mangostin. Alpha mangosteen is one type of xanthones that has wide biological activity such as anti-oxidant, anti-bacterial, anti-inflammatory, anti-allergy, antimicrobial, analgesic, anticancer and cytotoxic (Chin and Kinghorn, 2008; Ibrahim *et al.*, 2016; Kurniawati, 2017).

Another important element in MPE are γ -mangostin, flavonoids, saponins, and tannins which effects are increasing collagen deposit and accelerating wound healing (Gutierrez-Orozco and Failla, 2013; Yoshimura *et al.*, 2015; Waheed *et al.*, 2015).

Burn injury affected multiple organ systems. Due to its complexity, *in vitro* experiments have limitations to capture this complexity nor address the pathophysiology. In the past two decades, a number of burn animal models have been developed to replicate the various aspects of burn injury; to elucidate the pathophysiology and explore potential treatment interventions. Understanding the advantages and limitations of these animal models is essential for the design and development of treatments that are clinically relevant to humans (Abdullahi *et al.*, 2014). Among all animal models, rats are one of the most commonly used animals for skin injury models (Mitsunaga *et al.*, 2012). Characteristic of rat's skin has highly similarities with human skin, both has epidermis and dermis. Rats as animal models might be used to study pathophysiology of skin injuries and wound healing studies (Pandurangan *et al.*, 2010; Suruse *et al.*, 2011; Anitha *et al.*, 2015; Avinash *et al.*, 2016). Therefore, in this study, we used rat model of burn injury *in vivo* study to determine the efficacy of topical treatment such as MPE for burn injury.

Interaction of complex signaling molecule is found in wound healing process (Li *et al.*, 2016). Epidermal Growth Factor (EGF) is one of the signaling molecule that play role in wound healing process. EGF is a polypeptide that stimulates cell growth and differentiation. It accelerates wound healing rates through enhancing synthesis of basement membrane and extracellular matrix components, cell motility, and proliferation (Değim *et al.*, 2011). High level of EGF is detected in earliest wound healing process. EGF expression shorten epitalization duration and reduce scarring by inhibit excessive wound contraction (Steed, 1998; Inoue *et al.*, 1998; Svensjo *et al.*, 2002). In addition, some studies suggested that EGF application in wound is effective as an adjuvant therapy (Gorouhi *et al.*, 2014; Li *et al.*, 2016). Thus, it is interesting to reveal the effects of topical treatment of mangosteen peel extract to modulate EGF expression in animal burn injury models.

The aim of this study was to evaluate the efficacy of MPE as a topical remedy for the burn injury treatment. In addition, our study also had explored the MPE-mediated changes in the expression of EGF burned rat skins, which might have a role in the acceleration of skin wound healing.

MATERIALS AND METHODS

Burn Injury automatic tools: Double plate was joined with heat to make a flat metal plate. A 10 cm square length wood was placed in the top of the plate as a handle, then automatic thermometer was integrated into double plate and heated using Gas Burner until 170°C for every treatment (Supplemental Fig. 1).

Animal: The animal experiment protocol was approved by the Ethic Research Committee, Faculty of Medicine, Universitas Padjadjaran (No:11/UN6.KEP/EC/2018).

Fifty male Wistar rats, age 10 weeks (body weight 220±10 g) used in the present study were purchased from Biofarma Pharmaceutical Company (Bandung, Indonesia). Rats were divided into 4 groups: Control (FI), Silver sulfadiazine (SS), MPE dose 1 (FII) and dose 2 (FIII). They were kept in standard individual cages and provided with food and water *ad libitum*. The room temperature was kept at 24°C under a 12h light - 12h dark cycle (light on: 06:00-18:00). Environment humidity was maintained stable throughout the project.

After a week habituation process, Rats were anesthetized with ketamine and xylazine via intraperitoneal injection. The hair on the dorsum, interscapula region was shaved off and cleaned to ensure the burn wounding which was induced by using hot metal plate connected to automatic temperature control. The metal plate (area 2 cm x 2 cm) was heated on 170°C. The heated metal plate was placed in the exposed skin area vertically without any additional pressure for 15 seconds to induce burn injury. The animals were placed in individual cages until wound healing completed. During the wound healing process, rats were treated with four different vehicles according to group treatment. Vehicle gels were measured and taken 1ml using pipet then vehicle was applied topically using cotton buds every morning for 14 days after burn injury induction.

Burn Injury Topical Gel Extract

Mangosteen peels: Mangosteen peels were obtained from Bogor, Purwakarta, Tasikmalaya, and Subang (West Java, Indonesia) were identified by Drs. Joko Kusmoro, MS., a scientist in Department of Biology, the Faculty of Mathematics and Natural Sciences, Universitas Padjadjaran. Samples were cleaned, cut, air-dried, and finally powdered. Fruit rinds were extracted by maceration using 900 mL of 70% ethanol for 72 hours. The thick extract was freeze-dried to obtain dry extract of mangosteen peels.

The tools used for making gels extract were mortars, stampers, analytical scales (Shimadzu ATX224), glassware, petri dishes, weights, pH meters (S220 Seven Compact), refrigerated centrifuge (5702R), and microscope (Olympus CX23 LED). The material used in this study were the freeze dried mangosteen peel extract, pharmaceutical quality Na-CMC obtained from PT. Hensan Bersama Sukses. Aquades, propylenglycol, glycerol, and methyl paraben, each was obtained from PT. Brataco.

Manufacture of Extracted Gel using Na-CMC Base:

The Na-CMC base is made with a concentration of 2%. Na-CMC was developed at 15 mL distilled water at 70°C (Mixture 1). Furthermore, methyl paraben was dissolved in a small amount of distilled water then added a mixture of glycerin and propylenglycol (Mixture 2). Mixture of all compound were diluted using aquades until final volume 20mL. While the extract gels were prepared in two different dose, 0.2 grams and 0.4 grams. Gel formula is presented in Table 1. Gel making is done by mixing several compounds. Na-CMC acts as gelling agent, propylenglycol and glycerin as a humectant and maintains the stability of the preparation, methyl paraben acts as a preservative, and aquades as a solvent. The gel

preparations were evaluated together with Burnazin® and Mebo® products as a positive control. The evaluation of preparations was carried out on the 0th, 7th, 14th and 28th days of each test carried out three times (triplo). Data from organoleptic test results can be seen. From the organoleptic observations, there was no change in shape, odor, and color for all samples (base Na-CMC, extract dose 0.2, extract dose 0.4, Burnazin and Mebo) from testing day 0 to day 28. The pH test results showed a change in acidic pH close to normal pH. PH test data can be seen in Supplemental Fig. 2.

Four different topical gels were made in accordance Indonesian Pharmaceutical recommendation: 1) a gel with no active ingredients (vehicle gel/FI) 2) gel with silver sulfadiazine as positive control; 3) a gel that contained 0.2 mg mangosteen skin extract (FII) and 4) a gel that contained 0.4 mg mangosteen peel extract (FIII). All gels base was consisted Na-CMC as gelling agent, methyl paraben as preservative, glycerine and propilen glycol as humectant and solubilized in water. Gel formulation was presented in Table 1.

Immunohistochemistry: At day fourteen after burn injury, animals were sacrificed with an inhalation anesthesia. Burn injury skin samples were fixed in paraformaldehyde 4% (lot no. 158127, Sigma Aldrich, Merck KGA, Darmstadt, Germany) in 4°C overnight. The sample were embedded in paraffin and cut into 5µm section with microtome (Leica, Leica Biosystem Nussloch GmbH, Wetzlar, Germany). Skin slice stained with HE (Thermo Fisher Scientific, Waltham, Massachusetts, USA). Histological slices were examined using light microscope (Zeiss Apotome 2, Carl Zeiss AG, Oberkochen, Germany). Two section per animal were used for analysis. For immunohistochemistry, slices were deparaffinized in xylene and rehydrated in a graded alcohol series. Retrieval using Dako target retrieval solution (DakoCytomation, Denmark) for 20 min. Tris buffered saline (TBS) were used to washing specimen. Slices were incubated with 5% Bovine serum antibody (Thermo Fisher Scientific, Waltham, Massachusetts, USA) followed by primary antibody treatment, EGF concentration 1:200 (Ab 77851, Abcam, Cambridge, UK) in 4°C overnight. Slices washed with TBS 3 times 5 minutes each. Incubation with secondary antibody (1:200) and streptavidin biotinylated horseradish peroxidase complex, dilution 1:200 (Thermo Fisher Scientific, Waltham, Massachusetts, USA) was added to the section. Hematoxylin was used for counterstaining.

HE staining: The skin sample was fixed in 10% formalin. Epidermal structures of burn injury skin were examined by Hematoxylin Eosin (HE) staining. After routine processing, the skin sample was imbedded in paraffin wax. Four-µm-thick slices were prepared and stained with hematoxylin and eosin for evaluation with light microscope.

Western blot: Western blot protocol was adopted from pratiwi *et al.* (2018). Skin tissues were solubilized with 500 µl lysis buffer (50mM PBS, 5mM EDTA, 0.4% Triton X and protease inhibitors). Protein concentration of each sample was measured using Lowry method. The

protein concentration was adjusted to 5µg/µl and sample was mixed with 2x buffer solution (1:1) containing 250 mM Tris-HCl, 6% SDS, 50µg /µl bromophenol blue, 10% glycerol and 10% β-mercaptoethanol. Sample was heated to 95°C for 5 min. 15 µl sample was used for sample electrophoresis with 10% SDS-polyacrilamide gel. Sample protein were blotted into nitrocellulose membrane and blocked with 2.5% skim milk in Phosphate buffered saline (PBST) for 2 hours at room temperature. Incubation of primary antibody EGF (Abcam, Cambridge UK) in Bovine Serum Albumin was using concentration 1:500 overnight in 4°C. The secondary antibodies used were HRP conjugate anti mouse and anti-rabbit IgG (Santa Cruz Biotech. Dallas, USA). Immunoblotted proteins were visualized with chemiluminescence reagent ECL (Li-cor Biosciences, Lincoln, Nebraska, USA). Band density was measured using ImageJ (NIH) software. Data were analyzed by ANOVA and Tukey post hoc test. Statistically significance were considered with P<0.05.

RESULTS

Wound healing: The burned area on the first day did not differ macroscopically among all groups (Fig. 1A). These results are comparable with Hematoxylin Eosin staining preparation results (Fig. 2A-D). No epithelialization was detected in first day after burn injury. The differences in healing rate become prominent on day 14, in which MPE treated group showed reduction in wound area greater than control group (Fig. 1A). Furthermore, MPE dose 1 group and MPE dose 2 showed different healing pattern compared with silver sulfadiazine (SS) group (Fig. 1A-B). In SS group, the decrustation was almost completed on day 14, where in MPE dose 1 and dose 2 group the scab was still covering the major part of the wound. Histology results showed, on day 14, epithelization percentage was highest in MPE dose 2 group and lowest in control group as described in Fig. 2H and Fig. 2E continuously. No observable differences were seen between MPE dose 1 treated group (Fig. 2H) and SS treated group (Fig. 2F) group in epithelization percentage on 14th day of injury.

EGF Immunohistochemistry: Immunohistochemistry was performed to determine the expression of EGF in skin injury tissue as seen in Fig. 3. On day 1 and day 14, expression of EGF was higher in MPE dose 1 and dose 2 groups than control group. For SS group, the level of EGF expression from IHC was not in accordance with western blot assay. From IHC (Fig. 3B), the SS group showed relatively similar level of EGF compared to control group.

EGF protein expression: Western blot analysis of EGF protein level on day 14 were demonstrated in Fig. 4. EGF was up regulated in SS, Mangosteen peel extract (MPE) dose 1 and dose 2 groups compared to control group. EGF expression in MPE dose 1, 2 and SS relatively higher compared with control group as shown in representative Figure (Fig. 4A) and densitometric calculation using Image J showed that EGF protein level was increased nearly 3,5 folds (Fig. 4B).

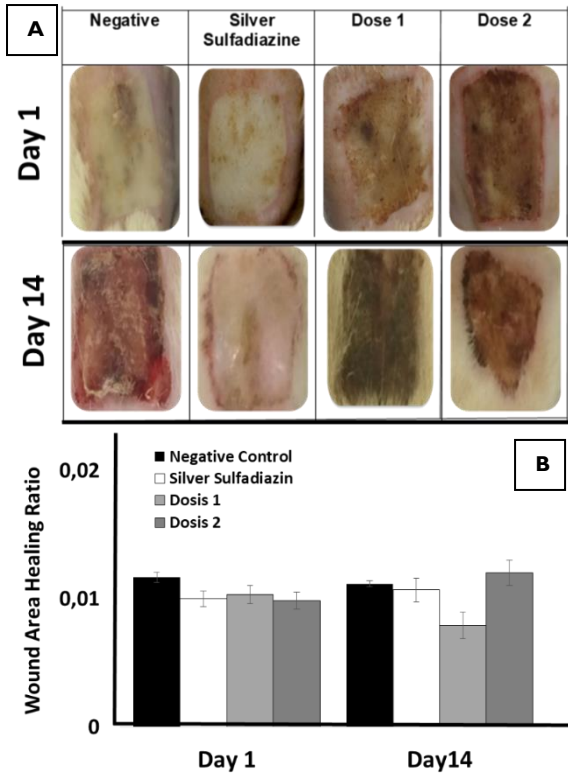


Fig. 1: Macroscopic image of burn wound on day 1 (Figure 1 A-D) and day 14 (E-H). On Day 1, the wound characteristics between negative control (FI; A), Silver Sulfadiazine (SS; B), dose 1 (FII; C) and dose 2 (FIII; D) were relatively similar. On Day 14, negative control (E) wound showed redness and exudate, where in dose 2 (H) there was scab formation and wound size reduction. Silver Sulfadiazine group (F) showed complete decrustation.

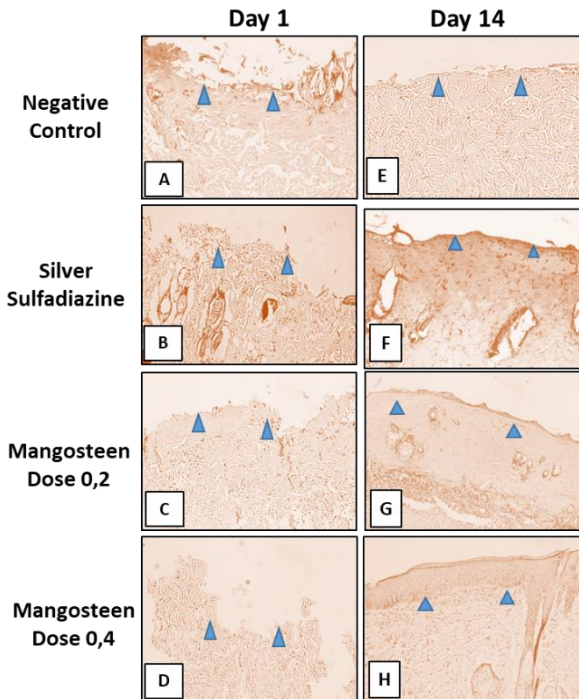


Fig. 2: Microscopic image (400x magnification) of burn wound on day 1 (A-D) and day 14 (E-H) with hematoxylin and eosin staining. On Day 1, there were complete loss of epidermis and partial loss of dermis in negative control (FI; A), Silver Sulfadiazine (SS; B), dose 1 (FII; C) and dose 2 (FIII; D) group which indicate second degree burn. On Day 14, negative control group (E) showed incomplete reepithelization. On the other hand, Silver Sulfadiazine (F), and dose 2 (H) showed complete reepithelization. Arrow heads represent Epidermis-dermis junction.

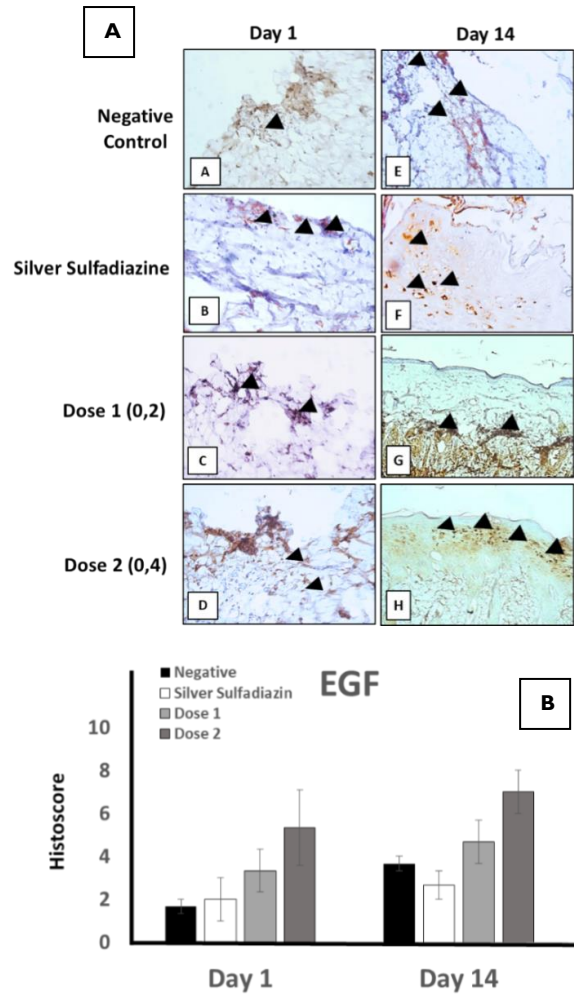


Fig. 3: Epidermal Growth Factor (EGF) expression by immunohistochemistry (IHC). A) Macroscopic image (400x) of wound on day 1 (AA-D) and day 14 (AE-H). Arrowheads represent EGF protein. B) EGF expression on day 1 and 14 were higher in dose 2 group than negative control and SS group. IHC expression was counted using histocore (Figure Data is expressed as average with standard error of mean (n=3 per group).

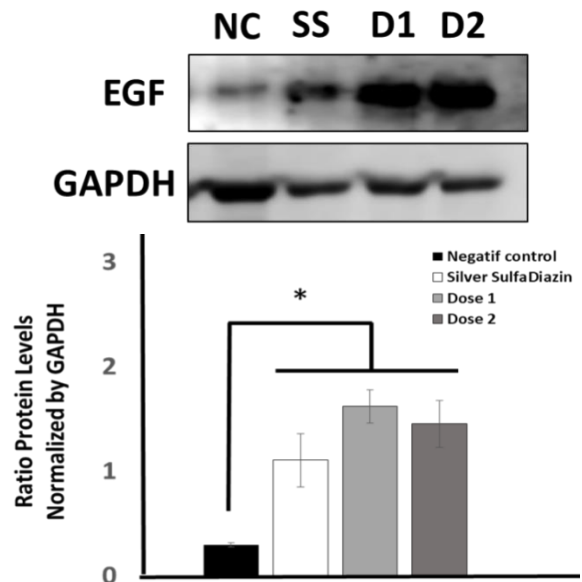
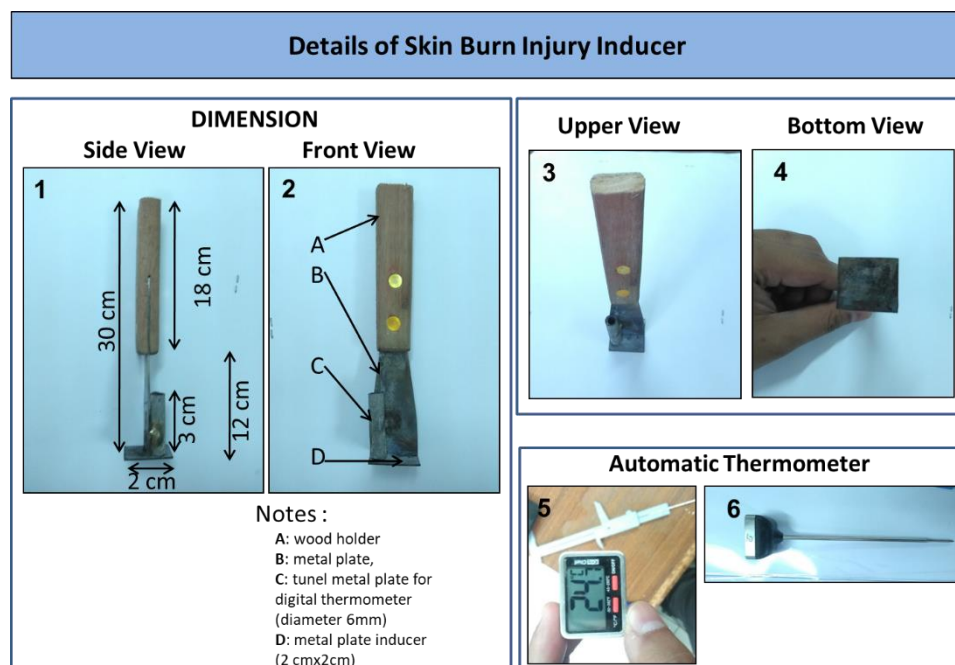


Fig. 4: Epidermal Growth Factor (EGF) expression on day 14 by western blot. EGF expression was significantly higher in SS, dose 1 (FII) and dose 2 (FIII) group than control group (FI). Data is expressed as average with standard error of mean. * P<0.05.

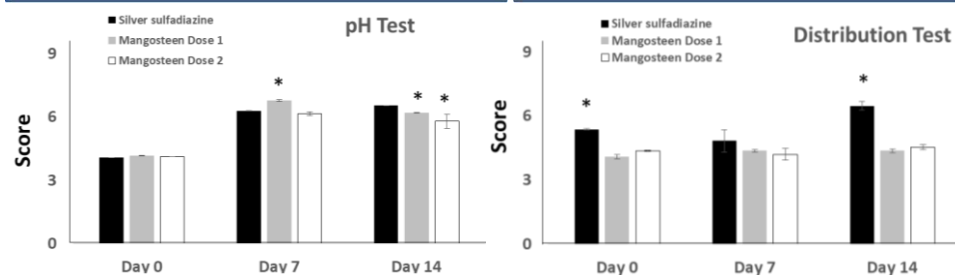


Supplemental Fig. 1: Burn Injury Inducer. Tools detail and references used for developing burn injury inducer.

Tools scientific reference:

1. Mohammad Javad Fatemi, Babak Nikoomaram, Amir Asadollah Khajeh Rahimi, Donya Talayi, Shahrzad Taghavi, and Yaser Ghavami. Effect of green tea on the second degree burn wounds in rats. *Indian J Plastic Surgery*. 2014; 47: 370-4.

2. Danielle dos Santos Tavares Pereira, Maria Helena Madruga Lima-Ribeiro, Nicodemos Teles de Pontes-Filho, Ana Maria dos Anjos Carneiro-Leão, and Maria Tereza dos Santos Correia. Development of Animal Model for Studying Deep Second-Degree Thermal Burns. *Journal of Biomedicine and Biotechnology* 2012; 27:418-22.



Supplemental Fig. 2: Gel pH and distribution Test. Produced and synthesized gel was evaluated for its performance using 2 test; pH test and distribution test. Data is expressed as average with standard error of mean with P < 0.05, *

Table 1: Topical Gel Formulation

Formulation	FI	FII	FIII
Freezedried mangosteen peel extract	-	0.2	0.4
Na-CMC	0.4g	0.4g	0.4g
Glycerin	2g	2g	2g
Propilenglycol	1g	1g	1g
Methyl paraben	0.03g	0.03g	0.03g
Aquades ad	20g	20g	20g

FI: control, FII: dose 1 (0.2 mg), FIII: dose 2 (0.4 mg).

DISCUSSION

The present study demonstrated that mangosteen peel extract (MPE) increased the healing rate of second degree burn on rat's skin at interscapular area of dorsal skin. We observed the progress in wound healing at different time points throughout the two weeks following treatment. Interestingly, higher efficacy was observed in MPE-treated group than Silver Sulfadiazine treated group. This result might be attributed to anti-oxidant, anti-bacterial and inflammatory modulator properties of MPE (Chen *et al.*, 2018).

Antioxidant properties of natural product accelerate wound healing process by scavenging free radicals from the inflamed site (El-Ferjani *et al.*, 2016). Free radicals might impair the healing process by damaging cellular organelles and aggravating inflammation. Cui *et al.* (2010) showed that α -mangostin and γ -mangostin which were isolated from mangosteen, exhibited strong ability to scavenge reactive oxygen species (ROS) in dose-dependent manner. In addition, previous study showed that α -mangostin could neutralize superoxide anion ($O_2^{\cdot-}$), singlet oxygen (1O_2) and peroxynitrite anion ($ONOO^-$) in

a concentration-dependent manner (Pedrazachaverri *et al.*, 2009). Therefore, antioxidant properties in MPE presumably control inflammation on burned skin and as a result, reepithelization of epidermis can be accelerated.

Sivaranjani *et al.* (2017) have showed the rapid killing efficacy of α -mangostin on *S. epidermidis* *in vitro*. This antimicrobial effects of the extracts are important to prevent microbial infections on the wound area. Therefore, extract of MPE can partially control growth of pathogens over the skin (Chah *et al.*, 2006; Sivaranjani *et al.*, 2017). In addition, other study had shown effect of antibiofilm activity of α -mangostin against *S. aureus* including the ferocious *methicillin-resistant S. aureus* (MRSA) (Phuong *et al.*, 2017). The results showed that α -mangostin was effective to disrupt the biofilms and killed the biofilm embedded bacteria. Therefore, antimicrobial effect of MPE might play a role in burn healing process.

The upregulation in the expression of Epidermal Growth Factor (EGF) in MPE-treated wound is also fascinating to be explored. Our finding showed that EGF protein expression in MPE treated rats was higher compared with control group (Fig. 4). Although the mechanism of how the MPE could fasten the wound healing process remain unclear, the benefit of MPE as burn remedy possibly might be explained by these modulating effects. (Gonzales *et al.*, 2016). *In vitro* and *in vivo* studies showed that EGF enhanced fibroblast and keratinocyte expansion (Choi *et al.*, 2008; Stoll *et al.*, 2012). EGF signal is important to promote migration of keratinocytes at wound margins and also from nearby viable hair follicles and sweat glands (Wenczak *et al.*, 1992). EGF also upregulated the expression of keratin,

epiregulin and loricrin (Hashimoto *et al.*, 1994; Choi *et al.*, 2008; Stoll *et al.*, 2012). Furthermore, previous studies showed that topical administration of recombinant EGF could accelerate reepithelialization, wound contraction and collagen deposition (Kwon *et al.*, 2006). In China, human recombinant EGF and basic fibroblast growth factor (bFGF) topical administration of these growth factors has been proven to shorten the wound healing duration (Shen *et al.*, 2017). Faster wound healing process in MPE treated group possibly due to increase in EGF expression levels. The results of the present study support the development of MPE as a new therapeutic remedy for the treatment of burn wounds. However, there are some limitations which needed to be addressed in the future study. The mechanics of wound-healing between rats and human are not completely similar. In rats, wound contraction is the primary healing mechanism as opposed to reepithelialization seen in human skin (Wong *et al.*, 2011). This is because rodents like rats and mice, have panniculus carnosus muscle in subcutaneous area which can facilitate wound contraction and collagen formation (Dorsett-Martin, 2004; Wong *et al.*, 2011).

Taken together, the topical application of MPE could induce more rapid wound healing than negative control (FI group) and might have comparable efficacy with silver sulfadiazine treatment. This might be partially explained by MPE-induced EGF expression. Further clinical and molecular studies are needed to determine the exact mechanisms involved in the burn wound healing effects of MPE.

Authors contribution: All Authors designed the project. MEG and NW constructed and made MPE gel. MEG, RL, AMR, TH, OW executed the experiment and analyzed the tissue samples. MEG, BP, SBS, RL, HG, WW, and US analyzed the data. All authors critically revised the manuscript and approved the final version.

Acknowledgements: Publication was supported by Grant Aid PDUPT (2019) (Penelitian Dasar Unggulan Perguruan Tinggi No: 3670/UN.6.C/LT/2019) to RL.

REFERENCES

- Abdullahi A, Amini-Nik S and Jeschke MG, 2014. Animal models in burn research. *Cell Mol Life Sci* 71:3241-55.
- Anitha KN, Reddy BS, Velmurugan C, *et al.*, 2015. Pear fruit velocity of woundhealing in dexamethasone delayed wound healing model in rats. *Der Pharmacia Lettre* 7:310-9.
- Avinash S, Gowda DV, Suresh J, *et al.*, 2016. Formulation and evaluation of topical gel using *Eupatorium glandulosum* michx. for wound healing activity. *Der Pharmacia Lettre*, 2016, 8 (9):52-63
- Branski LK, Al-Mousawi A, Rivero H, *et al.*, 2009. Emerging infections in burns. *Surg Infect* 10:389-97.
- Chah KF, Eze CA, Emuelos CE, *et al.*, 2006. Antibacterial and wound healing properties of methanolic extracts of some Nigerian medicinal plants. *J Ethnopharmacol* 104:164-7.
- Chen G, Li Y, Wang W, *et al.*, 2018. Bioactivity and pharmacological properties of α -mangostin from the mangosteen fruit: a review. *Expert Opinion Therap Patents* 28:415-27.
- Chin Y-W and Kinghorn AD, 2008. Structural characterization, biological effects, and synthetic studies on xanthenes from mangosteen (*Garcinia mangostana*), a popular botanical dietary supplement. *Mini-Rev Organic Chem* 5:355-64.
- Choi JK, Jang JH, Jang WH, *et al.*, 2012. The effect of epidermal growth factor (egf) conjugated with low-molecular-weight protamine (LMWP) on wound healing of the skin. *Biomaterials* 33:8579-90.
- Choi JS, Leong KW and Yoo HS, 2008. In vivo wound healing of diabetic ulcers using electrospun nanofibers immobilized with human epidermal growth factor (EGF). *Biomaterials* 29:587-96.
- Cui J, Huand W and Cai Z, 2010. New medicinal properties of mangostins: Analgesic activity and pharmacological characterization of active ingredients from the fruit hull of *Garcinia mangostana*. *L J Pharmacol Biochem Behavior* 95:166-72.
- Değim Z, Çelebi N, Alemardoğlu C, *et al.*, 2011. Evaluation of chitosan gel containing liposome-loaded epidermal growth factor on burn wound healing. *Int Wound J* 8:343-54.
- Elfahmi, Woerdenbag HJ and Kayser O, 2014. Jamu: Indonesian traditional herbal medicine towards rational phytopharmacological use. *J Herbal Med* 4:51-73.
- El-Ferjani RM, Ahmad M, Dhiyaaldeen SM, *et al.*, 2016. In vivo assessment of antioxidant and wound healing improvement of a new Schiff base derived Co (II) complex in rats. *Sci Reports* 6:38748.
- Gonzalez ACO, Costa TF, Andrade ZA, *et al.*, 2016. Wound healing - A literature review. *An Bras Dermatol* 91:614-20.
- Gorouhi F, Shah NM, Krishna RV, *et al.*, 2014. Epidermal growth factor-functionalized polymeric multilayer films: interplay between spatial location and bioavailability of EGF. *J Invest Dermatol* 134:1757-60.
- Gutierrez-Orozco F and Failla ML, 2013. Biological activities and bioavailability of mangosteen xanthenes: a critical review of the current evidence. *Nutrients* 5:3163-83.
- Hashimoto K, Higashiyama S, Asada H, *et al.*, 1994. Heparin-binding epidermal growth factor-like growth factor is an autocrine growth factor for human keratinocytes. *J Biol Chem* 269:20060-6.
- Ibrahim MY, Mariod AA, Mohan S, *et al.*, 2016. Review: Alpha Mangostin from *Garcinia mangostana* Linn: an update review of its pharmacological properties. *Arabian J Chem* 9:1-39.
- Inoue M, Ono I, Tateshita T, *et al.*, 1998. Effect of a collagen matrix containing epidermal growth factor on wound contraction. *Wound Repair Regen* 6:213-22.
- Kurniawati A, Roedhy PI, Sobiri I, Darda EI, and Herry C, 2010. Evaluation of fruit characters, xanthenes content, and antioxidant properties of various qualities of mangosteens (*Garcinia mangostana* L.). *Indonesian J Agron* 38 : 232 – 237.
- Kwon YB, Kim HW, Roh DH, *et al.*, 2006. Topical application of epidermal growth factor accelerates wound healing by myofibroblast proliferation and collagen synthesis in rat. *J Vet Sci* 7:105-9.
- Mitsunaga JJK, Gragnani A, Ramos ML, *et al.*, 2012. Rat an experimental model for burns: a systematic review. *Acta Cir Bras* 27:417-23.
- Pandurangan A, Khosa RL and Hemalatha S, 2010. Evaluation of wound healing activity of *Lchnocarpus frutescens* root. *Der Pharmacia Lettre* 2:444-9.
- Pedrazachaverri J, Reyesfermín LM, Nolascoamaya EG, *et al.*, 2009. ROS scavenging capacity and neuroprotective effect of alpha-MG against 3-nitropropionic acid in cerebellar granule neurons. *J Experim Toxicol Pathol* 61:491-501.
- Phuong NTM, Quang NV and Mai TT, 2017. Antibiofilm activity of α -mangostin extracted from *Garcinia mangostana* L. against *Staphylococcus aureus*. *Asian Pacific J Trop Med* 10:1154-60.
- Shen C, Sun L, Zhu N, *et al.*, 2017. Kindlin-1 contributes to EGF-induced re-epithelization in skin wound healing. *Int J Mol Med* 39:949-59.
- Sivaranjani M, Prakash M and Gowrishankar S, 2017. In vitro activity of alpha-mangostin in killing and eradicating *Staphylococcus epidermidis*, RP62A biofilms. *J Appl Microbiol Biotechnol* 101:3349-59.
- Steed DL, 1998. Modifying the wound healing response with exogenous growth factors. *Clin Plastic Surg* 25:397-405.
- Stoll SW, Rittié L, Johnson JL, *et al.*, 2012. Heparin-binding EGF-like growth factor promotes epithelial-mesenchymal transition in human keratinocytes. *J Invest Dermatol* 132:2148-57.
- Suruse P, Kale MK, Gunde M, *et al.*, 2011. Evaluation of wound healing activity of *Arisaema leschenaultii* blume in rats. *Der Pharmacia Lettre* 3:200-6.
- Svensjo T, Yao F, Pomahac B, *et al.*, 2002. Cultured autologous fibroblasts augment epidermal repair. *Transplantation* 73:1033-41.
- Wenczak BA, Lynch JB and Nanney, 1992. Epidermal growth factor receptor distribution in burn wounds. Implications for growth factor-mediated repair. *J Clin Invest* 90:2392-401.
- Wong VW, Sorkin M, Glotzbach JP, *et al.*, 2011. Surgical approaches to create murine models of human wound healing. *J Biomed Biotechnol* 969618. doi: 10.1155/2011/969618.
- Waheed M, Muhammad F, Javed I *et al.*, 2015. Dermatoprotective effects of some plant extracts (genus *Ficus*) against experimentally induced toxicological insults in rabbits. *Toxicol Ind Health* 31:982-990.
- Yoshimura M, Ninomiya K, Tagashira Y, *et al.*, 2015. Polyphenolic constituents of the pericarp of mangosteen (*Garcinia mangostana* L.). *J Agric Food Chem* 63:7670-4.
- Zhang S and Uludag H, 2009. Nanoparticulate systems for growth factor delivery. *Pharmac Res* 26:1561-80.

**LEMBAR HASIL PENILAIAN
SEJAWAT SEBIDANG atau PEER REVIEW**

KARYA ILMIAH : JURNAL ILMIAH

Judul Karya Ilmiah (Artikel) : *Garcinia Mangostana* Extract Enhances Skin Epithelialization in Rat Induced Burn Injury

Jumlah Penulis : 12 orang

Nama-nama Penulis : Marisca Evalina Gondokesumo, Bambang Pardjianto, Kusworini Handono, Sutiman Bambang Sumitro, **Wahyu Widowati**, Okta Wismandanu, Tyagita Hartady, Aziiz Mardanarian Rosdianto Hanna Goenawan, Ronny Lesmana, Nasrul Wathoni, and Unang Supratman

Status Penulis : ~~Penulis Pertama~~ / Penulis ke 5 / ~~Penulis Korespondensi~~ **)

Identitas Jurnal Ilmiah :

- a. Nama jurnal : Paskitan Verterinary Journal
- b. Nomor ISSN : 0253-8318, 2074-7764
- c. Vol., No., Bulan, Tahun : Vol. 39, No. 3 Nov 2019
- d. Penerbit : Faculty of Veterinary Science, University of Agriculture
- e. DOI Artikel (jika ada) : 10.29261/pakvetj/2019.059
- f. Alamat Web Jurnal : <http://www.pvj.com.pk/>
- g. Terindeks di : Scopus Q2, SJR 0.281

Kategori Publikasi Jurnal Ilmiah: ~~Jurnal Ilmiah Internasional~~ / Internasional Bereputasi **)

(beri tanda \checkmark yang dipilih)

Jurnal Ilmiah Nasional Terakreditasi

Jurnal Ilmiah Nasional / Nasional terindeks ***)

HASIL PENILAIAN (Peer Review) :

No	Komponen Yang Dinilai	Nilai Maksimal JURNAL ILMIAH			Nilai Akhir Yang Diperoleh *)
		Internasional / Bereputasi	Nasional Terakreditasi	Nasional ***)	
		<input checked="" type="checkbox"/>	<input type="checkbox"/>	<input type="checkbox"/>	
a.	Kelengkapan unsur isi karya (10%)	4			3,6
b.	Ruang lingkup dan kedalaman pembahasan (30%)	12			11,5
c.	Kecukupan dan kemutakhiran data/ informasi dan metodologi (30%)	12			11,7
d.	Kelengkapan unsur dan kualitas penerbitan (30%)	12			11,8
	Total	100%	40		38,6

Catatan Penilaian ARTIKEL oleh Reviewer :


a. Kelengkapan dan kesesuaian unsur.....
*Paper ditulis dengan baik, unsur lengkap, hasil sesuai judul penelitian, runtun mengi-
 kahi kaidah penulisan karya ilmiah internasional bereputasi*

b. Ruang lingkup & kedalaman pembahasan.....
*Data penelitian memadai tentang potensi ekstrak
 kulit Manggis meningkatkan epitelisasi kulit, ekspresi EGF metode IHC, pada
 tikus model burn injury*

c. Kecukupan & kemutakhiran data serta metodologi.....

Sumber pustaka mutakhir, hasil penelitian membahas metode hewan buru injury
pengamatan pada hari 0,7,14
d. Kelengkapan unsur dan kualitas penerbit
Park Vet J terindeks Scopus Q2 STAR 0,28. Penerbit Faculty of Veterinary Science,
University of Agriculture
e. Indikasi plagiasi
Similarity index 10%
tidak terdapat indikasi plagiarisme atau self-plagiarisme
f. Kesesuaian bidang ilmu
Paper bidang biomedik sesuai dengan bidang ilmu penulis.

REVIEWER 1



(Prof. Dr. Chrismis Novalinda Ginting, M.Kes)
NIK : 0115127801
UNIVERSITAS PRIMA INDONESIA

LEMBAR HASIL PENILAIAN
SEJAWAT SEBIDANG atau PEER REVIEW

KARYA ILMIAH : JURNAL ILMIAH

Judul Karya Ilmiah (Artikel) : Garcinia Mangostana Extract Enhances Skin Epithelialization in Rat Induced Burn Injury

Jumlah Penulis : 12 orang

Nama-nama Penulis : Marisca Evalina Gondokesumo, Bambang Pardjianto, Kusworini Handono, Sutiman Bambang Sumitro, **Wahyu Widowati**, Okta Wismandanu, Tyagita Hartady, Aziiz Mardanarian Rosdianto Hanna Goenawan, Ronny Lesmana, Nasrul Wathoni, and Unang Supratman

Status Penulis : ~~Penulis Pertama~~ / Penulis ke 5 / ~~Penulis Korespondensi~~ **)

Identitas Jurnal Ilmiah : a. Nama jurnal : Paskitan Verterinary Journal
 b. Nomor ISSN : 0253-8318, 2074-7764
 c. Vol., No., Bulan, Tahun : Vol. 39, No. 3 Nov 2019
 d. Penerbit : Faculty of Veterinary Science, University of Agriculture
 e. DOI Artikel (jika ada) : 10.29261/pakvetj/2019.059
 f. Alamat Web Jurnal : <http://www.pvj.com.pk/>
 g. Terindeks di : Scopus Q2, SJR 0.281

Kategori Publikasi Jurnal Ilmiah: Jurnal Ilmiah Internasional / Internasional Bereputasi **)
 (beri tanda \checkmark yang dipilih)

Jurnal Ilmiah Nasional Terakreditasi

Jurnal Ilmiah Nasional / Nasional terindeks ***)

HASIL PENILAIAN (Peer Review) :

No	Komponen Yang Dinilai	Nilai Maksimal JURNAL ILMIAH			Nilai Akhir Yang Diperoleh *)
		Internasional / Bereputasi	Nasional Terakreditasi	Nasional ***)	
		<input checked="" type="checkbox"/>	<input type="checkbox"/>	<input type="checkbox"/>	
a.	Kelengkapan unsur isi karya (10%)	4			3,8
b.	Ruang lingkup dan kedalaman pembahasan (30%)	12			11,5
c.	Kecukupan dan kemitakhiran data/informasi dan metodologi (30%)	12			11,8
d.	Kelengkapan unsur dan kualitas penerbitan (30%)	12			11,5
	Total	40			38,6

Catatan Penilaian ARTIKEL oleh Reviewer :

- a. Kelengkapan dan kesesuaian unsur.....
Kelengkapan unsur isi artikel sudah cukup lengkap dan terdapat kesesuaian antara unsur dan isinya.
- b. Ruang lingkup & kedalaman pembahasan.....
Ruang lingkup bahasan sudah memadai dan terdapat kedalaman antara data pembahasan
- c. Kecukupan & kemitakhiran data serta metodologi.....

secara umum metodologi sudah memadai dan lengkap, kemutakhiran data juga sudah terpenuhi

d. Kelengkapan unsur dan kualitas penerbit

Kualitas penerbit sudah memenuhi kaidah dan kualitas jurnal masuk kategori bereputasi yang baik

e. Indikasi plagiasi

Belum terdapat adanya unsur atau indikasi plagiasi sejauh ini

f. Kesesuaian bidang ilmu

Jurnal ini sudah sesuai dengan bidang ilmu yang diteliti

REVIEWER 2



(Prof. Dr. Ermi Girsang, M. Kes)

NIK : 0117057501

UNIVERSITAS PRIMA INDONESIA

LEMBAR HASIL PENILAIAN
SEJAWAT SEBIDANG atau *PEER REVIEW*

KARYA ILMIAH : JURNAL ILMIAH

Judul Karya Ilmiah (Artikel) : *Garcinia Mangostana Extract Enhances Skin Epithelialization in Rat Induced Burn Injury*

Jumlah Penulis : 12 orang

Nama-nama Penulis : Marisca Evalina Gondokesumo, Bambang Pardjianto, Kusworini Handono, Sutiman Bambang Sumitro, **Wahyu Widowati**, Okta Wismandanu, Tyagita Hartady, Aziiz Mardanarian Rosdianto Hanna Goenawan, Ronny Lesmana, Nasrul Wathoni, and Unang Supratman

Status Penulis : ~~Penulis Pertama~~ / Penulis ke 5 / ~~Penulis Korespondensi~~ **)

Identitas Jurnal Ilmiah : a. Nama jurnal : Paskitan Verterinary Journal
 b. Nomor ISSN : 0253-8318, 2074-7764
 c. Vol., No., Bulan, Tahun : Vol. 39, No. 3 Nov 2019
 d. Penerbit : Faculty of Veterinary Science, University of Agriculture
 e. DOI Artikel (jika ada) : 10.29261/pakvetj/2019.059
 f. Alamat Web Jurnal : <http://www.pvj.com.pk/>
 g. Terindeks di : Scopus Q2, SJR 0.281

Kategori Publikasi Jurnal Ilmiah: ~~Jurnal Ilmiah Internasional~~ / Internasional Bereputasi **) (beri tanda yang dipilih)

Jurnal Ilmiah Nasional Terakreditasi

Jurnal Ilmiah Nasional / Nasional terindeks ***)

HASIL PENILAIAN (*Peer Review*) :

No	Komponen Yang Dinilai	Nilai Maksimal JURNAL ILMIAH			Nilai Akhir Yang Diperoleh *)
		Internasional / Bereputasi <input checked="" type="checkbox"/>	Nasional Terakreditasi <input type="checkbox"/>	Nasional ***) <input type="checkbox"/>	
a.	Kelengkapan unsur isi karya (10%)	4			3,7
b.	Ruang lingkup dan kedalaman pembahasan (30%)	12			11,5
c.	Kecukupan dan kemutakhiran data/informasi dan metodologi (30%)	12			11,75
d.	Kelengkapan unsur dan kualitas penerbitan (30%)	12			11,65
	Total	40			38,6

Catatan Penilaian ARTIKEL oleh Reviewer :

- a. Kelengkapan dan kesesuaian unsur.....
 Paper ditulis dengan baik, unsur lengkap, hasil sesuai judul penelitian, runtun mengikuti kaidah penulisan karya ilmiah internasional bereputasi
-
 kelengkapan unsur isi artikel sudah cukup lengkap dan terdapat kesesuaian antara unsur dan ilimya
- b. Ruang lingkup & kedalaman pembahasan

bata penelitian memadai tentang potensi ekstrak kulit manggis meningkatkan epitelisasi kulit, ekspresi EGF metode IHC, pada tikus Model burn injury.

Ruang lingkup bahasan sudah memadai dan terdapat kedalaman antara analisa data dan pembahasan

c. Kecukupan & kemitakhiran data serta metodologi

Sumber pustaka mutakhir, hasil penelitian membahas metode hewan burn injury pengamatan pada hari 0, 7, 14

Secara umum metodologi sudah memadai dan lengkap, kemitakhiran data juga sudah terpenuhi

d. Kelengkapan unsur dan kualitas penerbit

Part. Vet. J, terindeks Scopus Q2 SJR 0,28. Penerbit Faculty of Veterinary Science, University of Agriculture.

Kualitas penerbit sudah memenuhi kaidah dan kualitas jurnal masuk kategori bereputasi yang baik

e. Indikasi plagiasi

Similarity index 10%. Tidak terdapat indikasi plagiarisme atau self-plagiarisme

Belum terdapat adanya unsur atau indikasi plagiasi sejauh ini

f. Kesesuaian bidang ilmu

Paper bidang biomedik sesuai dengan bidang ilmu penulis.

Jurnal ini sudah selesai dengan bidang ilmu yang diteliti

Medan,
Reviewer 2

(Prof. Dr. Ermi Girsang, M.Kes)

NIK : 0117057501

UNIVERSITAS PRIMA INDONESIA

Medan,
Reviewer 1

(Prof. Dr. Chrismis Novalinda Ginting, M.Kes)

NIK : 0115127801

UNIVERSITAS PRIMA INDONESIA