

1. Oral Mucosa Wound Healing Activities of Aloe vera Extract: in vivo Study

by Vinna K. Sugiaman, Natallia Pranata, Silvi Kintawati, Ani M. Maskoen,
Andri Rezano

Submission date: 10-Mar-2020 05:03AM (UTC+0700)

Submission ID: 1272545003

File name: 1._Oral_Mucosa.pdf (560.91K)

Word count: 3420

Character count: 18751

Oral Mucosa Wound Healing Activities of *Aloe vera* Extract: *in vivo* Study

Vinna K. Sugiawan^{1,2*}, Natallia Pranata^{2,3}, Silvi Kintawati⁴, Ani M. Maskoen^{2,4}, Andri Rezano^{2,5}

1. Department of Oral Biology, Faculty of Dentistry, Maranatha Christian University, Bandung, Indonesia.
2. Graduate School of Biomedical Sciences, Master Program, Faculty of Medicine, Universitas Padjadjaran, Bandung, Indonesia.
3. Department of Oral Pathology, Faculty of Dentistry, Maranatha Christian University, Bandung, Indonesia.
4. Department of Oral Biology, Faculty of Dentistry, Universitas Padjadjaran, Bandung, Indonesia.
5. Department of Anatomy, Physiology and Cell Biology, Faculty of Medicine, Universitas Padjadjaran, Bandung, Indonesia.

Abstract

Aloe vera L. (Liliaceae) in culture has been used for herbal medicine is also known as the healing plant. Wound healing property of *Aloe vera* on the skin has been proven. In contrast, the healing of oral mucosa is slightly different from the skin. Fibroblast in oral mucosa phenotypically resemble fetal fibroblast.

This study will analyze the effect of *Aloe vera* on the healing process of wound in oral mucosa of 24 male Wistar rat. Expression of transforming growth factor (TGF) β 1 and inflammation effect was analyzed by immunohistochemistry (IHC) and hematoxylin-eosin (HE) staining. Purified (100% concentration) whole leaf extract of *Aloe vera* was topically applied twice daily, with dose 5 μ g/g bw. **Result:** TGF β 1 expression was significantly increased 20-30% at the third ($P=0.041$) and sixth day ($P=0.015$). There is no significant reduction of inflammatory cell either on the third ($P=0.699$) or sixth day ($P=1.0$).

This study shows that *Aloe vera* enhanced oral mucosa wound healing by TGF β 1 marker. There is no significant reduction of inflammatory cell.

Experimental article (J Int Dent Med Res 2018; 11(3): 878-883)

Keywords: Herbal medicine, Wound length, TGF β 1, Inflammatory cell.

Received date: 09 May 2018

Accept date: 07 August 2018

Introduction

Tooth extraction is one of the treatments that may cause injury. To restore the integrity of damaged tissue, effective wound healing requires the supply of material and nutrient.¹⁻³ Medicinal plant usually contains material and nutrient necessary to accelerate the process of wound healing. *Aloe vera* L. (Liliaceae) in culture has been widely used as an herbal medicine, specially to wound healing. The whole leaf extract of *Aloe vera* contains various component, generally classified into saccharide (such as polysaccharide, monosaccharide and glycoside), quinone (such as anthraquinone), mineral, protein (such as bradykinase), lipid, and supplementary substance.⁴⁻⁶ The use of *Aloe*

vera gel extract resulted in faster wound healing with rat and rabbit skin.^{1,7} This extract increased wound contraction and collagen synthesis, stimulated the macrophage and proliferation of fibroblast, and had an anti-inflammatory effect.^{8,9}

Study on skin wound healing in rat and rabbit reported that saccharide and anthraquinone are present in *Aloe vera*. Saccharide can accelerate the healing process involve skin contraction and collagen synthesis. It also show high expression of transforming growth factor (TGF) β 1 gene.^{7,9} TGF β 1 is multifunctional growth factor, that stimulates proliferation of fibroblast, differentiation of myofibroblast, and enhances the formation of extracellular matrix (ECM).^{7,10,11} Immediately after skin injury, TGF β 1 will leave from skin wound by induce platelet degranulation. TGF β 1 shows increased mitotic index in the study of human's skin fibroblast cell.⁹ Beside the saccharide, other important molecule in *Aloe vera* is anthraquinone. It have played an important role in inflammation by inhibiting the cyclooxygenase pathway and reduces prostaglandin E2 production.^{9,12}

In contrast, the healing of oral mucosa is slightly different from the skin. Fibroblast in oral

*Corresponding author:

Vinna K. Sugiawan
Department of Oral Biology, Faculty of Dentistry,
Maranatha Christian University,
Bandung, Indonesia
E-mail: vinnakurniawati@yahoo.co.id

mucosa phenotypically resemble fetal fibroblast.¹³ This study will analyze the effect of *Aloe vera* whole leaf extract on the healing process of oral mucosa wound, based on the expression of TGF β 1 and its effect on inflammation.

Materials and methods

This study was approved by animal care and experimentation committee, Faculty of Medicine Maranatha Christian University–Immanuel Hospital Bandung. An effort was made to minimize the number of animal used in this study. The rats were housed at the Animal Facility of Pharmacology Therapy and Clinic Laboratory, Faculty of Medicine, Universitas Padjadjaran Bandung, with food and water *ad libitum* under controlled temperature (24 ± 3 °C), 12 h light dark cycle (light on 06.00 am until 06.00 pm). Twenty-four male Wistar rats weighing 200-250 g by the age of 40-60 day were purchased from Faculty of Veterinary Medicine, Bogor Agricultural University. The rats were divided into four group (n = 6/group). Group one and two were given injuries without treatment of topical *Aloe vera*. Group three and four were given the injuries and *Aloe vera* topical treatment. All rat went under anesthesia with ketamine (10 mg/kg bw) intramuscularly and were cut along 3 mm on the mandibular labial gingiva. At the end of experimental period, three days for group one and two, six days for group two and four, rat was terminated by anesthesia and cervical dislocation.

The proper plant material was obtained in wet season (January) from botanical garden *Manoko Lembang, Balai Penelitian Tanaman Rempah dan Obat*, Indonesian Agency for Agricultural Research and Development (IAARD), Ministry of Agriculture in Bandung, West Java, Indonesia. It was identified by Dr. Ir. Nurliani Bermawie (Senior researcher in IAARD). Voucher number of the plant is K0100097. Whole leaf extract was prepared¹⁴ at the Pharmaceutical Natural Products Laboratory, Faculty of Pharmacy, Universitas Padjadjaran, Bandung.

This extract has effectiveness and safety even at high concentration used. LD₅₀ for this extract was > 50 mg/kgbw.¹⁵ In this study purified (100% concentration) *Aloe vera* extract was topically applied twice daily with dose 5 μ g/gbw. On the third day, immunohistochemically analyzed by specific antibody and hematoxylin-

eosin (HE) staining carried on group 1 and 3. Same procedure was also conducted at sixth day for group 2 and 4.

Immunohistochemical (IHC) staining of the mucosal tissue section was performed using anti-TGF β 1 with labeled streptavidin-biotin method (LSAB) that use the primary TGF β 1 (R & D System, Minneapolis, MN, USA), with the instruction of the kit LSAB-HRP System. Unstained tissue section was dewaxed and rehydrated in xylene and graded ethanol. The optimal protocol for TGF- β 1 immunohistochemistry was determined by testing primary antibody dilution and staining condition, which was conducted at Anatomic Pathology Laboratory, Hasan Sadikin General Hospital Bandung.

The staining for TGF- β 1 on mucosa tissue was evaluated by pathologist who was blinded to the experimental data. The immunoreacting level is determined by the distribution of cell that showed immunoreaction and immunohistochemically color intensity using a light microscope (Olympus CX21FS1, Tokyo, Japan) with a 400x magnification. The immunoreacting cell was described as rounded brown. Distribution of cell with positive immunoreacting was counted semi-quantitatively by scale 0 to 3;¹⁶ 1 (focal) if <20% of immunoreacting cell; 2 (heterogeneous) if 20 - 50% of immunoreacting cell; 3 (diffuse) if >50% immunoreacting cell.

The intensity of immunohistochemical staining was assessed by scale 0 to 3;¹⁶ 0 (negative) if no brown granular staining; 1 (weak) very smooth, light brown granular staining; 2 (moderate) medium brown granular staining; 3 (strong) dark brown granular staining.¹⁰

Mucosa tissue section (4-5 μ m) was deparaffinized and dehydrated using a graded series of ethanol solution and stained with hematoxylin-eosin as standard procedure in this condition. All section was observed and the pictures were photographed⁵ with a light microscope. The representative field within each section was randomly chosen and captured under a 100x magnification. The integrated optical density (IOD) in each image was measured with the same setting for all slides, and the density was calculated as IOD/total area of each image.

HE staining used to examine the effect of *Aloe vera* on inflammatory reaction during mucosa wound healing. The percentage of inflammatory cell scaled 0 to 3;¹⁷ 0 (negative) if no inflammatory

cell; 1 if <20% inflammatory cell; 2 if 20-50% inflammatory cell; 3 if >50% inflammatory cell.

Statistical comparison was performed using T-test and Mann-Whitney. The p value of less than 0.05 ($P < 0.05$) considered significant.

Results

Immunoexpressing level of TGF β 1, from group (1 and 2) without *Aloe vera* show average weak intensity and distribution, either on the third or sixth day. While the group (3 and 4) with *Aloe vera* strong intensity and distribution observed (Figure 1).

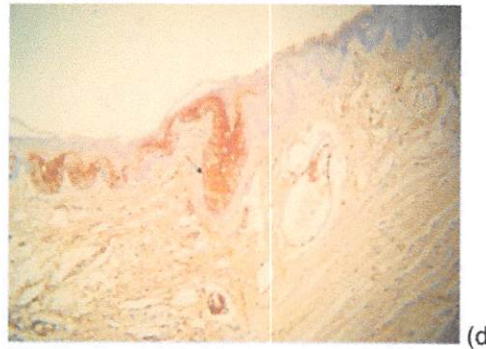
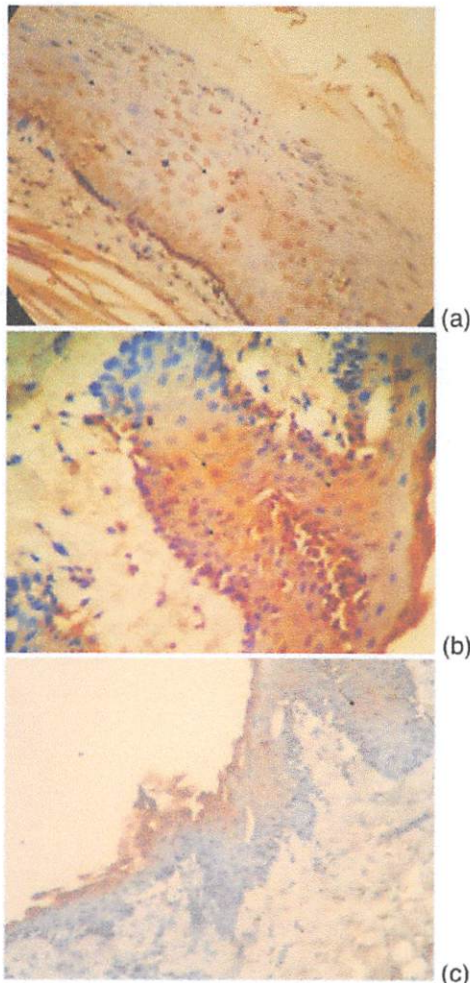


Figure 1. TGF β 1 expression observed using light microscope with 400x magnification. (a) Immunoreacted cell distribution (arrow) < 20% (1: focal) represent the untreated group (not received topical application of extract *Aloe vera*). (b) Immunoreacted cell distribution (arrow) > 50% (3: diffuse) represent the treated group (received topical application of *Aloe vera*). (c) Weak intensity (category 1) of brown granular staining represent the untreated group. (d) Strong intensity (category 3) of brown granular staining represent the treated group.

The intensity and distribution of TGF β 1 expression led significant increase 20-30% in the third ($P=0.022$) and sixth day ($P=0.015$). The comparison can be seen in the Table 1.

Expression TGF β 1	Treatment		P value
	without <i>Aloe vera</i> (n = 6/group)	<i>Aloe vera</i> (n = 6/group)	
Third day Intensity			
1 (weak)	4	0	
2 (medium)	2	3	
3 (strong)	0	3	
Distribution	Group 1	Group 3	0.041
1 (focal)	4	2	
2 (heterogeneous)	1	4	
3 (diffuse)	1	0	
Sixth day Intensity			
1 (weak)	4	0	
2 (medium)	1	1	
3 (strong)	1	5	
Distribution	Group 2	Group 4	0.015
1 (focal)	5	2	
2 (heterogeneous)	1	4	
3 (diffuse)	0	0	

Table 1. Intensity and Distribution of TGF β 1 Expression Immunoreacted Cell on the Third and Sixth Day. Note: Categorization of IHC staining intensity by scale 0 to 3; 0 (negative) if no brown granular staining; 1 (weak) very smooth, light brown granular staining; 2 (moderate) medium brown granular staining; 3 (strong) dark brown granular staining. Categorization of immunoreacted cell distribution by scale 0 to 3; 0 (negative) if no immunoreacted cell was found; 1 (focal) if < 20% of immunoreacted cell; 2 (heterogeneous) if 20-50% of immunoreacted cell; 3 (diffuse) if > 50% immunoreacted cell. In this experiment, no group was categorized as 0 (negative). TGF β 1 expression led to significant ($P < 0.05$) increase in

the value of $P=0.041$ on the third day and $P=0.015$ on the sixth day, which is confirmed by Mann-Whitney test.

There is no significant decrease in number of inflammatory cell between both of group treated and untreated of *Aloe vera* as showed by Mann-Whitney test ($P=0.699$ for 3rd-day; $P=1.0$ for 6th-day). The comparison can be seen in the Table 2.

HE staining show the number of inflammatory cell in the mucosa labial wound healing process under light microscope. Semi quantitatively analyze was done based on the percentage of inflammatory cell and are present (Figure 2).

Inflammatory cell (%)	Treatment		p value
	without Aloe vera (n = 6/group)	Aloe vera (n = 6/group)	
Third day			
1 (<20%)	3	4	0.099
2 (20-50%)	2	1	
3 (>50%)	1	1	
Sixth day			
1 (<20%)	3	3	1.0
2 (20-50%)	1	1	
3 (>50%)	2	2	

Table 2. Percentage of Inflammatory Cell on the Third and Sixth Day Both Group of Treatment.

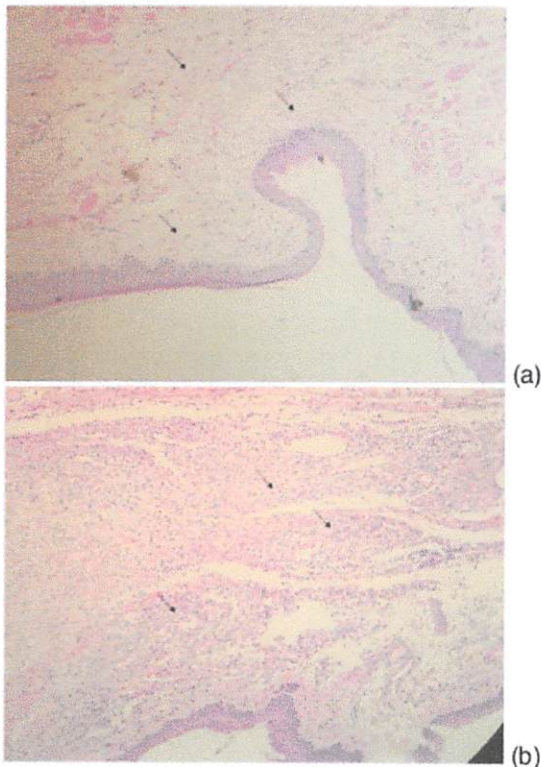


Figure 2. HE Staining for The Number of Inflammatory Cell (Numerous Round-Shaped

Cell) in the Mucosa Wound Healing Process Under Light Microscope With 100x Magnification. (a) Number of Inflammatory Cell (arrow) <20% (category 1). (b) Number of Inflammatory Cell (arrow) >50% (category 3).

Discussion

Aloe vera L. (Liliaceae), or its botanical name *Aloe barbadensis* Miller. This plant has thick leaves to survive on dry climate. The mucilaginous layer in the inner leaves is thought to be responsible for the majority of the plant's therapeutic property. This layer gel contains approximately 72% saccharide (such as polysaccharide, monosaccharide and glycoside), 16% mineral, 7% protein (such as bradykinase), 4% lipid, and 1% supplementary substance. Above this, a bitter yellow sap, contains phenolic compound, the anthraquinone. The therapeutic property of *Aloe vera* has been described as wound healing, anti-inflammatory, radiation damage repair, antibacterial, antiviral, antifungal, antidiabetic, antineoplastic, hematopoietic stimulation, and antioxidant.

Wound healing property of *Aloe vera* on the skin has been proven by many researchers. Topical application of *Aloe vera* extract showed significant effect on rat and rabbit skin. The wound length reduced due to increase skin contraction at the wound point, collagen synthesis, and fibroblast proliferation. The polysaccharide is responsible for the majority of the biological activity of this plant. The polysaccharide consist of linear chain of glucose and mannose molecule, in which acemannan and glucomannan are the form that have the most important function. This molecule plays an important role in several phase of wound healing. The three phase of wound healing are thrombosis and inflammation, proliferation and formation of new tissue, and remodeling or maturation phase.

One of the most important immune cell involved in the inflammation until the last phase wound healing is macrophage. Its level start to increase during the phase of inflammation, with the peak during the formation of granulation tissue and decline in the maturation phase.

Previous *in vitro* study reported that mannose molecule bind to mannose transmembrane receptor on the surface of macrophage and induce the intracellular

signaling pathway.^{7,18,19} This receptor contains N-terminal cysteine-rich domain, fibronectin type II domain, multiple C-type lectin-like domains (CTLDs), and C-terminal cytoplasmic domain. The CTLDs recognize polysaccharide chain ending with mannose, fucose, or N-acetylglucosamine.¹⁸ To confirm this interaction, future study required.

Macrophage, platelet, injured cell, fibroblast, and other cell involved in the wound healing coordinate with each other through cellular signaling by the help of various type of growth factor. Growth factor is protein with heavy molecular weight, which secretes and start autocrine and paracrine signaling in various cellular process. Growth factor that has a substantial role is TGF β .^{7,9} The major source that secreted this growth factor was macrophage. TGF β has three isoform, TGF β 1, β 2, and β 3.¹⁹ Between these isoform, high expressions of TGF β 1 is associated with scar less condition and enhance the wound contraction rate and ECM production *in vivo*. The expression level of TGF β 1 reflect the distribution of leukocyte or/and macrophage. In this study, we observed an immunoreacted against anti-TGF β 1 antibody (Figure 1a-b). TGF β 1 play a role in chemotaxis, fibroblast proliferation and collagen metabolism.⁹ This molecule will interact with growth factor receptor on the fibroblast, thereby stimulating its activity and proliferation. The fibroblast is one of the cell that play an important role in proliferative phase of wound healing, and fibroblast needed to maintain skin integrity.^{13,18}

In the early phase, *Aloe vera* serve as dressing that keeps wound moist.⁶ It was reported that *Aloe vera* increase collagen synthesis, changes collagen composition, enhance tensile strength and cause collagen cross-linking on damaged tissue.^{4,20} The mechanism of *Aloe vera* increasing collagen synthesis still require further study, as well as the effect of *Aloe vera* on growth factor.

Anthraquinone, phenolic compound of *Aloe vera* leaves, has strong anti-inflammatory effect.⁶ This effect is executed by inhibiting the cyclooxygenase pathway and reducing prostaglandin E2. Other molecule that have anti-inflammatory is C-glycosyl chromone extract (glycoside) and bradykinase (peptidase). Bradykinase is shown to break down the bradykinin, an inflammatory substance that induces pain.⁵ In this study, the anti-inflammatory

effect of *Aloe vera* was observed by detecting the presence of inflammatory cell (Figure 2a-b). The percentage of inflammatory cell did not show a significant reduction (Table 3). This may be caused due the examination being held on the third and sixth day which is still in the inflammatory phase. The most prominent inflammatory cell within three to five days is macrophage. Reduction of macrophage during these phase will cause delay of wound healing in a mouse and rabbit model.^{1,7,19} More study still required to prove the anti-inflammatory effect of this plant, by increasing the treatment time and modification of research method.

Conclusions

Aloe vera enhanced oral mucosa wound healing, significantly increased of TGF β 1 expression and no significant reduction of inflammatory cell.

Acknowledgements

We would like thank to Hj. Bethy Suryawathy Hernowo, M.D., Sp.PA(K), Ph.D. for pathological analysis and Dr. Ir. Nurliani Bermawie for *Aloe vera* identification. This work was supported by Maranatha Christian University Scholarship and Universitas Padjadjaran publication grant based on a thesis submitted to the Graduate School of Biomedical Sciences Master Program, Faculty of Medicine, Universitas Padjadjaran, in partial fulfillment of the requirements for the M.S. degree.

Declaration of Interest

The authors report no conflict of interest and the article is not funded or supported by any research grant.

References

1. Subramanian S, Sathish Kumar D, Arulselvan P. Wound healing potential of Aloe vera leaf gel studied in experimental rabbits. *Asian J Biochem*. 2006;1(2):178-185.
2. Moghbel A, Ghalambor A, Allipanah S. Wound healing and toxicity evaluation of Aloe vera cream on outpatients with second degree burns. *Iran J Pharm Sci*. 2007;3(3):157-160.
3. Gala-García A, Teixeira KIR, Mendes LL, Sobrinho APR, Santos VR, Cortes ME. Effect of Aloe vera on rat pulp tissue. *Pharm Biol*. 2008;46(5):302-308.
4. Surjushe A, Vasani R, Saple DG. Aloe vera: A short review. *Indian J Dermatol*. 2008;53(4):163-166.

5. Gupta V, Malhotra S. Pharmacological attribute of Aloe vera: Revalidation through experimental and clinical studies. *AYU*. 2012;33(2):193-196.
6. Rahman S, Carter P, Bhattarai N. Aloe vera for tissue engineering applications. *J Funct Biomat*. 2017;8(1):6-23.
7. Atiba A, Ueno H, Uzuka Y. The effect of Aloe vera oral administration on cutaneous wound healing in type 2 diabetic rats. *J Vet Med Sci*. 2011;73(5):583-589.
8. Radha MH, Laxmipriya NP. Evaluation of biological properties and clinical effectiveness of Aloe vera: A systematic review. *J Tradit Complement Med*. 2015;5(1):21-26.
9. Hashemi SA, Madani SA, Abediankenari S. The review on properties of Aloe vera in healing of cutaneous wounds. *BioMed Res Int*. 2015;2015:1-6.
10. Li MO, Flavell RA. TGF- β : a master of all T cell trades. *Cell*. 2008;134(3):392-404.
11. Moustakas A, Heldin C-H. Mechanisms of TGF β -induced epithelial-mesenchymal transition. *J Clin Med*. 2016;5(7):63-97.
12. Zhou Y-X, Xia W, Yue W, Peng C, Rahman K, Zhang H. Rhein: A review of pharmacological activities. *Evidence-Based Complement Altern Med*. 2015;2015:1-10.
13. Nanci A. *Oral Histology: Development, Structure, and Function*. 8th ed. Elsevier, Mosby Canada. 2012.
14. Wozniak A, Paduch R. Aloe vera extract activity on human corneal cells. *Pharmaceutical Biology*. 2012;50(2):147-154.
15. American College of Toxicology. Final report on the safety assessment of Aloe andongensis extract, Aloe andongensis leaf juice, Aloe arborescens leaf extract, Aloe arborescens leaf juice, Aloe arborescens leaf protoplasts, Aloe barbadensis flower extract, Aloe barbadensis leaf, Aloe barbadensis leaf extract, Aloe barbadensis leaf juice, Aloe barbadensis leaf polysaccharides, Aloe barbadensis leaf water, Aloe ferox leaf extract, Aloe ferox leaf juice, and Aloe ferox leaf juice extract. *Int J Toxicol*. 2007;26(2_suppl):1-50.
16. Fedchenko N, Reifenrath J. Different approaches for interpretation and reporting of immunohistochemistry analysis results in the bone tissue: A review. *Diagn Pathol*. 2014;9(1):221-233.
17. Erben U, Loddenkemper C, Doerfel K, et al. A guide to histomorphological evaluation of intestinal inflammation in mouse models. *Int J Clin Exp Pathol*. 2014;7(8):4557-4576.
18. Jettanacheawchankit S, Sasithanasate S, Sangvanich P, Banlunara W, Thunyakitpisal P. Acemannan stimulates gingival fibroblast proliferation; expressions of keratinocyte growth factor-1, vascular endothelial growth factor, and type I collagen; and wound healing. *J Pharmacol Sci*. 2009;109(4):525-531.
19. Delavary BM, van der Veer WM, van Egmond M, Niessen FB, Beelen RHJ. Macrophages in skin injury and repair. *Immunobiology*. 2011;216(7):753-762.
20. Anjani E, Khoswanto C. The use of 90% Aloe vera freeze drying as the modulator of collagen density in extraction socket of incisivus *Cavia cobaya*. *Dental Journal (Majalah Kedokteran Gigi)*. 2008;41(2):74-76.

1. Oral Mucosa Wound Healing Activities of Aloe vera Extract: in vivo Study

ORIGINALITY REPORT

22%

SIMILARITY INDEX

14%

INTERNET SOURCES

10%

PUBLICATIONS

17%

STUDENT PAPERS

PRIMARY SOURCES

- | | | |
|----------|---|-----------|
| 1 | repository.unair.ac.id
Internet Source | 4% |
| 2 | Submitted to Misr International University
Student Paper | 2% |
| 3 | www.mdpi.com
Internet Source | 2% |
| 4 | Jettanacheawchankit, Suwimon, Siriruk Sasithanasate, Polkit Sangvanich, Wijit Banlunara, and Pasutha Thunyakitpisal. "Acemannan Stimulates Gingival Fibroblast Proliferation; Expressions of Keratinocyte Growth Factor-1, Vascular Endothelial Growth Factor, and Type I Collagen; and Wound Healing", Journal of Pharmacological Sciences, 2009.
Publication | 2% |
| 5 | Yanping Yang, Jieqiong Zhao, Juan Zhang, Yonghong Lei et al. "Regulation of macrophage migration in ischemic mouse hearts via an | 1% |

AKT2/NBA1/SPK1 pathway", Oncotarget, 2017

Publication

6	www.jidmr.com Internet Source	1%
7	Submitted to iGroup Student Paper	1%
8	www.hindawi.com Internet Source	1%
9	ATIBA, Ayman, Hiroshi UENO, and Yuji UZUKA. "The Effect of Aloe Vera Oral Administration on Cutaneous Wound Healing in Type 2 Diabetic Rats", Journal of Veterinary Medical Science, 2011. Publication	1%
10	www.impactjournals.com Internet Source	1%
11	Submitted to Teerthanker Mahaveer University Student Paper	1%
12	www.eurekaselect.com Internet Source	1%
13	Seyyed Abbas Hashemi, Seyyed Abdollah Madani, Saied Abediankenari. "The Review on Properties of Aloe Vera in Healing of Cutaneous Wounds", BioMed Research International, 2015 Publication	1%

14	Submitted to International Medical University Student Paper	<1%
15	www.ektodermaldisplazi.com Internet Source	<1%
16	link.springer.com Internet Source	<1%
17	quintaisimortais.blogspot.com Internet Source	<1%
18	Submitted to Georgia Highlands College Student Paper	<1%
19	journal.unair.ac.id Internet Source	<1%
20	Submitted to Christian University of Maranatha Student Paper	<1%
21	Submitted to Universitas Indonesia Student Paper	<1%
22	Submitted to London School of Hygiene and Tropical Medicine Student Paper	<1%
23	Titipong Prueksrisakul, Soranun Chantarangsu, Pasutha Thunyakitpisal. "Effect of daily drinking of Aloe vera gel extract on plasma total antioxidant capacity and oral pathogenic bacteria in healthy volunteer: a short-term	<1%

study", Journal of Complementary and Integrative Medicine, 2015

Publication

24

Submitted to Universiti Malaysia Pahang

Student Paper

<1%

Exclude quotes Off

Exclude matches Off

Exclude bibliography On