
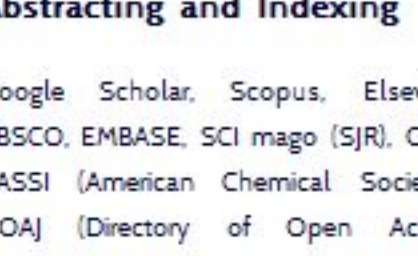































































<div><p>Impact (Cites per doc)- 0.48 (SCImago, SJR 2015)- For details visit www.scimagojr.com and see option Journal Search</p><p>ICV (2013)- 5.28</p><p>Abstracting and Indexing</p><p>Google Scholar, Scopus, Elsevier, EBSCO, EMBASE, SCImago (SJR), CAS, CASSI (American Chemical Society), DOAJ (Directory of Open Access Journal), Index Copernicus, ICAAP (International Consortium for the Advancement of Academic Publication), Open-J-Gate, Socolar.</p><div><div>Search Content</div><div><input type="text"/></div><div>Search</div></div></div>	<div><div>Vol 9 Issue 5 September 2016</div><div>TABLE OF CONTENTS</div><div>Case Study(s)</div><div><div>CEFUROXIME -INDUCED THROMBOCYTOPENIA: ITS JUST NOT THE RING??</div><div>Dr Balaji Ommurugan, Dr. Navin Patil, Dr Arnod Tilak, Dr Avinash A</div><div>Abstract View UNTITLED View PDF  Download PDF [0 Downloads]</div><div>0 Views</div></div><div>Review Article(s)</div><div><div>INFLUENCE OF LOVASTATIN ON PHARMACOKINETICS AND PHARMACODYNAMICS OF GLIPIZIDE IN HEALTHY AND STZ - INDUCED DIABETIC RATS: INVOLVEMENT OF P-GLYCOPROTEIN INHIBITION</div><div>KISHORE KUMAR KADIMPATI, Vanishree Sammeta, Ravindra Babu Pingili, Dr. Sujatha Sanneboina</div><div>Abstract View PDF  Download PDF [0 Downloads]</div><div>0 Views</div></div><div><div>NITRIC OXIDE MEDIATED NEURODEGENERATION IN PARKINSON'S DISEASE</div><div>Vaibhav Walia, Neeraj Gilhotra, Santilal Kansotia</div><div>Abstract View PDF  Download PDF [0 Downloads]</div><div>0 Views</div></div><div><div>MEDICAL MANAGEMENT OF DENTURE STOMATITIS</div><div>Shawna Rekshmy D'dharan</div><div>Abstract View PDF  Download PDF [0 Downloads]</div><div>0 Views</div></div><div><div>CANDIDATE GENES ASSOCIATED WITH POLYCYSTIC OVARY SYNDROME IN ASIAN POPULATIONS: A RESEARCH REVIEW</div><div>Abilash Vg</div><div>Abstract View PDF  Download PDF [0 Downloads]</div><div>0 Views</div></div><div><div>TERMINALIA CHEBULA: SUCCESS FROM BOTANY TO ALLOPATHIC AND AYURVEDIC PHARMACY</div><div>Varun Garg, Barinder Kaur, Sachin Kumar Singh, Birmlesh Kumar</div><div>Abstract View PDF  Download PDF [0 Downloads]</div><div>0 Views</div></div><div><div>GENOTOXIC EFFECT OF PESTICIDES ON HUMAN LEUKOCYTE CULTURE: A REVIEW/</div><div>Debanjana Mitra, Nishu Sekar, Sudhakaran Raja, Abilash Vg</div><div>Abstract View PDF  Download PDF [0 Downloads]</div><div>0 Views</div></div><div><div>GREEN SYNTHESIS AND CHARACTERIZATION OF SILVER NANOPARTICLES FROM WITHANIA SOMNIFERA (L) DUNAL</div><div>Prabhavathi Paulraj, Sankareswaran Muruganantham, Anbalagan S, Manikandan A, Karthikeyan G</div><div>Abstract View PDF  Download PDF [0 Downloads]</div><div>0 Views</div></div><div><div>NATURAL PSYCHODYSLEPTIC COMPOUNDS: SOURCES AND PHARMACOLOGY</div><div>Sisira Padavala, Ezhilarasan Devaraj</div><div>Abstract View PDF  Download PDF [0 Downloads]</div><div>0 Views</div></div><div>Original Article(s)</div><div><div>ANTIOXIDANT, ANTIINFLAMMATORY AND ANTIDIABETIC ACTIVITY OF HYDROALCOHOLIC EXTRACT OF OCIMUM SANTICUM: AN IN-VITRO AND IN-SILICO STUDY.</div><div>Udayabanu Malairaman</div><div>Abstract View PDF  Download PDF [0 Downloads]</div><div>0 Views</div></div><div><div>A FRAMEWORK FOR EVALUATION OF PHARMACEUTICAL INDUSTRY DEVELOPMENT IN DEVELOPING COUNTRIES: EVIDENCE FROM IRAN</div><div>Ebrahim Doostzadeh</div><div>Abstract View PDF  Download PDF [0 Downloads]</div><div>0 Views</div></div><div><div>ROASTED CASHEW NUT KERNEL (ANACARDIUM OCCIDENTALE L) SUPPLEMENTATION IMPROVES HEPATIC AND RENAL STATUS BUT NOT LIPID PROFILE IN RATS</div><div>Ademola Clement Famurewa</div><div>Abstract View PDF  Download PDF [0 Downloads]</div><div>0 Views</div></div><div><div>THE EFFECT OF CLIMATE ON TOTAL PHENOLICS IN MACROTYLOMA UNIFLORUM, VIGNA UNGUICULATA, CINNAMOMUM ZEYLANICUM AND MENTHA PIPERITA USING SPECTROPHOTOMETER</div><div>Vasundhara Saxena</div><div>Abstract View PDF  Download PDF [0 Downloads]</div><div>0 Views</div></div><div><div>AWARENESS, STRESS, ANXIETY AND DEPRESSION AMONG HYPERTENSIVE PATIENTS ATTENDING CARDIAC OPD IN SUPER SPECIALITY HOSPITAL.</div><div>Sushil Kumar Sharma</div><div>Abstract View PDF  Download PDF [0 Downloads]</div><div>0 Views</div></div><div><div>STUDY OF ANTIMICROBIAL, ANALGESIC AND ANTICONSULSANT ACTIVITY OF NOVEL ISATIN DERIVATIVES</div><div>Sravanthi Chirra</div><div>Abstract View PDF  Download PDF [0 Downloads]</div><div>0 Views</div></div><div><div>ANTIBACTERIAL ACTIVITY OF CHITOSAN AND HYDROLYZED COCONUT OIL AND THEIR COMBINATION AGAINST BACILLUS CEREUS AND ESCHERICHIA COLI</div><div>Jansen Silalahi</div><div>Abstract View PDF  Download PDF [0 Downloads]</div><div>0 Views</div></div><div><div>COMPARISON OF FENTANYL AND DEXMETETIMIDINE AS AN ADJUVANT TO BUPIVACAINE IN SUPRACLAVICULAR BRACHIAL PLEXUS BLOCKA RANDOMISED DOUBLE BLIND PROSPECTIVE STUDY</div><div>Swastika Swaro</div><div>Abstract View PDF  Download PDF [0 Downloads]</div><div>0 Views</div></div><div><div>ANTI-INFLAMMATORY STUDY OF ANREDERA CORDIFOLIA LEAVES AND CENTELLA ASIATICA HERBS AND ITS COMBINATIONS USING HRBC-MS METHOD</div><div>Entris Sutrisno</div><div>Abstract View PDF  Download PDF [0 Downloads]</div><div>0 Views</div></div><div><div>IN VITRO ANALYSIS OF ANTIMICROBIAL COMPOUNDS FROM ALSTONIA SCHOLARIS</div><div>Jayanthi Abraham</div><div>Abstract View PDF  Download PDF [0 Downloads]</div><div>0 Views</div></div><div><div>STUDY OF THE POSSIBLE ANTIHYPERTENSIVE AND HYPOLIPIDAEMIC EFFECTS OF A HERBAL MIXTURE ON L-NAME INDUCED HYPERTENSIVE RATS</div><div>Doha Aboubaker</div><div>Abstract View PDF  Download PDF [0 Downloads]</div><div>0 Views</div></div><div><div>ASSESSMENT OF EPILEPSY CLASSIFICATION USING TECHNIQUES SUCH AS SVD, APEN AND WEIGHTED KNN MEASURES</div><div>Sunil Kumar P</div><div>Abstract View PDF  Download PDF [0 Downloads]</div><div>0 Views</div></div><div><div>DRUG UTILISATION EVALUATION & COST ANALYSIS OF ANTI-EMETIC DRUGS PRESCRIBED IN ONCOLOGY WARD IN A QUATERNARY CARE HOSPITAL.</div><div>Ardesha A Nishita</div><div>Abstract View PDF  Download PDF [0 Downloads]</div><div>0 Views</div></div><div><div>CLINICO-PATHOLOGICAL CHARACTERISTICS OF LUPUS NEPHRITIS IN EASTERN ZONE OF INDIA: A SINGLE TERTIARY CENTRE EXPERIENCE.</div><div>Smaraka Ranjan Panda, Chittaranjan Kar, Prasant Kumar Sahu, Sashibhusan Rout, Bishwaranjan Mohanty, Tapas Ranjan Behera, Sudeshna Behera</div><div>Abstract View PDF  Download PDF [0 Downloads]</div><div>0 Views</div></div><div><div>FORMULATION AND EVALUATION OF GASTRORETENTIVE MICROBALLOONS OF ACEBROPHYLLINE FOR THE TREATMENT OF BRONCHIAL ASTHMA</div><div>Subramanian Manivannan</div><div>Abstract View PDF  Download PDF [0 Downloads]</div><div>0 Views</div></div><div><div>INTEND, DEPICTION IN-VITRO AND IN-VIVO APPRAISAL OF GLIPIZIDE FLOATING MICROSPHERES USING ETHYL CELLULOSE AND HPMS AS POLYMER BY SUBSTANTIALLY MODIFIED METHOD</div><div>Rishikesh Gupta</div><div>Abstract View PDF  Download PDF [0 Downloads]</div><div>0 Views</div></div><div><div>COSMETIC CONTAMINATION AWARENESS IN ADOLESCENT FEMALES</div><div>Ilankizhai Rj, Vishnupriya V, Gayathri R</div><div>Abstract View UNTITLED  Download PDF [0 Downloads]</div><div>0 Views</div></div><div><div>DOCKING STUDIES IN TARGET PROTEINS INVOLVED IN ANTIBACTERIAL ACTION MECHANISMS: ALKALOIDS ISOLATED FROM SCUTELLARIA GENUS</div><div>Sri Dharani R, Ranjitha R, Sripathi R, Ali Muhammad K S, Ravi S</div><div>Abstract View PDF  Download PDF [0 Downloads]</div><div>0 Views</div></div><div><div>EVOLVING TRENDS AND FUTURE PROSPECTS OF ADR MONITORING AND REPORTING: A LITERATURE REVIEW.</div><div>Aneela Amin, Madeeha Malik, Azhar Hussain</div><div>Abstract View PDF  Download PDF [0 Downloads]</div><div>0 Views</div></div><div><div>STUDY THE GROWTH KINETICS OF PEDIOCOCCUS ACIDILACTICI WITH ESTIMATION OF KINETIC PARAMETERS AND APPLIED IN LARGE SCALE PEDIOCIN PRODUCTION</div><div>Barnali Mandal</div><div>Abstract View PDF  Download PDF [0 Downloads]</div><div>0 Views</div></div><div><div>A PROSPECTIVE STUDY ON ABNORMAL LFT PATTERNS IN PATIENTS RECEIVING ANTITUBERCULOSIS THERAPY</div><div>Vijayalakshmi A</div><div>Abstract View PDF  Download PDF [0 Downloads]</div><div>0 Views</div></div><div><div>FORMULATION AND IN-VITRO EVALUATION OF TRANSDERMAL MATRIX PATCHES OF DOXOPHYLLINE</div><div>Sunny Jalhan</div><div>Abstract View PDF  Download PDF [0 Downloads]</div><div>0 Views</div></div><div><div>ANALGESIC ACTIVITY OF HYDROALCOHOLIC EXTRACT OF AERIAL PARTS OF MALVASTRUM COROMANDELIANUM</div><div>Bhupesh Chander Semwal</div><div>Abstract View PDF  Download PDF [0 Downloads]</div><div>0 Views</div></div><div><div>DELETERIOUS FUNCTIONAL IMPACT OF ANAEMIA ON ADOLESCENTS- A SURVEY STUDY</div><div>Karthigadevi I.</div><div>Abstract View PDF  Download PDF [0 Downloads]</div><div>0 Views</div></div><div><div>EFFECT OF PHARMACOLOGICAL DOSES OF GARLIC AND OMEGA3 ON GASTRIC LESIONS INDUCED BY ETHANOL IN MICE</div><div>Ausama Ayoob Jacob</div><div>Abstract View PDF  Download PDF [0 Downloads]</div><div>0 Views</div></div><div><div>ISOLATION OF BIOACTIVE COMPOUND OF MICHELIA CHAMPACA L. BARK AND ITS ACTIVITY TEST USING MECHANISM-BASED YEAST BIOASSAY</div><div>Ade Zuhrotun, Asep Gana Suganda, Komar Ruslan Virasutisna, Marlia Singgih Wibowo</div><div>Abstract View PDF  Download PDF [0 Downloads]</div><div>0 Views</div></div><div><div>ESTIMATION OF SERUM COPPER AND ZINC IN ANAEMIC PATIENTS</div><div>Aishwarya Swaminathan</div><div>Abstract View UNTITLED  Download PDF [0 Downloads]</div><div>0 Views</div></div><div><div>THE EFFECT OF KEFIR ON THE INFLAMMATORY STATUS AND THYROID FUNCTION (EXPERIMENTAL STUDY ON WISTAR RATS AFTER EXPOSED CHLORPYRIFOS)</div><div>Rasipin Rasipin</div><div>Abstract View PDF  Download PDF [0 Downloads]</div><div>0 Views</div></div><div><div>APOPTOTIC INDUCTION POTENTIALS OF BACOPA MONERI AGAINST ORAL</div><div>Keerthana Baskar</div><div>Abstract View PDF  Download PDF [0 Downloads]</div><div>0 Views</div></div><div><div>EFFECT OF GRAPE SEED EXTRACT ON REMINERALISATION OF ARTIFICIAL CARIES: AN IN-VITRO STUDY</div><div>Rubel M</div><div>Abstract View PDF  Download PDF [0 Downloads]</div><div>0 Views</div></div><div><div>ANALYTICAL METHOD DEVELOPMENT AND VALIDATION OF A RP-HPLC FOR THE DETERMINATION OF MODAFINIL IN BULK AND PHARMACEUTICAL DOSAGE FORMS</div><div>Bijithra Cholaraja</div><div>Abstract View PDF  Download PDF [0 Downloads]</div><div>0 Views</div></div><div><div>EXPLORATION OF PLANT BIOACTIVE FROM CASSIA FISTULA LEAVES FOR THE TREATMENT OF OVARIAN CANCER: AN INTEGRATIVE APPROACH</div><div>Ramanathan K, Shanthi V, Kanika Verma</div><div>Abstract View PDF  Download PDF [0 Downloads]</div><div>0 Views</div></div><div><div>INVITRO CYTOTOXIC STUDY AND GREEN SYNTHESIS OF GOLD AND SILVER NANO PARTICLES USING ECLIPTA PROSTRATA (L.)</div><div>Arvindganth Rajashekar, Vardhana Janakiraman, Kathiravan Govindarajan</div><div>Abstract View PDF  Download PDF [0 Downloads]</div><div>0 Views</div></div><div><div>PHARMACOGENETIC VARIATIONS RELATED TO CLOPIDOGREL RESISTANCE & ITS CLINICAL IMPLICATIONS: AN ISSUE WHICH REMAINS LARGELY UNADDRESSED</div><div>Dr Sabreen Bashir Bhat</div><div>Abstract View PDF  Download PDF [0 Downloads]</div><div>0 Views</div></div><div><div>SUBCHRONIC TOXICITY TEST OF COMBINATION ETHANOL EXTRACT OF DETAM 1 SOYBEAN (GLYCINE MAX L.MERR) AND JATI BELANDA (GUAZUMA ULMIFOLIA LAMM) TOWARDS FUNCTION, WEIGHT AND HISTOPATHOLOGICAL OF WISTAR RAT LIVER</div><div>Mellinah Hidayat, Sijani Prahastuti, Estherolita Dewi, Dewi Safitri, Siti Farah Rahmawati, Andreanus Andadja Soemardji</div><div>Abstract View PDF  Download PDF [0 Downloads]</div><div>0 Views</div></div><div><div>CHEMOTHERAPEUTIC EFFICACY OF TRIDHAM AND 1,2,3,4,6-PENTA-O-GALLOYL-B-D-GLUCOSE ON ANTIOXIDANTS STATUS AND TUMOUR MARKERS IN EXPERIMENTAL MAMMARY CARCINOMA IN SPRAGUE DAWLEY RATS</div><div>Karthick Dharmalingam</div><div>Abstract View PDF  Download PDF [0 Downloads]</div><div>0 Views</div></div><div><div>ANTIOSTEOPOROTIC ACTIVITY OF ANTHRAQUINONE ISOLATED FROM MORINDA CITRIFOLIA FRUITS IN RATS</div><div>Abin Joy</div><div>Abstract View PDF  Download PDF [0 Downloads]</div><div>0 Views</div></div><div><div>COMPARISON OF ANTIFUNGAL EFFECTS OF CANDIDIA ALBICANS IN HERBAL MOUTHWASHES AND CHLORHEXIDINE AGAINST CANDIDIA ALBICANS IN DIABETIC PATIENTS- AN INVITRO STUDY</div><div>Chandini Ravikumar</div><div>Abstract View PDF  Download PDF [0 Downloads]</div><div>0 Views</div></div><div><div>A STUDY ON PRESCRIBING PATTERN OF ANTIMICROBIAL AGENTS IN THE NEONATAL INTENSIVE CARE UNIT OF A TERTIARY CARE TEACHING HOSPITAL IN PUDUCHERRY, SOUTH INDIA.</div><div>Pandiamunian Jayabal, Kartik J Salwe, Somasundaram Ganesan, Bhanu Prakash Kolasani</div><div>Abstract View PDF  Download PDF [0 Downloads]</div><div>0 Views</div></div><div><div>EFFECTS OF IN VITRO 1,25 DIHYDROVITAMIN D ON MATURATION OF DENDRITIC CELLS IN GRAVES' DISEASE PATIENTS</div><div>Dyah Purnamasari, Samsuridjal Djauzi, Siti Setiati, Alida Harahap, Tjokorda Gde Dalem Pemasun, Joedo Prihartono, Pradana Soewondo</div><div>Abstract View PDF  Download PDF [0 Downloads]</div><div>0 Views</div></div><div><div>EVALUATION OF XPERT MTB/RIF ASSAY IN TB DIAGNOSTICS</div><div>Sevitha Bhat</div><div>Abstract View PDF  Download PDF [0 Downloads]</div><div>0 Views</div></div><div><div>FORMULATION AND STATISTICAL OPTIMIZATION OF BILAYER SUBLINGUAL TABLETS OF LEVOCETIZINE HYDROCHLORIDE AND AMBROXOL HYDROCHLORIDE</div><div>Priyanka Choudhury</div><div>Abstract View PDF  Download PDF [0 Downloads]</div><div>0 Views</div></div><div><div>MIDDLE EAR AND NASOPHARYNGEAL BACTERIAL FLORA AND THEIR SENSITIVITY IN ACTIVE STAGE OF MUCOSAL DISEASE CHRONIC SUPPURATIVE OTITIS MEDIA: A COMPARISON</div><div>Rakesh Vuppala</div><div>Abstract View PDF  Download PDF [0 Downloads]</div><div>0 Views</div></div><div><div>COMPARATIVE ANALYSIS OF ANTIOXIDANT ACTIVITY AND PHYTOCHEMICAL CONTENTS IN ETHANOLIC LEAF EXTRACTS OF IN VITRO AND FIELD GROWN WITHANIA SOMNIFERA</div><div>Prabhjot Singh Jassal</div><div>Abstract View PDF  Download PDF [0 Downloads]</div><div>0 Views</div></div><div><div>INTRATHECAL CLONIDINE AND FENTANYL WITH HYPERBARIC BUPIVACAINE IN SPINAL ANAESTHESIA FOR VAGINAL HYSTERECTOMY</div><div>Suman Chattopadhyay, Mallika Datta, Biswanath Biswas</div><div>Abstract View PDF  Download PDF [0 Downloads]</div><div>0 Views</div></div><div><div>AN IN VITRO STUDY OF CINNAMOMUM ZEYLANICUM AS NATURAL INHIBITOR OF ANGIOTENSIN CONVERTING ENZYME (ACE) ON SHEEP (OVIS ARIES) TISSUES</div><div>Ranjini Hs, Padmanabha Udupa Eg, Shobha U Kamath, Manjunath Setty, Basavaraj Hadapad, Asha Kamath</div><div>Abstract View PDF  Download PDF [0 Downloads]</div><div>0 Views</div></div><div><div>ANTIFUNGAL ACTIVITY OF KOMBUCHA TEA AGAINST HUMAN PATHOGENIC FUNGI</div><div>Ari - Yuniarto</div><div>Abstract View PDF  Download PDF [0 Downloads]</div><div>0 Views</div></div><div><div>EVALUATION OF THE ANTI INFLAMMATORY ACTIVITY OF COMBINATION OF ETHANOL EXTRACTS OF AZADIRACHTA INDICA (NEEM) AND LAWSONIA INERMIS (HENNA)</div><div>Uthupathi Rao</div><div>Abstract View PDF  Download PDF [0 Downloads]</div><div>0 Views</div></div><div><div>A COMPARATIVE STUDY OF INVITRO ANTIMICROBIAL ACTIVITY AND TLC STUDIES OF PETALS OF SELECTED INDIAN MEDICINAL PLANTS</div><div>Sumathy Rengarajan</div><div>Abstract View PDF  Download PDF [0 Downloads]</div><div>0 Views</div></div><div><div>CONTROLLED DELIVERY OF ANTIRETROVIRAL DRUG LOADED CROSS LINKED MICROSPHERES BY IONIC GELATION METHOD.</div><div>S. Princyly</div><div>Abstract View PDF  Download PDF [0 Downloads]</div><div>0 Views</div></div><div><div>DESIGN, FACILE SYNTHESIS AND BIOLOGICAL EVALUATION OF NOVEL 1,3-THIAZINE DERIVATIVES AS POTENTIAL ANTICONSULSANT AGENTS</div><div>Ravindar B</div><div>Abstract View PDF  Download PDF [0 Downloads]</div><div>0 Views</div></div><div><div>BIOACTIVE AND FUNCTIONAL PROPERTIES OF FISH PROTEIN HYDROLYSATE FROM LEOGNATHUS BINDUS</div><div>Prabha Johnrose</div><div>Abstract View PDF  Download PDF [0 Downloads]</div><div>0 Views</div></div><div>ISSN: 2455-3891</div></div>	<div><div>User</div><div>Username <input type="text"/></div><div>Password <input type="password"/></div><div><input type="checkbox"/> Remember me</div><div>Login</div><div>Subscription</div><div>Back Issues</div><div>Asian Journal of Pharmaceutical and Clinical Research</div><div>Indicator 2008-2015 Value</div><div>SJR 0.33</div><div>Cites per doc 0.48</div><div>Total cites 740</div><div>Journal Metrics</div><div>Source Normalized Impact per Paper (SNIP): 0.688</div><div>Impact per Publication (IPP): 0.588</div><div>SCImago Journal Rank (SJR): 0.326</div><div>Print ISSN: 0974-2441</div><div>Online ISSN: 2455-3891</div><div>AJPCR Visitors</div><div>You are visitor no 116621</div></div>
---	---	---

SUBCHRONIC TOXICITY TEST OF COMBINATION ETHANOL EXTRACT OF DETAM 1 SOYBEAN (*GLYCINE MAX L. MERR*) AND JATI BELANDA (*GUAZUMA ULMIFOLIA LAMK*) TOWARD FUNCTION, WEIGHT, AND HISTOPATHOLOGICAL OF WISTAR RAT LIVER

MEILINAH HIDAYAT¹, SIJANI PRAHASTUTI², ESTHEROLITA DEWI³, DEWI SAFITRI⁴, SITI FARAH RAHMAWATI⁴, ANDREANUS A SOEMARDJI⁴

¹Department of Nutrition, Maranatha Christian University, Bandung, Jawa Barat, Indonesia. ²Department of Biochemistry, Maranatha Christian University, Bandung, Jawa Barat, Indonesia. ³Faculty of Medicine, Maranatha Christian University, Bandung, Jawa Barat, Indonesia. ⁴Pharmacology Clinical Pharmacy Research Group, School of Pharmacy Bandung Institute of Technology, Jalan Prof Drg. Suria Sumantri, MPH No 65, Bandung - 40163, Jawa Barat, Indonesia. Email: mellahidayat@yahoo.com

Received: 03 June 2016, Revised and Accepted: 20 June 2016

ABSTRACT

Objective: As an antiobesity therapy, combination extracts of Detam 1 soybean and Jati Belanda will be consumed for a long time; therefore, their toxicities to the liver need to be investigated. To determine the effect of subchronic toxicity test of combination of ethanol extract of Detam 1 soybean (EEDS) and ethanol extract of Jati Belanda (EEJB) on liver function with parameters: Alanine transaminase (ALT), macroscopic, and histopathological of liver.

Methods: This study was conducted on 120 Wistar rats (60 males and 60 females), 90 days (treatment group) and 120 days (satellite group). Rats were divided into six treatment groups (3 test materials, 1 control, and 2 satellites); each group included 10 males and 10 females.

Results: ALT levels of treatment groups (low dose, medium, and high), both males and females were lower than the control group ($p < 0.05$). The treatment groups demonstrated a good effects effect on liver function. Liver weight of all groups showed no significant difference compared with the control group ($p > 0.05$). Results of histopathological score interpretation of male and female liver rats of low dose groups were not disturbed; middle dose groups were slightly disturbed and high dose groups were damaged. Satellite high doses of male groups were disrupted, while female groups were not.

Conclusion: The combination of EEDS and EEJB has a good effect on liver function, did not lead to change organ weight and at low doses did not cause renal histopathology damage in rats after 90 days administration.

Keywords: Combination of soybean Jati Belanda, Toxicity subchronic test, Function, Weight, Histopathology, Liver.

INTRODUCTION

Obesity is major risk factors for a number of chronic diseases including diabetes, cardiovascular diseases, and cancer and is now dramatically on the rise. One alternative to overcome is efficacious use of medicinal plants. Most people assume that all medicines derived from plants are safe and without side effects. Drugs consumed for a long time should be examined and tested for their safety and side effects.

According to pharmacokinetic aspect, all drugs will be metabolized until they are completely eliminated from the body. Through oral administration, the absorption is commonly happen throughout the intestine which will be followed by metabolism in the liver. The active substances of the drug will be carried into the bloodstream and liver, so the liver is always exposed to potentially toxic materials. The longer contact time and the higher concentration of the active substances contained in drugs, the potential for liver damage will be higher [1].

Transaminase enzyme/aminotransferase is an indicator or index that is sensitive for detecting disease hepatoseluler [2]. When liver cells damaged, the enzyme transaminase will be spread out from the liver, so the levels in the blood will increase. Serum glutamic-pyruvic transaminase or alanine transaminase (ALT) can be detected more specific for liver damage because the level is dominant on the liver cell [3].

Previous studies have found that histopathological changes in the liver of rats treated with a single ethanol extract of Jati Belanda (EEJB),

single ethanol extract of Detam 1 soybean (EEDS) and the combinations indicate that administration of a single extract EEJB tend to be hepatotoxic, whereas single effect EEDS cause liver histopathologic improvement. The combined extract with the proportion of EEJB:EEDS (2:1) lead to worsened the liver histopathologic features on the contrary effect on weight showed better results [4,5].

Detam 1 soybean (*Glycine max L. Merr*) comes from the plantation of Tubers and Nuts Research Department in Malang. The preliminary study examined the effect of soybean on body weight male Wistar rats for 14 days with the different treatments of 11 types of extracts, indicated that extract which has the most activity on bodyweight loss is extract of Detam 1 soybean protein at dose of 20 mg/kg BW ($p = 0.022$) [6,7]. Iswantini stated that the methanolic extract of Jati Belanda leaves var Bogor has inhibition activity on pancreatic lipase, while extract of Jati Belanda leaves from Bumi Herbal Dago plantations is expected to be a therapeutic target of antiobesity [8].

The combination of EEDS and EEJB has been proven in reducing bodyweight loss and antihyperlipidemia [9-11]. It supposed to be consumed for relatively long time. Hence, a subchronic toxicity testing is needed.

In this study, we conducted subchronic toxicity tests on the effect of EEDS and EEJB combination *in vivo* for 90 days on the hepatic function, with parameters ALT, gross macroscopic and histopathological of Wistar male and female liver.

The aim of this study was to determine the subchronic toxicity after 90 days administration of EEDS and EEJB combination to macro and micropathology of Wistar rats liver function, followed by observation for the next 30 days (satellite) for groups without any treatment and with high dose treatment.

METHODS

The material used is EEDS and EEJB, which produced by a simple maceration process using ethanol 96%. A total of 120 Wistar rats - 60 males and 60 females, 6-8 weeks old weighing between 150 and 200 g - were randomly divided into six groups (3 test materials, 1 control, and 2 satellites) each of 10 male rats and 10 female rats, then adapted for 7 days. All groups were treated for 90 days and were observed for 90 days, except in the satellite group was observed for 120 days in accordance with the toxicity tests guidance from National Agency for Drug and Food Control (Balai Pemeriksaan Obat dan Makanan/ BPOM) [12,13]. In the treatment groups, rats were administrated with combination of EEKD and EEJB at a ratio of 1:2 in multiple doses for 90 days. Negative control group was only provided with solvent distilled water and 0.5% carboxymethyl cellulose (CMC). Group 1: A low dose, Group 2: Intermediate dose, and Group 3: High dose; EEKD: EEJB=50: 100 mg/kg/day, EEKD: EEJB=100: 200 mg/kg/day, and EEKD: EEJB=200: 400 mg/kg/day, respectively. Satellite group negative control, only administrated with distilled water solvent, and CMC 0.5%, and satellite group high dose (EEKD:EEJB = 200:400 mg/kg/day) for 120 days.

The parameters measured were as follows: (1) ALT level after 90 days, using the colorimetric method with Roche Cobas 131 apparatus on days 91 and 121, (2) weight of liver organ of all groups using a analytical balance with a precision of three digits after the decimal point, and (3) examination and analysis of histopathological preparations hematoxylin-eosin staining of Wistar rat liver organ. The parameters used to assess is the modification and adaptation of several study [14-16], i.e., architectural feature of the liver in general, the size of hepatocytes, necrosis of hepatocytes, dilation of sinusoid, venous congestion centralis (percentage of swelling), bleeding around the vein centralis, inflammation, and fibrosis of the liver cells. To make simple comparison among groups of damage, all interpretation converted into scores and summed.

Differences between groups were analyzed by one-way ANOVA, Mann-Whitney U, Kruskal-Wallis, and Chi-square tests as appropriate. Data were checked for normality by visual inspection of the normal

probability curves and with the Shapiro-Wilk test of normality, followed by Tukey honestly significant difference test, with a limit of significance $\alpha < 0.05$. The histopathological analysis of liver preparations was analyzed semi-quantitatively in score system and was totally summed.

RESULTS

After 90 days administration of the negative control group, low dose G1, G2, and G3 medium dose of high dose, then on day 91 serum ALT levels were assessed. The satellite groups were examined in the next 30 days and on day 121, the ALT levels of satellite control group and high dose satellite were measured. The results are shown in Fig. 1. The level of ALT serum and statistical analysis are provided in Tables 1-3.

Based there are significant differences between low, middle, and high dose group on male and female in control group, the ALT levels were significantly lower, mean that administration of the test material did not cause an increase in alanine aminotransferase levels. For high dose group, there is a significant different as compared to the control group both in low and middle dose. Satellite control high dose group showed a significant difference as compared to satellite control group ($p < 0.05$). After 30 days washout period, good ALT levels in high dose are performed.

On day 91, the rats were sacrificed, and the weight of liver organ in the negative control group, low dose G1, G2 middle dose, and G3 high dose

Table 1: ALT serum levels on male and female Wistar rats in different groups of treatment

Group	n	Male		Female	
		Average	SD	Average	SD
Group control negative	10	67.60	12.607	167.20	13.612
G1 dose low	10	56.00	10.965	132.80	9.705
G2 dose middle	10	52.40	7.074	110.70	6.183
G3 dose high	10	35.40*	3.169	84.70*	6.701
Satellite control	10	55.00	10.541	127.10	9.550
Satellite dose high	10	32.90*	3.035	74.80*	4.077
Result of homogeneity test variance	0.032			0.131	
ANOVA	0.000*			0.000*	
Tukey HSD*					

*The mean difference is significant at the 0.05 level. SD: Standard deviation, ALT: Alanine transaminase

Table 2: Different advanced test averages Tukey HSD of male Wistar rats

Group	Group control	Group 1 low	Group 2 middle	Group 3 high	Satellite control	Satellite D high
Group control		*	*	**	*	**
Group 1 low			NS	**	NS	**
Group 2 middle				**	NS	**
Group 3 high					**	NS
Satellite control						**
Satellite D high						

*: Significant, **: Highly significant, NS: Non-significant

Table 3: Different advanced test averages Tukey HSD of female Wistar rats

Group	Group control	Group 1 low	Group 2 middle	Group 3 high	Satellite control	Satellite D high
Group control		**	**	**	**	**
Group 1 low			NS	**	NS	**
Group 2 middle				**	NS	**
Group 3 high					**	NS
Satellite control						**
Satellite D high						

**: Highly significant, NS: Non-significant

was weighed. Satellite groups were sacrificed at the next 30 days, on day 121. Table 4 shows the weight of rats' liver.

Liver organ of male and female Wistar rats in treatment groups were not significant $p=0.099$, and $p=0.270$, respectively, as compared to the control group.

Histopathological analysis of liver organ male Wistar rats

The liver was weighed, soaked in a solution of 1% formalin, with stained with hematoxylin-eosin for histopathology preparations. Then, analyzed under a light microscope with 100 and $\times 400$ magnification and conducted semi-quantitative interpretation by scoring. The parameters used are architectural feature in general, the size of hepatocyte cells, necrosis of hepatocytes, sinusoidal dilation, congestion of central vein, bleeding around vicinity of the central vein, inflammation, and fibrosis. Comparison of damage of each group, the result of interpretation was converted into scores and summed up. Results of resumes obtained from each group are listed in Tables 5 and 6.

The results of histopathological score is summarized in the Table 7. Results total scores of male control group were 12.3; females 18.25; G1 low dose males 17.4, females 19.5; G2 medium dose males 27.6, females 27.7; G3 high dose males 49, females 52.6; satellite control males 17.2;

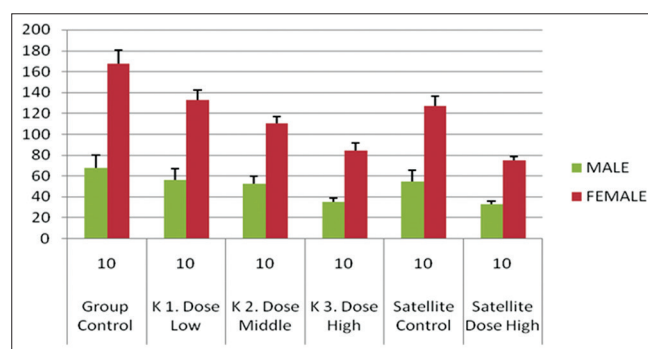


Fig. 1: Alanine transaminase serum levels on male and female Wistar rats in different groups of treatment

Table 4: Weight of on male dan female Wistar rats' liver

Group	n	Male		Female	
		Average/gr	SD	Average/gr	SD
Group control	10	6.61	0.56	5.71	1.20
K1 dose low	10	6.12	0.73	6.44	0.89
K2 dose middle	10	6.29	1.56	6.73	1.42
K3 dose high	10	6.30	1.30	6.10	0.82
Satellite control	10	6.91	1.11	6.93	0.84
Satellite dose high	10	7.61	1.23	6.24	0.85
Sig ANOVA		0.099	($p>0.05$)	0.270	($p>0.05$)

SD: Standard deviation

females 26.8 and 31.2 the satellite high dose males and the female the result is very low: 9.2. The results of microscopic observation on liver male and female rats at low dose group showed no damaged, for middle dose group of male and female slightly distracted and satellite high dose male group was severely damaged, while the female was very good, and not disturbed. Liver organ of female rats had an excellent recovery in 30 days.

DISCUSSION

The ALT levels, in general, however were lower in male than female rats. The ALT levels of treatment groups (low dose G1, G2 medium, and high G3), both males and females showed significantly lower than the negative control group, indicated that the treatment did not cause an increase in ALT. It was concluded that the provision of material test did not interfere the ALT, but on the contrary, it showed a good effect on liver function. There was no chemical parameter-related pathological change, so the changes were not considered to be toxicologically significant.

Genistein, an isoflavone in soybean is powerful antioxidants, significantly lowered tumor necrosis factor alpha plasma and prevented emerge of non-alcoholic fatty liver disease through stress reduction oxidative mechanism [17]. High level of antioxidants in EEDS will reduce oxidative stress so that the liver cell damage can be prevented, as shown by stable or lower ALT level [18].

The lowest level of ALT was observed in G3 high dose group and high dose control satellite, means that the higher the dose, the better the ALT levels. The combination of appropriate natural materials provides synergistic effects, sum up the antioxidant activities and protective the liver from damage [19,20]. Isoflavones, flavonoids, and tannins contained in EEDS and EEJB are known to have antioxidant properties suppress the free radicals [18-20]. However, the active substance in EEJB causes liver damage is not clearly defined, exacerbating histopathologic Fig. 2 of liver cells, as shown in the previous study [4,5]. Moreover, optimal dose of antioxidants is not yet known, many studies on this field were needed, but in that study, if the dose increased, the results got better. In this study, administration of the test substances showed a positive effect on liver function, adverse effects of Jati Belanda might be suppressed by antioxidants in Detam 1 soybean [18-20].

The liver weights of all groups showed no significant difference as compared to the control group ($p>0.05$); it is concluded that the test material did not damage the liver cells as shown by no change in macroscopic of liver organ.

The interpretation of preparations histopathology score of G1 low dose group both male and female showed that their livers were not disturbed. G2 medium dose and high dose G3 slight disturbed and damaged in satellite high doses male group. Giving high doses of the test substance has the potential to have a cumulative effect and postponed effect against the male rat liver, seen by disturbed histopathologic feature of satellite high dose group, after 30 days later. The dose tested

Table 5: Histopathological of liver preparation Hepar male Wistar rats

Liver score	Group control	Group 1 low	Group 2 middle	Group 3 high	Satellite control	Satellite D high
Architectural feature	1	3	7	11	1	4
Size of hepatocyte cells	0	2	5	7	1	0
Necrosis of hepatocytes	0	0	0	1	0	0
Sinusoidal dilation	2	3	7	10	0	12
Congestion of centralis v	2,3	2,4	1,6	5	2,2	3,2
Bleeding around centralis v	0	0	0	0	0	0
Inflammation	6	6	6	11	9	7
Fibrosis	1	1	1	4	4	5
Total scores	12.3	17.4	27.6	49	17.2	31.2

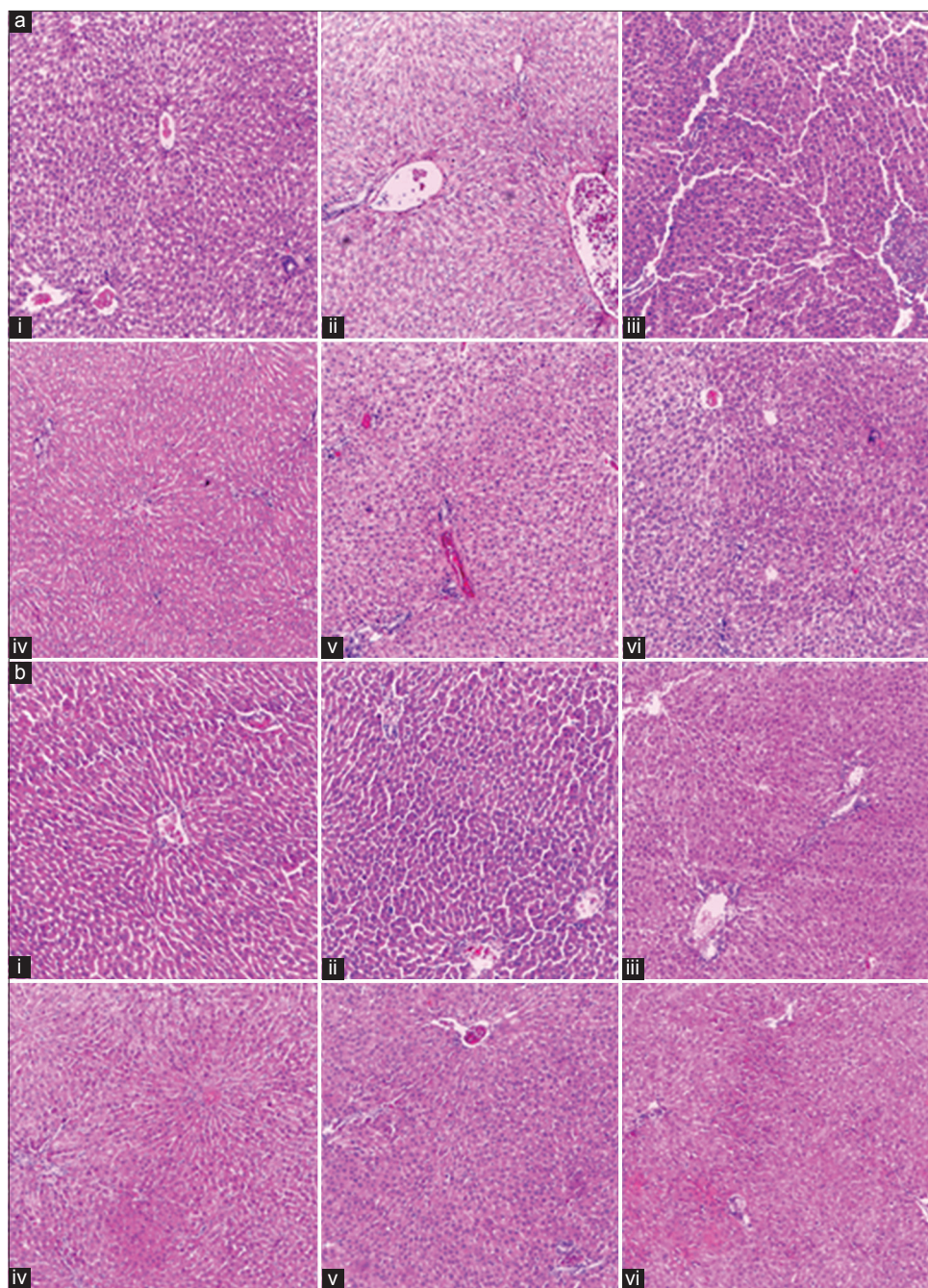


Fig. 2: (a) Female. (i) Female low dose, (ii) female middle dose, (iii) female high dose, (iv) female negative control, (v) female satellite control, (vi) female satellite high dose. (b) Male. (i) Male low dose, (ii) male middle dose, (iii) male high dose, (iv) male negative control, (v) male satellite control, (vi) male satellite high dose

is equivalent to dose which is $600 \text{ mg} \times 56 = 33600 \text{ mg}$ or 33.6 g for human. The use of low dose (the used dose for therapeutic), i.e., $150 \times 56 = 8400 \text{ mg}$ is still within a safe limit for health.

In female rats, administration of high dose satellite group was good restoration of liver cells after 30 days, as compared to the control group. It might be due to the induction of the test substances on female hormones which facilitate liver cell repair. If we compare to another study, no observed adverse effect level (NOAEL) of black soybean (*G. max*) hull extract was found to be $5074.1 \text{ mg/kg body weight/day}$ for males and $7617.9 \text{ mg/kg body weight/day}$ for females in mice [21]. The toxic dose for female is higher than in male mice; it is concluded that the effects on hepatic histopathological differ in males and females.

CONCLUSION

A combination of EEDS and EEJB extracts shows a significant effect on the liver function, and maintains the organ weights, and it is safe and no interference to the liver histopathology at low doses and NOAEL at dose of $8400 \text{ mg/kg body weight/day}$ for humans.

ACKNOWLEDGMENT

The authors thank the Directorate General of Higher Education of the Republic of Indonesia for Research Grant No. SP-DIPA 023.04.1.673453/2015 dated 14 November 2015 Revision 01, dated March 3, 2015. Our thanks to Dr. Roro Wahyudianingsih Sp. PA who

Table 6: Histopathology preparation Hepar rats female

Liver score	Group control	Group 1 low	Group 2 middle	Group 3 high	Satellite control	Satellite D high
Architectural feature	0	2	2	12	0	0
Size of hepatocyte cells	1	1	4	8	1	0
Necrosis of hepatocytes	0	0	0	3	0	0
Sinusoidal dilation	5	4	8	10	5	0
Congestion of centralis v	4.25	3.5	2.7	3.6	2.8	1.2
Bleeding around centralis v	1	0	0	0	0	0
Inflammation	7	7	8	12	12	6
Fibrosis	0	2	3	4	6	2
Total scores	18.25	19.5	27.7	52.6	26.8	9.2

0: Not damaged, 1: Very slightly damaged, 2: Slightly damaged at ¼ of the visual field, 3: Damaged ¼ the visual field, 4: ½ slightly damaged on the field of vision, 5: ½ damaged the visual field, 6: Badly damaged in ½ of the visual field, 7: ¾ heavily on visual field, 8: ¾ heavily on visual field, 9 damaged at >¾ of the visual field, 10: Severely damaged the entire field of view

Table 7: Total scores of histopathological analysis of liver male and female Wistar rats

Group	Total scores	
	Male	Female
Control	12.3	18.25
Dose low	17.4	19.5
Dose middle	27.6	27.7
Dose high	49	52.6
Satellite control	17.2	26.8
Satellite high	31.2	9.2

Score 10-20: Not damaged at all; considered the same as control, 21-30: Slightly damaged, 31: Damaged

has helped making preparations for histopathology, analysis, and interpretation of histopathology PA, and Ingrid S Surono, MSc, Ph.D., for English editing assistance.

REFERENCES

1. Fatmawati A. Pengaruh Pemberian Ekstrak Daun Jati Belanda Dosis Bertingkat Terhadap Hepar Tikus Wistar. Semarang. Repository: Fakultas Kedokteran Universitas Diponegoro; 2008.
2. Behrman ER, Kliegman RM, Arvin MA. Ilmu Kesehatan Anak Paediatrics. Nelson. Vol. 2. Jakarta: EGC; 2000.
3. Yayasan Spiritia. Penjelasan Tes Fungsi Hepar Warta AIDS. San Diego: Yayasan Spiritia; 2001. p. 1.
4. Vera E. Gambaran Histopatologis Hepar Terhadap Pemberian Ekstrak Etanol Biji Kedelai Detam 1 dan Daun Jati Belanda Serta Kombinasinya pada Tikus Wistar Jantan Yang Diinduksi Pakan Tinggi Lemak. Bandung. Repository: Universitas Kristen Maranatha; 2015.
5. Hidayat M, Soeng S, Wahyudiansih R, Ladi JE, Krisetya YA, Elviora V. Ekstrak Kedelai Detam 1, daun Jati Belanda serta Kombinasinya terhadap Berat Badan dan Histopatologis Hepar Tikus Wistar. JKKI 2015;6(4):167-78.
6. Hidayat M, Kurnia D, Sujatno M, Sutadipura N, Setiawan I. Perbandingan kandungan makronutrisi dan isoflavon dari biji, tempe dan ekstrak kedelai detam 1 dan wilis serta potensinya dalam menurunkan bobot badan. Bionatura J Ilmu Hayati dan Fisik 2010;12(1):5-13.
7. Hidayat M, Sujatno M, Sutadipura N, Setiawan I. Effect several soybean (*Glycine max* L. Merr) extracts to food intake, body weight and cholecystokinin plasma in rats. Majalah Ilmu Faal Indonesia 2009;8(3), 151-8.
8. Iswantini D, Silitonga RF, Martatilofa E, Darusman LK. *Zingiber cassumunar*, *Guazuma ulmifolia*, and *Murraya paniculata* extracts as antiobesity: *In vitro* inhibitory effect on pancreatic lipase activity. Hayati. J Biosci 2011;18:1.
9. Hidayat M, Soeng S, Prahastuti S. Characteristics of combination of ethanol extract detam 1 soybean (*Glycine max* L. Merr) and ethanol extract of jati belanda leaves (*Guazuma ulmifolia*) in potential inhibition of pancreas lipase enzyme. International Seminar on Natural Product of Medicine. Poster, Bandung Institute of Technology; 2012.
10. Krisetya YA, Hidayat M, Soeng S. Perbandingan Efek Ekstrak Etanol Kedelai Detam 1, Jati Belanda dan Kombinasinya terhadap Penghambatan Kenaikan Berat Badan tikus Wistar Jantan yang diinduksi Pakan Tinggi Lemak. Bandung. Repository: Universitas Kristen Maranatha; 2013.
11. Hidayat M, Soeng S, Prahastuti S, Tiono H, Krisetya YA, Sugiono M. Characteristics of ethanol extract of detam 1 indonesian soybean, jati belanda leaves and the effects of their combinations to weight gain and the jejunum histopathological changes in male wistar rats. Eur J Med Plants 2015;7(2):87-98.
12. BPOM. Badan Pengawas Obat dan Makanan Republik Indonesia. Peraturan Kepala Badan Pengawas Obat dan Makanan Republik Indonesia Nomor 7 Tahun 2014 tentang Pedoman Uji Toksisitas Nonklinis Secara *In vivo*.
13. OECD, Organization for Economic Cooperation and Development. Guidelines for Testing of Chemicals. Paris: OECD;2001. p. 407-8.
14. Singh K and Arora SP. Effect of feeding salseed-meal tannins on histopathology of some organs and amino acid uptake. Indian J Anim Sci 1982; 52(2):84-8.
15. Omar HM, Hassan KA, Elghafar ASKh, and Ahmend EA. Aluminium toxicity in rats: The role of tannic acid as antioxidant. Ass Univ Bull Environ Res 2003;6(2):1-14.
16. Karimi H, Kia HD, Hosseinkhani A. Histological effects of different levels of sorghum grain on the liver and Kidney of ghezelxarkhar merino crossbred lambs. Anim Vet Sci 2014;2(4):130-4.
17. Hartini. Studi Tentang Efek Antioksidan Vitamin E dengan Parameter SGOT dan SGPT Serum Darah Tikus Putih (*Rattus novergicus*) yang Dipapar Asap Rokok. Biology; 2006. p. 1.
18. Hidayat M, Soeng S, Prahastuti S, Hermanto PT, Andhika YK. Aktivitas Antioksidan dan Antitrigliserida Ekstrak Tunggal Kedelai, Daun Jati Belanda serta Kombinasinya. Bionatura J Ilmu Hayati dan Fisik. 2014;16(2): 89-94.
19. Hermanto PT. Aktivitas Antioksidan Ekstrak Etanol Biji Kedelai (*Glycine max* (L.) Merr) Varietas Detam 1, Daun Jati Belanda (*Guazuma ulmifolia*) dan Kombinasinya. Bandung. Repository: Fakultas Kedokteran Universitas Kedokteran Maranatha; 2013.
20. Koshy AS, Anila L, Vijayalakshmi NR. Flavonoids from *Garcinia cambogia* lower lipid levels in hypercholesterolemic rats. Food Chem 2001;72:289-94.
21. Fukuda I, Tsutsui M, Yoshida T, Toda T, Tsuda T, Ashida H. Oral toxicological studies of black soybean (*Glycine max*) hull extract: Acute studies in rats and mice, and chronic studies in mice. Food Chem Toxicol 2011;49(12):3272-8.