



Quick Menu

- ▶ Journal Home
- ▶ About this Journal
- ▶ Author Guidelines
- ▶ Manuscript Submission
- ▶ Articles in Press
- ▶ Abstracting & Indexing
- ▶ OASPA/DOAJ/COPE Compl.
- ▶ Editorial Policy
- ▶ Editorial Board Members
- ▶ Current Issue
- ▶ Archives
- ▶ SDI General Editorial Policy
- ▶ Propose a Special Issue
- ▶ Reprints
- ▶ Subscription
- ▶ Pub. Ethics & Malpractice
- ▶ Digital Archiving Policy

Upcoming Journals

- ▶ Journal of Advances in Microbiology
- ▶ Asian Journal of Physical Sciences
- ▶ Asian Journal of Chemical Sciences
- ▶ Asian Journal of Environment & Ecology

▶ MORE

European Journal of Medicinal Plants



2015 - Volume 7 [Issue 2]

Contents

Original Research Article

Cytotoxicity of Various Fractions of Compounds Extracted from Yoyo Bitters on Human Cervical Cancer Cells

A. A. Onyeaghala^{1*}, I. O. Omotosho² and A. R. Shivashankara¹
¹School of Clinical Research, Texila American University, Georgetown, South America, Guyana.
²Departments of Chemical Pathology, College of Medicine, University of Ibadan, Nigeria.

[Abstract](#) [Full Article - PDF](#) Page 46-58 [Article Metrics](#)

DOI : [10.9734/EJMP/2015/15913](#)

[Review History](#)

Short Communication

Study to Evaluate the Antioxidant Activity of *Astragalus glycyphyllos* Extract in Carbon Tetrachloride-Induced Oxidative Stress in Rats

Aleksandar Shkondrov¹, Rumyana Simeonova², Magdalena Kondeva-Burdina², Vessela Vitcheva² and Ilina Krasteva^{1*}
¹Department of Pharmacognosy, Faculty of Pharmacy, Medical University of Sofia, 2 Dunav St. Sofia 1000, Bulgaria.
²Department of Pharmacology, Faculty of Pharmacy, Laboratory of Drug metabolism and Drug toxicity, Pharmacotherapy and Toxicology, Medical University of Sofia, 2 Dunav St. Sofia 1000, Bulgaria.

[Abstract](#) [Full Article - PDF](#) Page 59-66 [Article Metrics](#)

DOI : [10.9734/EJMP/2015/16259](#)

[Review History](#)

Original Research Article

Evaluation of Wound Healing Activity of *Erythrophleum suaveolens* (Gull. & Perr.) Brenan and *Moringa oleifera* Lam. On Infected Albino Rats

O. C. Akanji^{1*} and M. A. Sonibare²
¹Department of Plant Science and Biotechnology, Adekunle Ajasin University, Akungba Akoko, Nigeria.
²Department of Pharmacognosy, University of Ibadan, Ibadan, Nigeria.

[Abstract](#) [Full Article - PDF](#) Page 67-76 [Article Metrics](#)

DOI : [10.9734/EJMP/2015/15222](#)

[Review History](#)

Original Research Article

Comparative Study on the Phytochemical Compositions and Antihyperglycemic Potentials of the Leaves Extracts of *Combretum paniculatum* and *Morinda morindoides*

Akintayo L. Ogundajo¹, Mutiu I. Kazeem², Jude E. Evroh¹, Mayowa M. Avoseh¹ and Isiaka A. Ogunwande^{1*}
¹Department of Chemistry, Natural Products Research Unit, Faculty of Science, Lagos State University, Badagry Expressway, PMB 0001 LASU Post Office, Ojo, Lagos, Nigeria.
²Department of Biochemistry, Antidiabetic Drug Discovery Group, Faculty of Science, Lagos State University, Badagry Expressway, PMB 0001 LASU Post Office, Ojo, Lagos, Nigeria.

[Abstract](#) [Full Article - PDF](#) Page 77-86 [Article Metrics](#)

DOI : [10.9734/EJMP/2015/15929](#)

[Review History](#)

Original Research Article

Characteristics of Ethanol Extract of Detam 1 Indonesian Soybean and Jati Belanda Leaves and the Effects of their Combinations on Weight Gain and Jejunum Histopathological Changes in Male Wistar Rats

Meilinah Hidayat^{1*}, Sylvia Soeng², Sijani Prahastuti³, Hartini Tiono⁴, K. Yonathan Ar⁵ and Monica Sugiono⁵
¹Nutrition Department, Faculty of Medicine, Maranatha Christian University, Indonesia.
²Biology Department, Faculty of Medicine, Maranatha Christian University, Indonesia.
³Biochemistry Department, Faculty of Medicine, Maranatha Christian University, Indonesia.
⁴Histology Department, Faculty of Medicine, Maranatha Christian University, Indonesia.
⁵Faculty of Medicine, Maranatha Christian University, Bandung, Indonesia.

[Abstract](#) [Full Article - PDF](#) Page 87-98 [Article Metrics](#)

DOI : [10.9734/EJMP/2015/13440](#)

[Review History](#)

Original Research Article

Ex vivo and *In vivo* Antioxidant Related Effects of *Zingiber officinale* Roscoe (Ginger) Extracts in Humans

Yousif Y. Bilto^{1*} and Nesslerin G. Alabdalla²
¹Department of Biological Sciences, The University of Jordan, Amman, Jordan.
²College of Applied Medical Sciences, Majmaah University, Majmaah, Saudi Arabia.

[Abstract](#) [Full Article - PDF](#) Page 99-108 [Article Metrics](#)

DOI : [10.9734/EJMP/2015/16618](#)

[Review History](#)

Search this site

Google™ Custom Search

Search

[Advanced Search](#)

Announcement & News

Science (IF: 31) report confirmed the high standard of SDI journal

As per a recent report (Link) of Science Journal (present Impact factor 31), one of our journal (Bri...

Polish Ministry of Science and Higher Education included 18 SDI journals in its official report of 2013

SDI is pleased to announce that Polish Ministry of Science and Higher Education included 18 SDI jour...

SDI introduced Post-publication peer review by its comment section

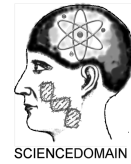SDI journals encourage Post-publication peer review by its comment section. Policy details a...

▶ MORE

SCIENCE DOMAIN Awards

SCIENCE DOMAIN International Excellence Award 2014

▶ MORE



Characteristics of Ethanol Extract of Detam 1 Indonesian Soybean and Jati Belanda Leaves and the Effects of their Combinations on Weight Gain and Jejunum Histopathological Changes in Male Wistar Rats

Meilinah Hidayat^{1*}, Sylvia Soeng², Sijani Prahastuti³, Hartini Tiono⁴,
K. Yonathan Ari⁵ and Monica Sugiono⁵

¹Nutrition Department, Faculty of Medicine, Maranatha Christian University, Indonesia.

²Biology Department, Faculty of Medicine, Maranatha Christian University, Indonesia.

³Biochemistry Department, Faculty of Medicine, Maranatha Christian University, Indonesia.

⁴Histology Department, Faculty of Medicine, Maranatha Christian University, Indonesia.

⁵Faculty of Medicine, Maranatha Christian University, Bandung, Indonesia.

Authors' contributions

This work was carried out in collaboration between all authors. Author MH designed the study performed the statistical analysis, wrote the protocol and wrote the first draft of the manuscript. Authors SS, SP and HT designed and conducted the the study. Authors KYA and MS conducted the the study and kept it done properly. All authors read and approved the final manuscript.

Article Information

DOI: 10.9734/EJMP/2015/13440

Editor(s):

- (1) Karim Hosni, Institute National de Recherché et d' Analyse Physico-chimique, Biotechpole de Sidi Thabet, Tunisia.
- (2) Patrizia Diana, Department of Molecular and Biomolecular Sciences and Technologies, University of Palermo, Palermo, Italy.
- (3) Marcello Iriti, Department of Agricultural and Environmental Sciences, Milan State University, Italy.

Reviewers:

- (1) Ahmed M.S. Hegazy, Benha Faculty of Medicine, Benha University, Egypt.
- (2) Ifeoma Irene Ijeh, Department of Biochemistry, College of Natural and Applied Sciences, Michael Okpara University of Agriculture, Nigeria.
- (3) Oudghiri Mounia, Department of Biology, University Hassan II, B.P 5366 Maarif, Casablanca, Morocco.
- (4) Anonymous, Turkey.
- (5) Anonymous, India.

Complete Peer review History: <http://www.sciencedomain.org/review-history.php?iid=1018&id=13&aid=8356>

Original Research Article

Received 16th August 2014
Accepted 23rd February 2015
Published 7th March 2015

ABSTRACT

Background: Anti-Nutritional-Factors (ANF) are natural or synthetic compounds that interfere with the absorption of nutrients. ANF may cause changes in the histopathology of the small intestinal mucosa, and may affect the digestive, secretory and absorptive functions of the small intestine. Soybean and Jati Belanda leaves which can promote weight loss, may contain ANF. In this study, soybean seeds variety Detam 1 and Jati Belanda leaves were used to assess their potential effects on weight gains and jejunum functions.

Research Objective: To study the effects of ethanol extracts of Detam 1 raw soybean (EEDS) and Jati Belanda (EEJB) Bumi Herbal Dago variety and their combinations on weight gain and jejunum histopathological changes in male Wistar rats.

Research Methods: Phytochemical analyses of EEDS and EEJB ethanol extracts were performed, then assayed for the above mentioned activities after administered to high-fat induced male Wistar rats for 28 days. Weight gain was determined and histopathological examination of jejunum was achieved after fixation and staining with Hematoxylin Eosin.

Results: The combinations of EEDS:EEJB (2:1 and 1:2 w/w) reduced the weight gain with the effect being more pronounced (5.95%) for the combination 1:2 (w/w). Such effect may be attributed to ANFs contained in EEDS and EEJB such as tannin, saponin, flavonoids and phenolics. The histopathologic examination of the positive control group was not different from all treatment groups ($p>0.05$).

Conclusion: The combination EEDS:EEJB (1:2 w/w) is effective in inhibiting weight gain without remarkable histopathological changes in male Wistar rat jejunum.

Keywords: Anti-nutritional factors; detam 1 soybean; jati belanda leaves; weight gain-jejunum; histopathological changes.

1. INTRODUCTION

Soybean (*Glycine max* L. merr) is known for their health benefits effects. they are good dietary supplements for both humans and animals. Soybean are also known to contain anti nutritional factors (ANF) which are detrimental to health [1].

ANF are natural or synthetic compounds that interfere with the absorption of nutrients [2]. ANFs include: protease inhibitors, like trypsin and pepsin; lipase inhibitors, amylase inhibitors, phytic acid, oxalic acid, glucosinolates, saponins and flavonoids, which are a group of polyphenolic compounds that include tannins [3]. Several studies have reported that ANF can caused changes in the small intestine mucosal histopathology, a reduction in villus height and crypt depth. These histopathological changes can affect the ability of the small intestine, especially the jejunum to digest, secrete and absorb food, leading hence to diarrhea, malnutrition and weight loss [4,5].

Jati Belanda (*Guazuma ulmifolia* Lamk) has been known as a medicinal plant that is useful as aslimming agent. Its use however is limited by its adverse effects on intestinal function [6]. Jati Belanda contains various active chemical

compounds such as tannins, mucilage, caffeine, β -sitosterol, friedelin, kaueronic acid, flavonoids, saponins, antioxidants proanthocyanidins, etc [7,8,9]. The changes in intestinal morphology and histopathology associated with use of the leaves have been attributed to the presence of these ANFs [10].

The purpose of this study was to determine the characteristics of ethanol extract of Detam 1 variety raw soybean (EEDS) and Jati Belanda (EEJB) Bumi Herbal Dago variety and the effects of their combinations on weight gain and jejunum histopathology changes in Wistar rats.

2. MATERIALS AND METHODS

Detam 1 soybean seed variety, which is a high quality of black soybean that has been approved by the Agricultural Ministry of Republic of Indonesia; grown on the estate of Research Unit and Development of Legumes and Tuber in Malang, East Java Indonesia [11] and Jati Belanda grown in plantations of Bumi Herbal Dago, North Bandung, Indonesia were used.

2.1 Preparation of Ethanol Extracts [12]

Ethanol extraction of Detam 1 Soybean and Jati Belanda leaves was carried out by using simple maceration, refered to references [12]. Detam 1

Soybean (3 kg) and Jati Belanda (700 g) leaves were extracted twice by ethanol for 7 days. After evaporation of solvent, a thick liquid extract was obtained (71 and 56 g for EEDS and EEJB, respectively).

2.2 Phytochemicals Analyses

Phytochemical evaluation on EEDS and EEJB were carried out using standard procedures as described by Muchtadi, 1989.

2.3 Phenolic Test Procedures

A portion of EEDS/EEJB (2 g) was mixed with 5 mL of methanol and filtered through cotton wool, then 5% ferric chloride FeCl_3 (2-3) drops were added to confirm the presence of phenols.

2.4 Flavonoid Test Procedures

2.4.1 Method I

A portion of EEDS/EEJB (2 g) was mixed with 5 mL of methanol and filtered through cotton wool, 5% HCl (2) drops then Mg powder were added to confirm the presence of flavonoids after shaken vigorously.

2.4.2 Method II

A portion of EEDS/EEJB (2 g) was mixed with 5 mL of methanol and filtered through cotton wool, 2N H_2SO_4 (2) drops were added to confirm the presence of flavonoids after shaken vigorously.

2.4.3 Method III

A portion of EEDS/EEJB (2 g) was mixed with 5 mL of methanol and filtered through cotton wool, 10% NaOH (2) drops were added to confirm the presence of flavonoids after shaken vigorously.

2.5 Flavonoids Test Procedures [13]

A portion of EEDS/EEJB (2 g) was mixed with 5 mL of methanol and 5% ammonia and sheked thouroughly. Therafter, 2 N HCl were added and the mixture was shaken to become Water phase. The solution was divided into 4 tubes, A, B, C and D. Dragendorf solution was added into tube A, Wagner solution into tube B, Mayer solution into tube C and Hager solution into tube D.

2.6 Lieberman Burchard Test Procedure (Terpenoid and Steroid Test)

A portion of EEDS/EEJB (5g) was mixed with 5 mL of methanol, and filtered through cotton wool, then heated to dry. Subsequently extracted in chloroform and water (1:1). The chloroform extract (2 drops) were drop on the plate and then allowed it to dry. Then concentrated sulfuric acid and acetic acid anhydride (1 drop) were added, to confirm the presence of terpenoids or steroid by the color changes.

2.7 Saponin Test Procedures

A portion of EEDS/EEJB (2 g) was mixed with 5 mL of methanol and filtered through cotton wool, then 2N HCl (2) drops were added to confirm the presence of saponins by the formed foam.

2.8 Quinone Test Procedures

A portion of EEDS/EEJB (2 g) was mixed with 5 mL of methanol and filtered through cotton wool, then 1% NaOH (2-3) drops were added to confirm the presence of quinones.

2.9 Tannin Test Procedures

A portion of EEDS/EEJB (2 g) was mixed with 5 mL of methanol and filtered through cotton wool, then 1% FeCl_3 (2-3) drops were added to confirm the presence of tannins.

2.10 Animal Research Procedure

Forty male Wistar rats, aged 11 weeks, weighing between 180-280 g, after acclimatization for 7 days, they were randomly divided into 8 groups. All groups, except the NC group, induced with high-fat diet for 14 days. Followed by the treatment with ethanol extract for 28 days. NC: negative control, were fed standard diet; PC: Positive control, high-fat diet without treatment, receiving only distilled water; P1: high-fat diet and EEDS 10 mg : EEJB 10 mg; P2: high-fat diet and EEDS 20 mg : EEJB 10 mg; P3: high-fat diet and EEDS 10 mg : EEJB 20 mg; P4: high-fat diet and EEDS 20 mg/rat/day; P5: high-fat diet and of EEJB 20 mg/rat/day. And for body weight measurement, we add one group of rats, P6: high-fat diet, administered of Orlistat 2.16 mg/rat/day, as a positive control. High Fat Diet: Cholesterol 1% (0.25 kg), egg yolk 5% (26 eggs), animal fat (goat) 10% (2.5 kg), coconut cooking oil 8% (2 kg), wheat flour 20% (5 kg) and

standard feedant (pellet) until 100% (14 kg). 100 g high fat diet contains 750 kkal. [14]

All rats were weighed every 2 days. After 28 days of treatment, the rats were sacrificed, the jejunum was taken and prepared for histopathological examination. The potential inhibition of ethanol extract of Detam 1 Soybean (EEDS) and Ethanol extracts of Jati Belanda Leaves (EEJB) on weight gain after treatment for 28 days and the changes of jejunum in histopathological preparations were measured. This study received ethical clearance from the Ethical Committee of Maranatha Christian University/ Immanuel Hospital Bandung.

2.11 Preparation of Jejunum Histopathological for Haematoxylin Eosin Staining [15]

2.11.1 A. preparation of paraffin block [12]

The jejunum tissue was inserted into cassette metals, and then immersed in a glass beaker containing a solution of 10% buffered formalin. The tissue in the glass beaker were put in an incubator at temperature of 65-70°C for 30 minutes. Then the tissue were processed for dehydrated and followed by clearing processed so that paraffin could get into the tissue. Impregnancy process, is purposed to condense the rat jejunum tissue. Then continued with embedding process. Paraffin block containing the jejunum tissue was cut using a microtome with a thickness of 0.5 µm. Then incision results were put in warm water and placed on a glass object, then allowed to dry at room temperature. The jejunum tissue were fixed on the object glass by heated in an incubator at temperature of 65 - 70°C. The details preparations referred to references. [15]

2.11.2 Mixture B. staining with hematoxylin eosin [15]

The next step were deparafinization, then the preparations were rinsed with running water. The mixture were soaked in Hematoxyline solution for 4-5 minutes. Then the preparations were rinsed again with running water. The mixture were dipped into a lithium solution of by 4 dye, then were rinsed with running water. The mixture were dipped into 80% alcohol solution by 20 dye. Then the mixture were immersed in eosin solution for 5 minutes. Preparations were rinsed with running water until clean. Then immersed in a solution of 70% alcohol by 5 dye. The mixture were dipped

into 80% alcohol solution by 5 dye, 90% alcohol by 5 dye, 100% alcohol as much as 5 dye, then were dried and dipped in a Xylol solution of 5 dye, then dried. The mixture were spilled with adhesive (entellan) and covered with a cover glass. The details preparations referred to references [15].

2.11.3 Determining the scoring [16]

Histopathologic analysis assessed by observe at every field of the view of the histopathological jejunum Wistar rats, refered to the atlas references [17], then took the scoring as much as 10 times of the field of each preparations view based on modified Barthel Manja assessment [16] as follows:

- There is no pathological changes (magnification 400x) = 0
- Epithelial desquamation = 1
- Erosion of the epithelial surface (gaps 1-10 epithelial cells / lesion) = 2
- Epithelial ulceration (gap > 10 epithelial cells / lesion) = 3. 17

After 10 times visual fields of each jejunum histological rat, the median scores were taken and followed by statistical analysis.

2.12 Statistical Analysis

Data of body weight were analysed using ANOVA test, followed by Tukey HSD test. Data of histopathological changes were analysed using Kruskall Wallis test followed by Mann Whitney test.

3. RESULTS

From 3000 grams of Detam 1 soybean we get 71 grams of EEDS, as much as 2.3%. If optimal dose for rats: 20 mg / kgBW so the optimal dose for humans : $56 \times 20 \text{ mg} = 1120 \text{ mg} = 1.12 \text{ g}$, it was retrieved from $100 / 2.3 \times 1:12 \text{ g} = 48.69 \text{ g} \sim 49 \text{ g}$ of Detam 1 soybean.

From 700 grams of simplicia Jati Belanda leaves we get 56 grams EEJB, as much as 8%. If optimal dose for rats: 20 mg / kgBW so the optimal dose for humans : $56 \times 20 \text{ mg} = 1120 \text{ mg} = 1.12 \text{ g}$, it was retrieved from $100/8 \times 1:12 \text{ g} = 14 \text{ g}$ of Jati Belanda leaves.

Soybean Seed Extract Ethanol Detam 1 contained: phenolic, flavonoid NaOH, triterpenoids, steroids, saponins, quinones and tannins, but did not contain flavonoid H₂SO₄ and alkaloids, as seen in Table 1.

Ethanol Extract of Jati Belanda Leaves contained: phenolic, flavonoid NaOH, triterpenoids, quinones and tannins, but did not contain flavonoid H₂SO₄, steroid, alkaloids, and saponins, as seen in Table 2 .

the percentage of weight gain P3 (EEDS 10 mg : EEJB 20 mg) group is the least (5.9%), followed by P2 (EEDS 20 mg: EEJB 10 mg) (8.5%), 5 (EEJB 20mg) (14.3%), P1 (EEDS 10 mg : EEJB 10 mg) (15%), and P4 (EEDS 20 mg) (18.42%).

All treatment groups showed better results in inhibiting weight gain of experimental animals compared with negative controls (NC) and positive control (PC). Table 3 and Fig. 1 showed that the percentage of weight gain in NC group is the greatest (21%), followed by PC (18.7%). The Orlistat group (P6) showed the least percentage of weight gain (0.9%). In the treatment groups,

Data were analyzed using ANOVA $\alpha = 0.05$ showed $F_{\text{calculated}} (6,760) > F_{\text{table}} 5\% (2,25)$ and $1\% (3,120)$, significancy 0.000, as seen in Table 4, this mean there were at least a couple of different treatments ($p=0,000 < 0.01$). So continued with Tukey HSD test, and the results can be seen in Table 5.

Table 1. The characteristics of phytochemical of secondary metabolites of detam 1 soybean

Extract	Secondary metabolites							
	Phenolic	Flavonoid	Alkaloid H ₂ SO ₄	LB	Saponin NaOH	Quinone (Wagner) Triterpenoid steroid	Tannin	
Detam 1 Soybean	+	-	+	-	+	+	+	+

Table 2. The characteristics of phytochemical of secondary metabolites of Jati Belanda leaves var. Bumi Herbal Dago

Extract	Secondary metabolites							
	Phenolic	Flavonoid	Alkaloid H ₂ SO ₄	LB	Saponin NaOH	Quinone (Wagner) Triterpenoid steroid	Tannin	
Jati Belanda	+	-	+	-	+	-	-	+

Table 3. Average body weight and the percentage of weight gain of male wistar rats

Groups	Beginning day 15	End day 42	% weight gain
NC	213	270	21%
PC	236.5	280	18.7%
P1	203	243	15%
P2	227	249	8.5%
P3	180	200	5.9%
P4	211	261	18,42%
P5	213	248	14,3%
P6	213	214	0,9%

Table 4. Analyses of ANOVA significancies

	Sum of squares	Df	Mean square	F	Sig
Between groups	1845.535	7	263.648	6.760	.000
Within groups	1559.948	4047	38.999		
Total	3405.483				

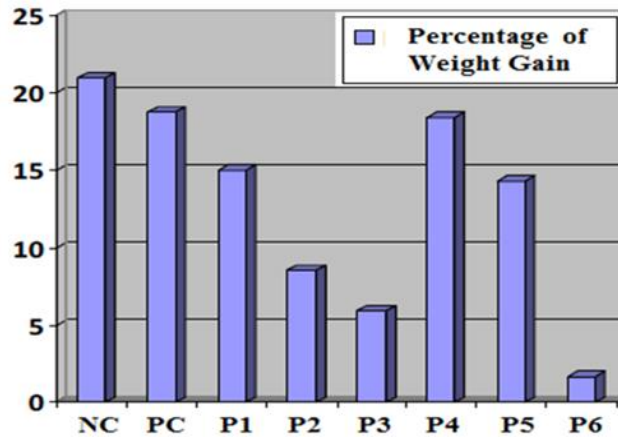


Fig. 1. Percentage of wistar rats weight gain

Notes : NS : Non Significant, * : Significant, ** : Highly Significant
 NC : Negative Control, standard diet

PC : Positive Control, High Fat Diet without Treatment, only aquadest
 P1 : High Fat Diet and EEDS 10 mg : EEJB 10 mg
 P2 : High Fat Diet and EEDS 20 mg : EEJB 10 mg
 P3 : High Fat Diet and EEDS 10 mg : EEJB 20 mg
 P4 : High Fat Diet and EEDS 20 mg/ rat/day
 P5 : High Fat Diet and EEJB 20 mg/ rat/day
 P6 : High Fat Diet and Orlistat 2,16 mg/rat/day

Table 5. Analyses of rats weight gain percentage using Tukey HSD

	NC	PC	P1	P2	P3	P4	P5	P6
NC		NS	NS	*p= 0.000	** p=0.001	NS	*p=0.046	** p=0.000
PC			NS	** p=0.003	** p= 0.000	NS	NS	** p=0.000
P1				NS	** p=0.008	NS	NS	** p=0.000
P2					NS	** p=0.004	NS	* p=0.025
P3						** p=0.004	*p=0.009	NS
P4							NS	** p=0.000
P5								** p=0.006
P6								

Notes : NS : Non Significant, * : Significant, ** : Highly Significant
 NC : Negative Control, standard diet

PC : Positive Control, High Fat Diet without Treatment, only aquadest
 P1 : High Fat Diet and EEDS 10 mg : EEJB 10 mg
 P2 : High Fat Diet and EEDS 20 mg : EEJB 10 mg
 P3 : High Fat Diet and EEDS 10 mg : EEJB 20 mg
 P4 : High Fat Diet and EEDS 20 mg/ rat/day
 P5 : High Fat Diet and EEJB 20 mg/ rat/day
 P6 : High Fat Diet and Orlistat 2,16 mg/rat/day

Statistical analyses showed that P2 and P3 treatment groups were highly significant different from the PC and NC, means the provision of a combinations of EEDS 20 mg: 10 mg EEJB and EEDS 10 mg: 20 mg EEJB showed good potential to inhibit weight gain of rats. P3 was significantly different from the group of P4 and P5, means the provision of combinations of EEDS 10 mg: 20 mg EEJB was better than single extract in inhibiting weight gain in rats. P3 groups did not significantly different with group P6, showed that provision of combinations of

EEDS 10 mg: EEJB 20 mg had an equal effect with Orlistat in inhibiting weight gain on rats, but in percentage rate, Orlistat still better and among all of treatments groups, the EEDS 10 mg: EEJB 20 mg is the best to inhibit weight gain.

From the observation of jejunum histopathological Wistar rats tissue preparations from each group which seen in Figs. 2,3,4,5,6,7 and 8 obtained a median scores that are shown in Table 6 as follows.

The data has been obtained then presented in the form of graphs, can be seen in Fig. 9 below.

To determine whether there were significant differences between each group, we use the Kruskal-Wallis test. The results of significance is 0.008 which meant that there were differences

in the value of significant histopathologic scores between groups. To determine which treatment groups had significantly different results, then the median difference test was performed using Mann-Whitney test that can be seen in the Table 7.

Histopathological view of jejunum of male wistar rats after 28 days of treatment

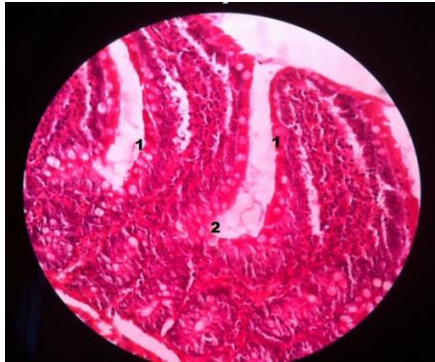


Fig. 2. Histopathological view of NC

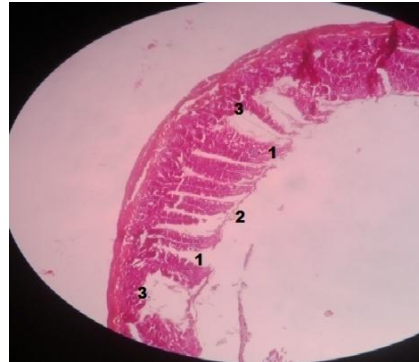


Fig. 3. Histopathological view of PC

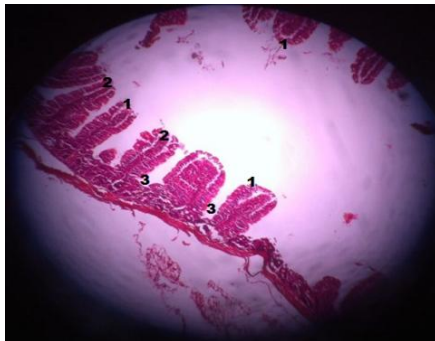


Fig. 4. Histopathological view of P1

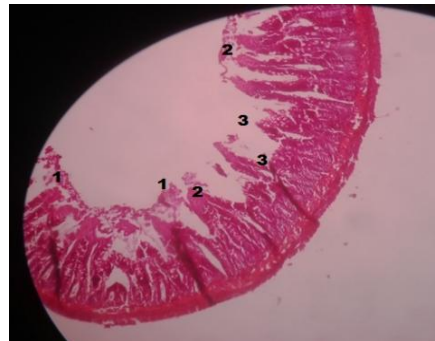

Fig. 5. Histopathological view of P2

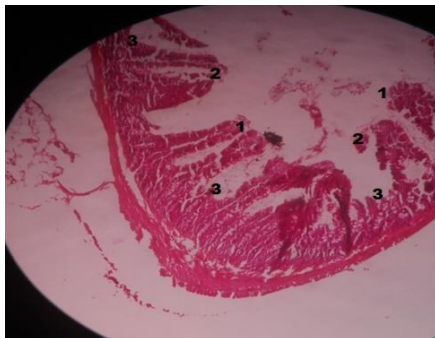


Fig. 6. Histopathological view of P3

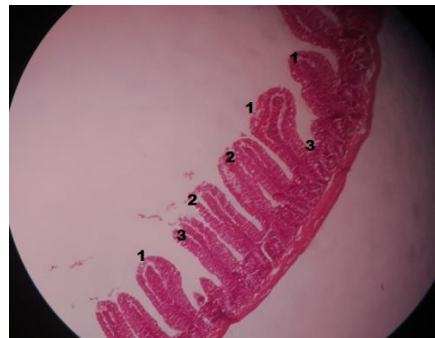


Fig. 7. Histopathological view of P4

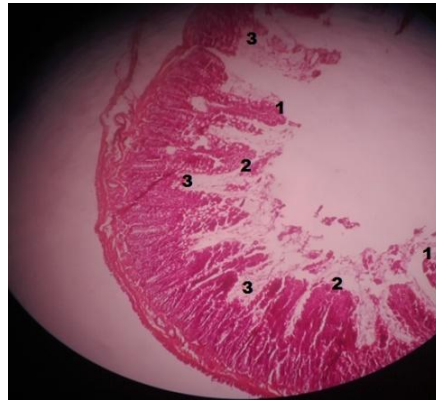


Fig. 8. Histopathological view of P5

Notes:1. There is no pathological changes (magnification 400x) = 0; 2. Epithelial desquamation = 1; 3. Erosion of the epithelial surface (gaps 1-10 epithelial cells / lesion) = 2; 4. Epithelial ulceration (gap > 10 epithelial cells / lesion) = 3

Table 6. Median scores of histopathological jejunum of wistar rats, based on Barthel Manja scoring

Groups	Median scoring				
	Rats 1	Rats 2	Rats 3	Rats 4	Rats 5
NC	1	1	1	2	1
PC	2	3	2	3	3
P1	3	3	3	3	3
P2	1	3	3	3	3
P3	3	3	3	3	3
P4	3	3	3	1	3
P5	3	2	3	2	3

Table 7. Mann-Whitney test towards scores of jejunum histopathological of male wistar rats

	NC	PC	P1	P2	P3	P4	P5
NC		0,014*	0,004*	0,028*	0,004*	0,028*	0,011*
PC			0,134	0,699	0,134	0,699	1,000
P1				0,317	1,000	0,317	0,134
P2					0,317	1,000	0,699
P3						0,317	0,134
P4							0,699
P5							

Notes: NC: Negative Control, standard diet
 PC: Positive Control, High Fat Diet without Treatment, only aquadest
 P1: High Fat Diet and EEDS 10 mg: EEJB 10 mg
 P2 : High Fat Diet and EEDS 20 mg : EEJB 10 mg
 P3 : High Fat Diet and EEDS 10 mg : EEJB 20 mg
 P4 : High Fat Diet and EEDS 20 mg/ rat/day
 P5 : High Fat Diet and EEJB 20 mg/ rat/day

The results of Mann Whitney test showed that there were significantly differences in the scores value of jejunum histopathological view ($p < 0.01$) between groups of NC with P1, P2, P3, P4, and P5. While the group NC also found significantly different with PC. Between PC group with group

P1, P2, P3, P4, and P5 were not found significant differences. This showed that the provision of EEDS and EEJB did not worsen the jejunum Wistar rat histopathological view. Worsening jejunum function of Wistar rat may caused by high-fat diet [18,19].

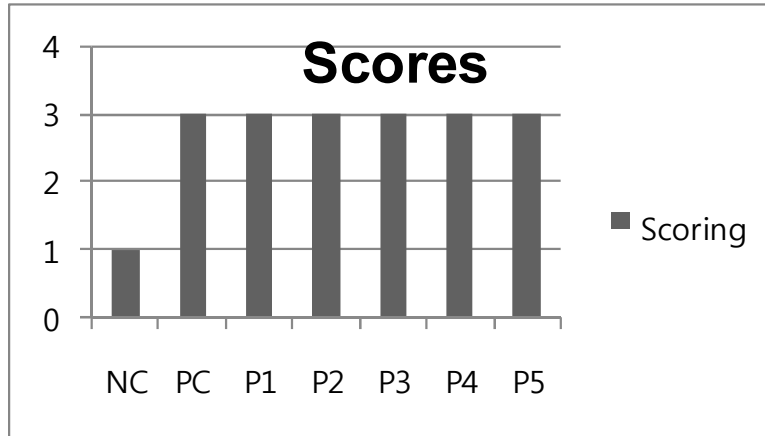


Fig. 9. Median graph of histopathologic scores of Jejunum of male Wistar Rats

4. DISCUSSION

In general, all treatment of EEJB and EEDS inhibited weight gain in male Wistar rats; the results of percentage inhibition of weight gain were varied. The combinations treatment group of P3, EEDS 10 mg: EEJB 20 mg or EEDS:EEJB=1:2 was assumed as the best treatment for achieving in inhibition of weight gain. It showed the least percentage weight gain (5.9%), it supports the earlier in vitro research, which states that the combination of EEDS:EEJB=1:2 showed the best inhibition of pancreatic lipase enzyme activity [20].

The qualitative phytochemical test results showed that the ethanol extract of Detam 1 soybean seeds contain: phenolic, flavonoid triterpenoid, steroid, saponins, quinone and tannins, but did not contain alkaloid. Inhibition of weight gain in rats in this study may primarily because EEDS contain ANF compounds such as: saponins, tannins, phenolic and flavonoids. Saponins which can act as antifeedant. Tannins is an astringents, bitter plant polyphenolic compounds that can bind and precipitates proteins. The most important flavonoid in soybean are Isoflavone, ie: genistein and daidzein. Isoflavone can inhibit pancreatic lipase enzyme and induces the cell apoptosis of adipocytes. Levels of isoflavone in soy are most numerous in the ethyl acetate fraction, and the highest levels of Daidzein in ethyl acetate fraction of Detam 1 soybean seed is 0.669% [21].

Soybean usually contains: trypsin inhibitor, lectin, polyphenol, phytic acid, and saponin, which are known to have negative effects on the absorption

of food in the digestive tract [22,23,1]. ANFs can cause histological changes in the mucosal lining of the small intestine, such as reduction of villi height and depth of cryptae. These histological changes can affect the function of the small intestine leading to weight loss. Mechanism by which trypsin inhibitor and lectin cause changes the histology of the mucosal lining of the small intestine is unclear but both have been shown to cause changes in villus height and crypt depth [6,7].

The results of qualitative phytochemical test of ethanol extract of Jati Belanda leaves Bumi Herbal Dago, almost the same with EEDS; EEJB contain: phenolic, flavonoid H₂SO₄, triterpenoid, quinone and tannin, but did not contain steroidal alkaloid and saponin [20].

The results of the analysis of histopathological view between treatment groups (P1, P2, P3, P4 and P5) and the positive control did not show significant differences. Positive control group was a control group that fed high-fat diet but did not given any treatment. Weight gain in the negative control is greater than the positive control because according to Bagchi research in 1998, rats that fed high-fat diet, their mucosal lining of gut may change so that there will be atrophy of the villi leading mal-absorbtion of food and it will affect the weight gain in the rats [24]. Free radicals are involved in the pathogenesis of stress and injury to the gastrointestinal tract. According to Bagchi, the effects of high-fat diet can increase the production of Reactive Oxygen Species (ROS) that can induce gastrointestinal oxidative stress and mucosal injury in Sprague-Dawley rats. These studies stated that there was

a correlation between the production of ROS and the effects of damage to the gastric and intestinal tissues [24].

The pathogenesis of most common case of herbs toxic effects on the gastrointestinal is the irritation of mucous membranes. Some kinds of chemical compounds, such as tannin, responsible for that process [25,10,3]. High doses of astringent in tannin can cause irritation excessive effects of the intestinal mucosal membrane [10]. Proanthocyanidin (tannin condensation) can damage the mucosal of the gastrointestinal tract, as well as reduce the absorption of nutrients and essential amino acid, such as methionine and lysine [9]. Presumably that toxic factors is the cause of the changes in the histopathology of intestinal mucosal [10].

In this study, the results of Kruskal Wallis test showed significant differences on at least one pair of treatment groups and the Mann Whitney test showed significantly differences between groups NC and PC. So the jejunum mucosal in the PC group may have significantly differed from NC group. The PC group was not different with the treatment groups, but in but the GIT function were different, as shown in the results of weight gain. It can be concluded that administered of ethanol extract of Detam 1 Soybean, ethanol extract of Jati Belanda leaves and their combinations in therapeutic dose did not worsen the histopathological view of jejunum, and safe for consumption.

The previous research showed that provision extract protein of Detam 1 soybean raw seed 20 mg/kgBW/day and extract protein of Detam 1 tempeh 20 mg/kgBW/day to male Wistar rats for 14 days caused atrophy villi. These extract protein contained a high level of β -conglycinin [1]. Among the Anti Nutritional Factors, β -conglycinin was suggested as being one of the key Anti Nutritional Factors: β -conglycinin has been approved that induces inflammation and oxidation, and causes dysfunction of intestinal digestion and absorption in fish, and finally reduces fish growth [26]. The reducing body weight that occurred was caused not only by β -conglycinin effect but probably by other Anti Nutritional Factors and other substance also [1]. In Hu et al study, the results showed that soy fiber improved weight loss in overweight and obese adults [27]. So combinations of soybean and Jati Belanda leaves which contained many active compounds becomes a promising therapy for obesity in the future.

Based on the results of this study, consume ethanol extracts Detam 1 dan Jati Belanda leaves dose of 20 mg/day for 28 days is safe and did not result in any adverse histopathological changes in male Wistar rats jejunum. Converse from dosage for rats, extract dose for humans is 1.12 g, it was extracted from Detam 1 soybean 49 g, still below the dose that can cause toxicity and neurotoxicity (for humans: 2777 g) [28]. However literatures state that a slimming drug is recommended not too much consume because it can damage the intestine, so should be used in the right dose [6,29,30].

There are limitations of this study: Another ANF compounds in ethanol extract of Detam 1 soybean and Jati Belanda leaves such as trypsin inhibitor, lectin, phytic acid, oxalic acid and antivitamin levels have not been tested because limitations of the tools.

5. CONCLUSION

EEDS contained phenolic, flavonoid H₂SO₄ triterpenoid, steroid, saponin, quinone and tannin, but does not contain alkaloids. EEJB contained phenolic, flavonoid H₂SO₄ triterpenoid, quinone and tannin, but does not contain steroidal alkaloid, saponin. Inhibition of rat weight gain in this study primarily because EEDS contained ANF compounds: saponins, tannins, phenolic and flavonoids. while EEJB contained tannin, phenolic and flavonoid compounds. The EEDS:EEJB=10 mg:20 mg is the best combinations to inhibits weight gain and administration of EEDS, EEJB and their combinations in therapeutic dose did not make the jejunum histopathological view of male Wistar rat worsen.

CONSENT

It is not applicable.

ACKNOWLEDGEMENTS

We would like to thank the Higher Ministry of Education of the Republic of Indonesia for the Competitive Grant funding SP DIPA-023.04.2.189789/2014 so that this research can be accomplished.

COMPETING INTERESTS

Authors have declared that no competing interests exist.

REFERENCES

1. Hidayat M, Ladi JE. Increasing of plasma cholecystokinin level and jejenum histological. HAYATI Journ. Biosci. 2012;19(2):53-59.
2. Oxford Dictionary of Biochemistry and Molecular Biology. Oxford University Press. ISBN 0-19-8529171. 2006;107.
3. Beecher GR. Overview of Dietary Flavonoids: nomenclature, occurrence and intake. J. Nutr. 2003;133(10):3248-3254.
4. Yen JT, Jensen HA, Simon J. Effects of dietary raw soybean and soybean trypsin inhibitor on trypsin and chymotrypsin activities in the pancreas and in small intestinal juice of growing swine. Nutrition. 1977;107:158-165.
5. Feng J, Liu X, Xu Z, Wang Y, Liu J. Effects of fermented soybean meal on digestive enzyme activities and intestinal morphology in broilers. J Anim Sci. 2007;86(6):1149-54
6. Supriadi, dkk. Tumbuhan Obat Indonesia: Penggunaan dan Khasiatnya. Jakarta: Obor. 2001;39.
7. Suharmiati MH. Khasiat dan Manfaat Jati Belanda, si Pelangsing dan Peluruh Kolesterol. Jakarta: Agromedia Pustaka. 2003;8.
8. Sulaksana JJ. Kemuning dan Jati Belanda, Budidaya dan Pemanfaatan untuk Obat. Jakarta: Penebar Swadaya. 2005;22.
9. Reed JD. Nutritional toxicology of tannins and related polyphenols in forage legumes. J.Anim.Sci. 1995;73:1516-1528
10. Gumay AR. Pengaruh pemberian ekstrak daun Jati Belanda (*Guazuma ulmifolia* Lamk) dosis bertingkat terhadap gambaran histopatologi duodenum tikus Wistar. Thesis. 2008. Fakultas Kedokteran Diponegoro. Eprints.undip.ac.id; 23949.
11. Balai Penelitian Tanaman Kacang-kacangan dan Umbi-umbian. 2012. Available:<http://balitkabi.litbang.deptan.go.id/varietas-unggul/vu-kedelai/77-varietas-unggul-kedelai-detam-1.html>
12. Harborne JB. Metode Fitokimia. Penuntun Cara Modern menganalisis Tumbuhan. Terbitan Kedua. Penerbit ITB Bandung; 1987.
13. Muchtadi D. Petunjuk Laboratorium Analisis Pangan. Departemen Pendidikan dan Kebudayaan Direktorat Jendral Pendidikan Tinggi. PAU Pangan dan Gizi. IPB Bogor. 1989;4-8.
14. Smith JB, Mangkoewidjojo S. Pemeliharaan, Pembiakan Hewan di Daerah Tropis. Jakarta: Universitas Indonesia Press. 1988;43-44.
15. Anatomic Pathology Laboratory. Modified Technique Histopathologic and cytology preparations Management in Anatomic Pathology Laboratory of the University of Padjadjaran. Hasan Sadikin Hospital. 2003;21-30.
16. Manja B, Hapfelmeir S, Quintanilla LM, Kremer M., Rohde M, Hogardt M. Pretreatment of Mice with Streptomycin Provides a *Salmonella enterica* Serovar Typhimurium Colitis Model that Allows Analysis of Both Pathogen and Host. Infection and Immunity. 2003;71(5):2839-2858. American Society for Microbiology. ASM society. Available:www.ncbi.nlm.nih.gov/pmc/articles/PMC153285
17. Gartner LP, Hiatt JL. Color textbook of histology international edition. Third Edition. Saunders Elsevier. Philadelphia, PA 19103-2899. ISBN-13:978-1-4160-2945-8. 2007;403-5.
18. Thomsen LL, Tasman-Jones C, Maher C. Effects of dietary fat and gel forming substances on rat jejunal disaccharidase levels. Digestion. 1983;26(3):124-30. Available:www.ncbi.nlm.nih.gov/pubmed/6406282
19. Vasquez CM, Zanetti R, Santa-Maria C, Ruiz-Gutierrez V. Effects of two highly monounsaturated oil on lipid composition and enzyme activities in rat jejunum. Biosci Rep. 2000;20(5):355-68. Available:www.ncbi.nlm.nih.gov/pubmed/11332598
20. Hidayat M, Soeng S, Prahastuti S. Characteristics of combinations ethanol extract of detam 1 soybean (*Glycine max* L. merr) /EEDS and ethanol extract of Jati Belanda Leaves (*Guazuma ulmifolia*) /EEJB in Potential Inhibition of Pancreas Lipase Enzyme. Proceeding. International Symposium of Natural Products and Medicine, ITB, Bandung. 2012;34.
21. Hidayat M, Kurnia D, Sujatno M, Sutadipura N, Setiawan. Comparison of Macronutrition and isoflavone content in Detam 1 dan Wilis seed, Tempeh, and Soybean Extracts and Its Potential in Decreasing Body Weight. Bionatura. 2010;12:5-13.
22. Palacios MF, Easter RA, Soltwedel KT, Parson CM, Douglas MW & Hymowitz T. Effect of Soybean Variety and Processing

- on Growth Performance of Young Chicks and Pigs. J. Anim. Sci. 2004;82:1108-1114.
23. Godlewski MM, Slazak P, Zabielski R, Piatowska A, Gralak MA. Qualitative study of soybean-induced changes in proliferation and programmed cell death in the intestinal mucosa of young rats. J Physiol Pharm. 2006;57:125-133.
24. Bagchi D, Carryl OR, Tran MX, Khorn R.L, Bagchi DJ, Garg A, et al. Stress, diet and alcohol-induced oxidative gastrointestinal mucosal injury in rats and protection by bismuth subsalicylate. J. Appl. Toxicol. 1998;18:3-13.
Available:<http://www.ncbi.nlm.nih.gov/pubmed/9526828>[Onlinelibrary.wiley.com/journal/10.1002/\(ISSN\)1099-1263](http://onlinelibrary.wiley.com/journal/10.1002/(ISSN)1099-1263)
25. Gilani GS, Cockell KA, Sepehr E. Effects of antinutritional factors on protein digestibility and amino acid availability in foods. J AOAC Int. 2005;88(3):967-987. PMID 16001874.
26. Zhang JX, Guo LY, Jiang WD, Kuang SY, Liu Y, Jiang J et al. Soybean β -conglycinin Induces Inflammation and Oxidation and Causes Dysfunction of Intestinal Digestion and Absorption in Fish; 2013. Available:www.plosone.org/article/info%3Adoi%3A10.1371/journal.pone.0058115
27. HuX, Gao J, Zhang Q, Fu Y, Li K, Zhu S, et al. Soy fiber improves weight loss and lipid profile in overweight and obese adults: a randomized controlled trial. Mol Nutr Food Res. 2013;57(12):2147-2154.
Available:www.ncbi.nlm.nih.gov/pubmed/23711774
28. Shahib MN, Syamsunarno MRAA, Faried A, Yuliana D, Anggraeni D, Yuniarti L, Tih F. The effect of *Glycine max* extract diets on changes in NR2B gene expression, cognitive vitality and neurotoxicity in high concentrate consumption. The Kitakanto Medical Journal. 2010;60(1):41-47.
29. Health Ministry of Republic of Indonesia. Inventaris Medicinal Plant of Indonesia. Jakarta. 2000; Bind 3:1348.
30. Health Ministry of Republic of Indonesia. Parameter of General Standard of Extracts of Herbal Medicine. Jakarta: General Directory of Food and Drugs Regulation. 2000;Bind 1:28.

© 2015 Hidayat et al.; This is an Open Access article distributed under the terms of the Creative Commons Attribution License (<http://creativecommons.org/licenses/by/4.0>), which permits unrestricted use, distribution, and reproduction in any medium, provided the original work is properly cited.

Peer-review history:

The peer review history for this paper can be accessed here:
<http://www.sciencedomain.org/review-history.php?iid=1018&id=13&aid=8356>