



ISSN 0119-9641

PHILIPPINE JOURNAL OF INTERNAL MEDICINE

CONTENTS

LETTER TO THE EDITOR

Diabetes and Cardiovascular Disease *Alberto Daysog, Jr., M.D., FPCP* V

LEGAL PRESCRIPTION FOR DOCTORS

Advance Health Care Directives *Atty. Rodel V. Capule, M.D., FPCP* VII

SPECIAL ARTICLES

Community Involvement in Strategic Hypertension Management
Ramon F. Abarquez, Jr., M.D., EFACC, FPCP, CSPSH IX

Policies on Healthcare of Older Persons: Implications to Internal
Medicine Training and Practice
Shelley F. de la Vega, M.D., MSc, FPSGM XIII

ORIGINAL ARTICLES

Severity Outcome of Acute Ischemic Stroke in Corellation to Hyperglycemia
*Genalin A. Estandian, M.D., Carmenchu Rueda, M.D., Clara Rivera, M.D.,
Melanio Grayda, M.D. and Johnny Lokin, M.D.* 151

Mini-Mental Status Examination Profile of the Elderly Filipino
Hemodialysis Patient
*Marc Evans M. Abat, M.D., Florosita A. Reyes, M.D.
and Miguel A. Ramos Jr., M.D.* 161

SGPT Check and Risk Factor Evaluation for Early Liver Disease Detection
(Screen Registry) A Multi-Center, Observational, Cross-Sectional Study
Alma Casareo, M.D., Jaime Ignacio, M.D. and Marievi Lelis 175

CASE REPORT

Trisomy 8, 19, 21 Associated Myeloproliferative/Myelodysplastic Syndrome
Loida Cruz-Torres, M.D. and Jesus Relos, M.D. 179

MEDICAL GRAND ROUNDS (St. Luke's Medical Center, Department of Medicine)

A 35-Year-Old Female, with High Grade Fever and Rashes
Limdawati Kwee, M.D. 183

DRUG TRIAL

Improved Glycaemic Control and Less Hypoglycaemia with Novorapid® Flexpen®
(Insulin Aspart) in Filipino Patients with Acute Hyperglycaemia
Richard Elwyn Fernando, M.D., Gerry H. Tan, M.D. and Editha Arceo-Dalisay, M.D. 189

OFFICIAL PUBLICATION OF THE PHILIPPINE COLLEGE OF PHYSICIANS

July - August 2009

Volume 47 Number 4



PHILIPPINE JOURNAL OF INTERNAL MEDICINE

PCP COMPONENT AND AFFILIATE SOCIETIES

Philippine Society of Allergy, Asthma & Immunology

Philippine College of Chest Physicians

Philippine Dermatological Society

Philippine Diabetes Association

Philippine Society of Endocrinology & Metabolism

Philippine Society of Gastroenterology

Philippine Society of Geriatric Medicine

Philippine Heart Association

Philippine Society of Hematology & Blood Transfusion

Philippine Society of Medical Oncology

Philippine Society for Microbiology & Infectious Diseases

Philippine Society of Nephrology

Philippine Society of Nuclear Medicine

Philippine Neurological Association (Affiliate Member)

Philippine Rheumatism Association

EDITOR EMERITUS
Conrado Dayrit, M.D., FPCP

EDITORIAL ADVISER
Esperanza Icasas-Cabral, M.D., FPCP

REGENT-COORDINATOR
Jaime C. Montoya, M.D., FPCP

EDITOR-IN-CHIEF
Rafael R. Castillo, M.D., FPCP

ASSOCIATE EDITORS
Linda A. Lim-Varona, M.D., FPCP
Willie T. Ong, M.D., FPCP
Miguel A. Ramos, Jr., M.D., FPCP

BUSINESS MANAGER
Miss Connie Bayona

PHILIPPINE COLLEGE OF PHYSICIANS
Officers and Members
of the

Board of Regents (01 June 2009 until 31 May 2010)

President	EUGENIO JOSE F. RAMOS, M.D., FPCP
Vice President.....	JAIME C. MONTOYA, M.D., FPCP
Secretary.....	NORBERT LINGLING D. UIY, M.D., FPCP
Treasurer.....	OSCAR T. CABAÑOG, M.D., FPCP

REGENTS

PRISCILLA B. CAGUIOA, M.D., FPCP	KENNETH HARTIGAN-GO, M.D., FPCP
ANTHONY C. LEACHON, M.D., FPCP	MARILYN O. MATEO, M.D., FPCP
MARIANO B. LOPEZ, M.D., FPCP	

CHARLES Y. YU, M.D., FPCP
Immediate Past President

Medical Grand Rounds

St. Luke's Medical Center, Department of Medicine

Phil. J. Internal Medicine, 47: 183-188, July-Aug., 2009

A 35-YEAR-OLD FEMALE, WITH HIGH GRADE FEVER AND RASHES

Limdawati Kwee, M.D.*

PRESENTATION OF CASE

Limdawati Kwee, M.D. (2nd year Medical Resident, Department of Medicine, St. Luke's Medical Center): A 35 year old female was admitted because of high grade fever and rashes.

One year prior to admission, she developed intermittent low grade fever associated with erythematous macular rashes on the anterior chest wall and all extremities. She also noted multiple lymph nodes at posterior triangle of supraclavicular area, bilateral, firm, non tender, non matted which progressively increase in size, 2.5 cm in greatest diameter. Excision biopsy was done and the histopathology showed reactive hyperplasia. She was subsequently prescribed Amoxicillin/Clavulanic Acid for five days, however there was no improvement. Eight months prior to admission, the fever became remittent with the highest recorded temperature of 39.0°C. This was associated with erythematous, evanescent maculopapular rashes on the face, trunk and extremities with centrifugal distribution. She claimed morning stiffness in her metacarpophalangeal joints. She was admitted in another hospital and was diagnosed with fever of unknown origin, prescribed Paracetamol and Ibuprofen. The symptoms (fever, rashes, joints pain) persisted for two months and then progressively subsided for five months with intake of Paracetamol as needed. Eight days prior to admission, there was recurrence of aforementioned symptoms and sore throat. There was no cough, night sweats, weight loss, photosensitivity, muscle pains, jaundice. Persistence of symptoms prompted consult at St. Luke's Medical Center.

She has no history of hypertension, diabetes mellitus nor bronchial asthma. She has regular dental check-ups and with no history of surgeries. She claims to have allergy to penicillin. She denies history of travel outside Metro Manila recently. She works as a finance supervisor in a company. She denies any

exposure to any chemical substance, insect bites, nor pets. She does not smoke nor drink alcohol. She claims to have family history of hypertension, diabetes, and lung cancer.

On physical examination, she was conscious, coherent and not in cardio-respiratory distress. Her blood pressure was 100/70 mmHg, cardiac rate 100/bpm regular, respiratory rate 21/cpm, and febrile at 38.8°C. General examination of the skin showed erythematous, maculopapular rashes on the back, fore arms, and thighs. She had pink palpebral conjunctiva and anicteric sclera. There were multiple bilateral firm, non-tender, non-matted lymphadenopathies on posterior triangle of supraclavicular area with the biggest measuring 2.0 cm. Lung and heart examination were unremarkable. The abdomen was flat, soft, non-tender, normoactive bowel sounds with no palpable masses. There was swelling on the metacarpophalangeal and proximal interphalangeal joints of both hands with limitation of active movement, but without warmth nor tenderness.

On admission, Hemoglobin was 12.2 g/dL, WBC of 12,560/mm³, neutrophils of 76% lymphocytes of 13%, platelet count of 311,000/mm³. ESR was 96mm/hr, C-reactive protein was elevated at 48 mg/L. Urinalysis was normal. Chest radiography showed calcified granuloma right upper lobe with no active infiltrate.

DISCUSSION

Limdawati Kwee, M.D.: What is the most probable cause of fever and rash in this patient?

According to Kaye *et al.*,¹ disease with fever and rashes could be characterized by the following type of eruption: 1) centrally distributed maculopapular eruption, 2) peripheral eruptions, 3) confluent desquamative erythemas, 4) vesiculobullous eruptions, 5) urticarial eruptions, 6) nodular eruptions, 7) purpuric eruptions, 8) eruptions with ulcers and/or eschars. Our patient presented with centrifugal distribution rashes or centrally distributed maculopapular eruption. This type of eruption can be divided into three categorical causes: drug induced, infectious and autoimmune (Figure 1).

*Second year Medical Resident, Department of Medicine, St. Luke's Medical Center

Reprint request to: *Limdawati Kwee, M.D.*, Dept. of Medicine, St. Luke's Medical Center, E. Rodriguez Ave., Quezon City, Philippines

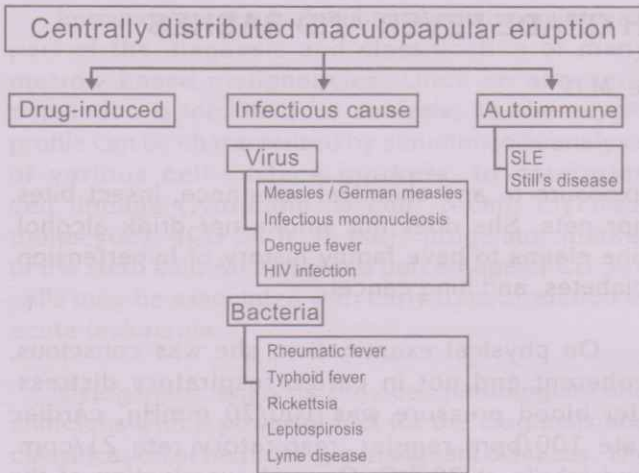


Fig. 1. Diseases Characterized with Centrally Distributed Maculopapular Eruption

Although the patient have allergy to Penicillin, she has no recent history of penicillin injection thus exanthematous drug-induced eruption can be ruled out as a cause of her rashes. Viral infection with fever and rash presentation could be seen in these four diseases: Measles/German measles, Infectious Mononucleosis, Dengue fever and acute HIV infection. Measles and German measles can be ruled out since these two diseases have rashes that begin at hairline behind the ears which was not claimed by our patient. Aside from that, the incidence of disease recurrence is rare. Infectious mononucleosis caused by Epstein-Barr virus is highly considered because it is characterized by fever, sore throat, bilateral posterior cervical lymphadenopathy, maculopapular rashes, and it may have episode of recurrence in patient with immunodeficiency status. Although patient had fever and rashes, she had no muscle pain, headache, retroorbital pain, nausea/vomiting and bleeding episode, hence dengue fever can be ruled out. Acute HIV infection was considered since it may present with fever, pharyngitis, lymphadenopathy, arthralgia, and erythematous maculopapular rash. The symptoms usually persist for several weeks and gradually subside, however it may recur once the immune system is impaired.

In bacterial infections, the following diseases present with fever and rash: (1) Rheumatic fever, could present with fever, polyarthritis and skin rashes. However rashes which are called erythema marginatum are different with the rashes of our patient. This disease also occurs mostly in children; hence rheumatic fever in our patient is less likely. (2) Typhoid fever is characterized by remittent fever with maculopapular rashes known as rose spots and gastrointestinal symptoms, which is not found in our patient hence it can be ruled out. (3) Rickettsial disease, should be considered in the evaluation of individual with centrally distributed maculopapular eruptions, however we can rule this out because our patient had no tick exposure and no history of travel outside Manila or to endemic area of Rickettsia.

(4) Leptospirosis, also presents with fever and rash, however other characteristic features such as myalgia, jaundice and conjunctival suffusion are not present in our patient, hence it can be ruled out. (5) Lyme disease is caused by spirochete and transmitted by mite/tick vector. It presents with annular skin lesion with central clearing and arthritis of large joints which were not seen in our patient. It is also not prevalent in the Philippines; hence this disease is less likely.

Aside from drug-induced and infectious cause of fever and rash, an autoimmune setting such as Systemic Lupus Erythematosus (SLE) and Still's disease can be entertained since both of them are characterized by fever, maculopapular rashes, arthritis and with period of recurrence. Hence, our differential diagnosis for the cause of fever and rashes at this point are: Infectious mononucleosis, acute HIV infection, Systemic Lupus Erythematosus, and Still's disease.

What diagnostic tests will differentiate Infectious mononucleosis, acute HIV infection, Systemic Lupus Erythematosus, and Still's disease?

The heterophile antibody test is used for the diagnosis of infectious mononucleosis. In the study by Chien *et al.*,² in 2001, heterophile antibody was found to be 75% sensitive and 90% specific in diagnosing infectious mononucleosis, with a positive likelihood ratio of 7.5 and negative likelihood ratio of 0.28. Our patient's heterophile antibody is negative. Based on the prevalence of infectious mononucleosis in adults and adolescents with fever and rash,³ we set the pretest probability of infectious mononucleosis at 50%. Since our result is negative, we use negative likelihood ratio of 0.28 at the nomogram, decreasing the probability of our patient as having Infectious mononucleosis to 20%.




Fig. 2. Probability of Infectious Mononucleosis in Patient Using Heterophile Antibody Test

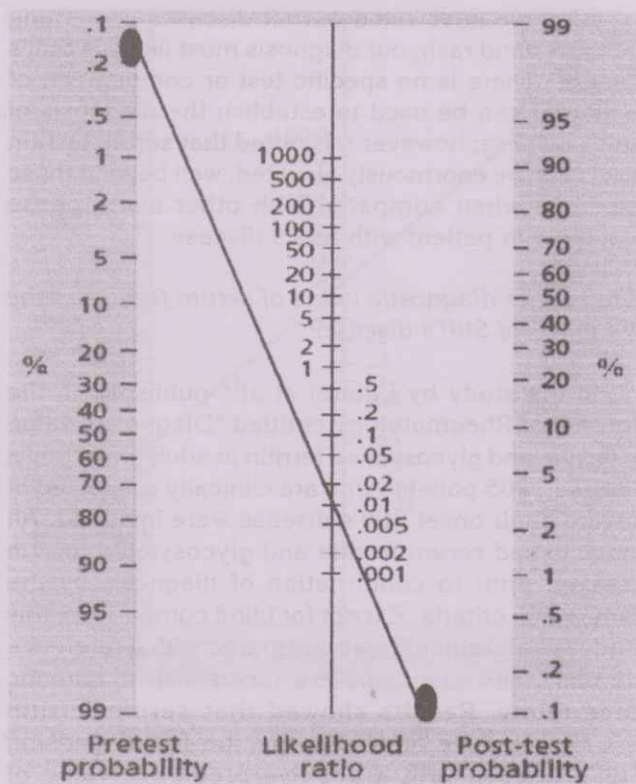


Fig 3. Probability of HIV Infection Using HIV ELISA Test

HIV ELISA test is the recommended screening for HIV. Chou *et al*⁴ in their study about screening for HIV showed that HIV ELISA test has sensitivity of 99% and specificity of 98% in diagnosing HIV, with positive likelihood ratio of 49.5 and negative likelihood ratio of 0.01. Our patient had negatively HIV ELISA test. With a pretest probability of 0.1% based on prevalence of HIV in our country⁵ and negative HIV ELISA test, giving the probability of less than 0.1% for our patient having HIV, hence we can rule out HIV infection.

Based on the 1982 revised criteria for classification of SLE, if four of the eleven criteria are present at any time during the course of disease, a diagnosis of SLE can be made. Our patient has arthritis which fulfilled 1 out of the 11 criteria. To determine our post test probability we requested for ANA titer which is a sensitive test in detecting the presence of an autoimmune disease. ANA test of our patient was positive at low titer 1:80. According to study by Malleson *et al* in 1997,⁸ ANA titer at 1:80 give a positive likelihood ratio of 0.8. Assuming individual features has equal weight, probability of SLE can be presumed based on the number of manifestations found (Table I).⁷

Table I. Probability of Systemic Lupus Erythematosus (SLE) Based on the Number of Manifestations

Number of Manifestations	Sensitivity %	Specificity %	Probability of SLE %
0	100	0	0
1	100	52	2
2	99	81	5
3	90	94	13
4	80	98	29
5	63	99	39

With one clinical manifestation of Systemic Lupus Erythematosus (SLE) in our patient, we set the pretest probability to 2%. Using positive likelihood ratio of 0.8, decreasing the probability of SLE to 1.8%.

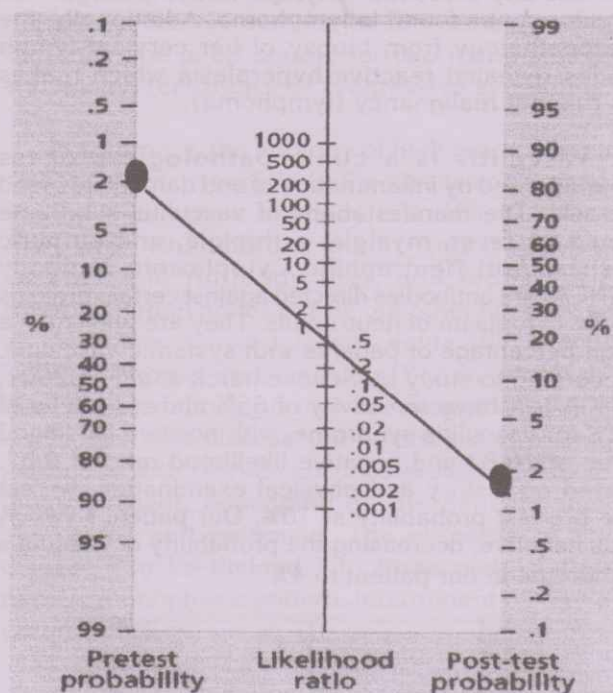


Fig 4. Probability of SLE Using Anti Nuclear Antibody Test

We are left with Still's disease in our patient's differential diagnosis. Yamaguchi Criteria is used to establish the diagnosis of Still's disease (Table II).

Table II. Yamaguchi Criteria for Diagnosis Still's Disease⁹

Major criteria	Minor criteria
1. Fever > 39°C more than 1 week	1. Sore throat
2. Arthralgia more than 2 weeks	2. Lymphadenopathy
3. Typical rash	3. Liver dysfunction
4. Leukocytosis	4. Negative ANA and Rheumatoid Factor

The presence of five features, with at least two being major diagnostic criteria were required to diagnose Still's disease. Based on study by Bennet *et al*¹⁰ in 2004, Yamaguchi Criteria has 96% sensitivity

and 92% specificity in diagnosing Still's disease, with a positive likelihood ratio of 12. With the pre test probability at 20% based on the history and physical examination and the fulfillment of more than five criteria, increasing the probability of our patient having Still's Disease to 80%. However the diagnosis of Still's disease remains one of exclusion.

What are the exclusion criteria for Still's disease?

Systemic infection, malignancy (lymphoma), and vasculitis syndrome should be ruled out before a diagnosis of Still's disease is made.⁹ The most common malignancy that presents with fever and lymphadenopathy is lymphoma. Our patient's abdominal CT scan only showed right nephrolithiasis without any evidence of lymph nodes enlargement which may be found in lymphoma. Additionally, the histopathology from biopsy of her cervical lymph nodes revealed reactive hyperplasia which makes us rule out malignancy (lymphoma).

Vasculitis is a clinicopathologic process characterized by inflammation of and damage to blood vessels. The manifestations of vasculitis syndrome could be fever, myalgia, arthralgia, and purpuric rashes. Anti Neutrophilic Cytoplasmic Antibody (ANCA) are antibodies directed against certain proteins in the cytoplasm of neutrophils. They are present in a high percentage of patients with systemic vasculitis. According to study by Schonemarck *et al*¹¹ in 2001, ANCA test have sensitivity of 65% and specificity of 94% for vasculitis syndrome, with positive likelihood ratio of 10.83 and negative likelihood ratio of 0.37. Based on history and physical examination, we set the pre test probability at 10%. Our patient's ANCA was negative, decreasing the probability of vasculitis syndrome in our patient to 4%.

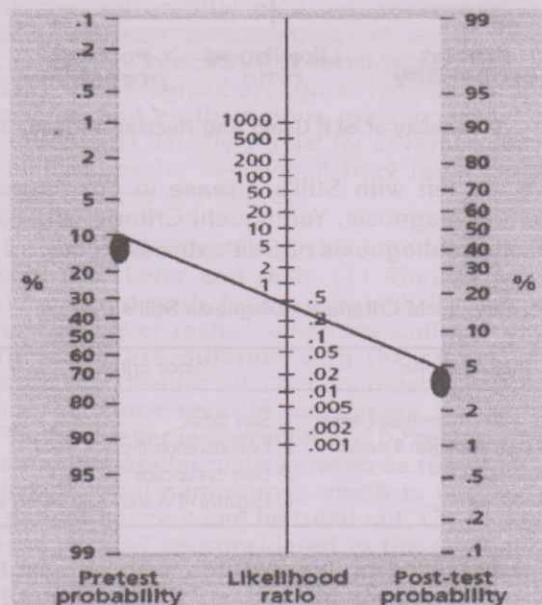


Fig 5. Probability of Vasculitis Syndrome Using Anti Neutrophilic Cytoplasmic Antibody (ANCA) Test

After we have ruled out all diseases presenting with fever and rash, our diagnosis most likely is Still's disease. There is no specific test or combination of tests that can be used to establish the diagnosis of Still's disease; however it is noted that serum ferritin levels can be enormously elevated, well beyond those expected when compared with other acute phase reactants in patient with Still's disease.

What is the diagnostic value of serum ferritin in the diagnosis of Still's disease?

In the study by Fautrel *et al*¹² published in the Journal of Rheumatology entitled "Diagnostic value of ferritin and glycosylated ferritin in adult onset Still's disease", 205 patients who are clinically suspected of having adult onset Still's disease were included. All patients had serum ferritin and glycosylated ferritin assayed prior to confirmation of diagnosis by the Yamaguchi criteria. Except for blind comparison, this study is valid since it was compared with a reference standard and clinicians are faced with diagnostic uncertainty. Results showed that serum ferritin is 67% sensitive and 35% specific for diagnosing Still's disease with a positive predictive value of 30%, negative predictive value of 73%, positive likelihood ratio of 1.03 and negative likelihood ratio of 0.94. A serum ferritin level more than 5 times the upper limit of normal is 41% sensitive and 80% specific for diagnosing Still's disease with a positive predictive value of 45%, negative predictive value of 77%, positive likelihood ratio of 2.05 and negative likelihood ratio of 0.73. Glycosylated ferritin is one of isoform of the ferritin, which value less than 20% considered abnormal. It has sensitivity of 97% but specificity of 19% for diagnosing Still's disease with a positive predictive value of 32%, negative predictive value of 95%. The results are applicable to our patient and is reproducible. The authors concluded that ferritin and glycosylated ferritin levels are powerful diagnostic markers of adult onset Still's disease. They may be helpful in clinical practice for excluding differential diagnosis in patients presenting with fever and rash. Although glycosylated ferritin is the most sensitive for diagnosing Still's disease, serum ferritin at more than five times normal value would provide a higher likelihood ratio of 2.05 in determining adult onset Still's disease.

Our patient's serum ferritin was 2990 ng/ml, which is more than five times upper limit normal. With pretest probability of 80% based on Yamaguchi criteria and positive likelihood ratio of 45% increase the probability of our patient having Still's disease to 92%. Hence our impression is Adult onset Still's disease.




Fig 6. Probability of Still's Disease Using Serum Ferritin Test

How Do We Manage Patient with Adult Onset Still's Disease?

Therapeutic decisions should be based upon the extent and severity of organ system involvement. Patients with relatively mild disease may respond to a Non Steroid Anti-inflammatory Drugs (NSAID). Ibuprofen 800mg QID or naproxen 500mg BID are reasonable selections for initial therapy. If patients do not demonstrate a resolution of their symptoms within several days of starting an NSAID, the addition of glucocorticoid should be considered. Those with high fevers, debilitating joint symptoms, or internal organ involvement should be treated with glucocorticoids from the onset of therapy. If Still's disease proves refractory, biologic agents such as Tumor Necrosing Factor (TNF) inhibitor should be used. When patients have not responded sufficiently to the drugs mentioned above, Diseases Modifying Anti-Rheumatic Drugs (DMARDs) can be employed. However only limited data exist to support the use of any particular DMARDs. Since our patient had no response to her previously medication (Ibuprofen), she then was put on Methylprednisolone 16 mg tablet 3x a day which relieved her symptoms.

What is the outcome of patient with adult onset Still's disease?

The clinical course of adult onset Still's disease can be divided into three main patterns:¹⁷

- 1) Monophasic pattern (14.3%), who have a disease course that usually lasts less than one year, with complete resolution of symptoms.
- 2) Intermittent pattern (57.1%), who have one or more disease flares with complete remissions between episodes. The subsequent flares tend to be less severe and shorter in duration.
- 3) Chronic pattern (28.6%), who have persistently active disease, usually associated with a destructive arthritis. The predictors of chronic disease are the development of polyarthritis early in the course of disease, involvement of the shoulders or hips and the need for more than two years of systemic steroid therapy. We can also use serum ferritin to monitor the disease activity. Our patient was given corticosteroid with tapering dose for five months. Her serum ferritin went down to normal gradually. Presently she is off steroid for two months already and has no recurrence or progressive symptoms.

In summary, the etiology of high grade fever and rashes in our patient is Still's disease. We need to request heterophile antibody test, HIV ELISA test, ANA titer, Rheumatoid factor, Anti Neutrophilic Cytoplasmic Antibody titer, and biopsy of the enlarged lymph nodes to rule out other etiology such as Infectious mononucleosis, acute HIV infection, SLE, lymphoma, and vasculitis. Serum ferritin more than 5 times above normal has diagnostic value in diagnosing this disease. Still's disease is managed medically with NSAID, corticosteroid, DMARD's, or biologic agent, depending on the patients clinical symptoms and response. The outcome of Still's disease can be divided into three main patterns, namely monophasic pattern, intermittent pattern and chronic pattern.

Benjamin Jr Felipe, M.D.: (Infectious Disease Consultant): Was any work-up done to rule out the possibility of endocarditis?

Limdawati Kwee, M.D.: The 2D-echocardiogram was done, which showed no evidence of vegetation. Blood culture was negative, and Rheumatoid factor was less than 20 U/l.

Benjamin Jr Felipe, M.D.: Did you also consider syphilis in this patient?

Limdawati Kwee, M.D.: this patient also has been worked up for syphilis. RPR or Rapid Plasma Reagen was requested and revealed negative result.

Dennis F Natino, M.D.: (Moderator): Are there reported cases of patients diagnosed as Still's disease and later found out having lymphoma?

Juan Javier T Lichauco, M.D.: (Rheumatology Consultant): Still's disease is not a common. So far, based on literature, there is no real case of malignant transformation of Still's disease to lymphoma. But as what Dr. Kwee presented, this is a diagnosis of exclusion. You always have to document that the patient has no existing lymphoma. If someone later on develops lymphoma, I would consider it to be a misdiagnosis rather than a transformation of Still's disease into malignancy. That may be because Still's disease is not considered a B cell disease unlike rheumatoid arthritis, psoriatic arthritis and SLE. It is an autoimmune disease which are basically lymphocyte driven. There are patients that are at risk of developing lymphoma but Still's disease does not confer the same risk.

Dennis F Natino, M.D.: Do you use Rituximab in patients with Still's disease?

Juan Javier T. Lichauco, M.D.: No, there are no reports on the use of Rituximab. However, there are reports on the use of anti-TNF agents such as Infliximab that is because TNF is a very important cytokine in Still's disease. Proinflammatory cytokine when stimulated also produces cytokine that propagate inflammation. Its use is still off label with very few case reports to merit the use of anti-TNF. I would consider it in patients with poor remission and control despite the used standard of treatment.

Benjamin Jr Felipe, M.D.: This patient was suspected to have lymphoma and have one excision biopsy. Would you request any more test to confirm that this patient has lymphoma?

Dennis F nation, M.D.: Normally, we look at the diagnostic criteria for lymphoma. The biopsy using morphology alone would be difficult because you are dealing with the same cell that produces inflammation which may also produce a malignant growth. When the haematologist is in doubt, we would use immunophenotyping to come up with the type of cell that you see, whether you are dealing with a monoclonal cell or whether it's something else. It's very important to get as much tissues as possible since architecture is very important in lymphoma. That's why we refrain from using FNAB in the initial diagnosis.

REFERENCES

1. Elaine TK, Kenneth MK: Fever and Rash. In: Kasper DL, Fauci AS, Braunwald E, Hauser SL, *et al.* Editors. Harrison's Principle of Internal Medicine. 17th ed. McGraw-Hill Companies. New York: 2008, p110.
2. Chien YC *et al.*: Serologic Markers of Epstein-Barr Virus Infection and Nasopharyngeal Carcinoma. *N Engl J Med*, 345: 1877, 2001.
3. Aronson M: Infectious Mononucleosis in Adults and Adolescents. *Ann Internal Med*, 75: 82, 2002.
4. Chou, *et al.*: Screening for HIV: A Review of the Evidence for the U.S. Preventive Services Task Force. *Annals of Internal Medicine*, 143 (1): 55-73.
5. Prevalence of HIV/AIDS in the Philippines: Dept. of Health (DOH), Government of the Philippines. 2005.
6. Hochberg MC: 1982 Revised Criteria for Classification of Systemic Lupus Erythematosus (Updated 1997). *Arthritis Rheum*, 40:1725, 1970.
7. Black ER, *et al.*: Diagnostic Strategies for Common Medical Problems, 2nd Edition, 4:98, 1999.
8. Malleson PN, *et al.*: Usefulness of Antinuclear Antibody Testing to Screen for Rheumatic Diseases. *Arch Dis Child*, 77:299, 1997.
9. Edward DH: Disorders of Immune-Mediated Injury. In: Kelley's Textbook of Rheumatology. Vol. II 7th ed. 2005, p1047-1048.
10. Bennett H, *et al.*: Adult Onset Still's Disease and Collapsing Glomerulopathy. *Rheumatology Journal*, 43:795, 2004.
11. Schonermark U, *et al.*: Prevalence and Spectrum of Rheumatic Diseases Associated with Proteinase 3-Antineutrophil Cytoplasmic Antibodies (ANCA) and Myeloperoxidase-ANCA. *Rheumatology*, 40: 178, 2001.
12. Bruno Fautrel, *et al.*: Diagnostic Value of Ferritin and Glycosylated Ferritin in Adult Onset Still's Disease. *The Journal of Rheumatology*, 28(2): 322, 2001.
13. Sampalis P, *et al.*: Adult Onset Still's Disease: Manifestations, Disease Course and Treatment. *Medicine (Baltimore)*, 70:118, 1991.
14. Klipper JH: Adult Still's Disease. *Rheumatology*, 521, 1998.
15. Fujii, *et al.*: Methotrexate Treatment in Patients with Adult Onset Still's Disease. *Ann Rheum Dis*, 56:144, 1997.
16. Aarntzen, *et al.*: Refractory Adult Onset Still's Disease and Hypersensitivity To Non Steroidal Anti Inflammatory Drugs and Cyclo-Oxygenase-2 Inhibitors: Are Biological Agents the Solution? *Ann Rheum Dis*, 64:1523, 2005.
17. Sukhbir Singh, *et al.*: Ten Years of Clinical Experience with Adult Onset Still's Disease: Is the Outcome Improving? *Clin Rheumatol*, 26:1055, 2007.
18. Schwarz-Eywill, *et al.*: Evaluation of Serum Ferritin As A Marker for Adult Still's Disease Activity. *Annals of the Rheumatic Disease*, 51:683, 1992.